

MINISTRY OF HEALTH OF THE RUSSIAN FEDERATION
FEDERAL STATE EDUCATIONAL INSTITUTION OF HIGHER EDUCATION
AMUR STATE MEDICAL ACADEMY

**Tseluyko S. S., Krasavina N. P., Korneeva L. S.,
Lashin S.A., Ostronkov V.S.**

**MORPHOFUNCTIONAL CHARACTERISTICS
ISLETS OF THE PANCREAS AND LUNG IN
EXPERIMENTAL HYPERGLYCEMIA DURING
TREATMENT WITH DIHYDROQUERCETIN**

Blagoveshchensk, 2017

МИНИСТЕРСТВО ЗДРАВООХРАНЕНИЯ РОССИЙСКОЙ ФЕДЕРАЦИИ
ФЕДЕРАЛЬНОЕ ГОСУДАРСТВЕННОЕ ОБРАЗОВАТЕЛЬНОЕ
УЧРЕЖДЕНИЕ ВЫСШЕГО ОБРАЗОВАНИЯ
АМУРСКАЯ ГОСУДАРСТВЕННАЯ МЕДИЦИНСКАЯ АКАДЕМИЯ

**С.С.Целуйко, Н.П. Красавина, Л.С. Корнеева,
С.А. Лашин, В.С. Остронков**

**МОРФОФУНКЦИОНАЛЬНАЯ
ХАРАКТЕРИСТИКА ОСТРОВКОВ
ПОДЖЕЛУДОЧНОЙ ЖЕЛЕЗЫ И ЛЕГКОГО ПРИ
ЭКСПЕРИМЕНТАЛЬНОЙ ГИПЕРГЛИКЕМИИ НА
ФОНЕ ПРИМЕНЕНИЯ ДИГИДРОКВЕРЦЕТИНА**

Благовещенск, 2017

Monograph Authors



Tseluyko Sergey Semenovich

Doctor of Medical Sciences, professor, Head of the Department of Histology and Biology of Federal State Institution of Higher Education Amur State Medical Academy of Ministry of Health of the Russian Federation



Krasavina Nadezhda Pavlovna

Doctor of Medical Sciences, professor of the Department of Histology and Biology of Federal State Institution of Higher Education Amur State Medical Academy of Ministry of Health of the Russian Federation



Korneeva Larisa Sergeevna

Candidate of Medical Sciences, Assistant Professor of the Department of Internal Diseases of Federal State Institution of Higher Education Amur State Medical Academy of Ministry of Health of the Russian Federation



Lashin Sergey Alekseevich

Chairman of the Board of Directors of JSC "Ametis"



Ostronknov Vladimir Sergeevich

CEO of JSC "Ametis"

About the company “Ametis”

Ametis JSC was founded on June 25, 1998 in Blagoveshchensk. Despite the fact that Ametis JSC is a relatively start-up company, it has already become the largest industrial complex in production of Dahurian larch extracts and proved to be a stable, commercially viable competitor.

All activities of the company are submitted to one aim: to create an innovative high-tech manufacturing enterprise by complex processing of Dahurian larch wood succeeded by a unique natural substances extraction.

The company doesn't stand still; it develops successfully in the domestic and international markets, improving technology of production, introducing know-how in order to produce natural, highly effective, qualitative products. In this regard, Ametis JSC works in close rapport with more than 20 leading scientific institutions located in Russia, including Amur State Medical Academy, Far East State Agrarian University, Institutes of Tomsk, Novosibirsk and Moscow.



УДК: 616.153.455.01 - 611.018 - 678.048

БКК (P)

ISBN

Tseluyko S.S. Morphofunctional characteristics of pancreatic and lung islets in experimental hyperglycemia during treatment with dihydroquercetin /S.S. Tseluyko, N.P. Krasavina, L.S. Korneeva, S.A. Lashin, V.S. Ostronkov; edited by S.S. Tseluyko. - Blagoveshchensk, 2017.- 147p.
Translation from Russian by Kosyreva P.V.

В книге содержатся материалы о строении и функциональной организации островков Лангерганса поджелудочной железы и легких при экспериментальной гипергликемии на фоне применения биофлавоноида – дигидрокверцетина.

В работе представлены новые факты, полученные гисто-, электронно-иммуногистохимическими методами о морфо-функциональных отношениях клеточной организации островков Лангерганса, воздухоносных и респираторных отделов легких. Книга рассчитана на морфологов, пульмонологов и всех тех, кто интересуется вопросами экспериментального диабета и действием биофлавоноида дигидрокверцетина.

Ключевые слова: поджелудочная железа, легкие, экспериментальный диабет, биофлавоноид дигидрокверцетин.

Reviewers:

Ryzhavskiy Boris Yakovlevich - honored worker of science of the Russian Federation, head of the department of Biology and Histology of the Far Eastern State Medical University, doctor of Medical Sciences, professor;

Reva Galina Vasilievna - doctor of Medical Sciences, professor of the department of Fundamental Medicine at the School of Biomedicine of the FEFU.

The book contains the materials of the structure and the functional organization of the islets of Langerhans of the pancreas and lung in experimental hyperglycemia during treatment with bioflavonoid Dihydroquercetin. The paper presents new evidence obtained by histological, electron methods of morphological and functional relationships of cellular organization of Langerhans islets, pneumatic and respiratory portions of lungs. Book designed morphology, pulmonologists, and all those who are interested in experimental diabetes and action of bioflavonoid Dihydroquercetin.

Key words: pancreas, lungs, experimental diabetes, bioflavonoid Dihydroquercetin.

All rights reserved. No part of this book may be reproduced in any form without the written permission of the copyright holders.

(C) S.S. Tseluyko, N.P. Krasavina, L.S. Korneeva, S.A. Lashin, V.S. Ostronkov, 2017.

PREFACE

The research presented by the authors enables to substantiate and implement into clinical practice new approaches to the preventive measures, treatment and rehabilitation of patients with diabetes mellitus and lung diseases. The administration of glucose in large doses to rats leads to the development of sustained hyperglycemia, increased reactions of lipid peroxidation, and negative changes in the structure of the pancreas. The administration of dihydroquercetin in the setting of experimental hyperglycemia causes a blood glucose decrease, a decrease in the reaction level of lipid peroxidation and an increased concentration of vitamin E in peripheral blood and lung tissue; it also leads to the improvement of structural changes in the pancreatic islets of Langerhans. Dihydroquercetin from Dahurian larch is produced by Ametis under the trademark “Lavitol” by means of its own patent-protected technology. “Lavitol” is registered not only in Russia, but also abroad. The company is certified in US FDA (United States Food and Drug Administration) and “Lavitol” was granted the status GRAS (generally recognized as safe), revealing that the product was generally recognized as safe. “Lavitol” is on the list of the International Nomenclature of Cosmetic Ingredients and it is registered as a cosmetic raw material in India.

The data were obtained by the authors with the use of modern histo-, electron-immunohistochemical methods of the morpho-functional relations of the cell organization of the pancreatic islets of Langerhans, airway and respiratory units of the lungs; they introduce new ideas about the diseases process in violation of the regulation of carbohydrate metabolism.

Identified in the tested object of experimental hyperglycemia, the anti-hypoxic effect of dihydroquercetin bioflavonoid enables to use it in the combination therapy of diabetes mellitus, as well as in other morbid conditions accompanied by the development of tissue hypoxia. The obtained data can be used in research work and teaching issues at the departments of medical universities.

Ryzhavskiy Boris Yakovlevich – Doctor of Medical Sciences, professor

Reva Galina Vasilevna - Doctor of Medical Sciences, professor

INTRODUCTION

THEMATIC JUSTIFICATION: At the present time diabetes mellitus (DM) occupies one of the leading positions in the list of the morbidity. Considering the fact that this pathology is accompanied by a large number of complications, specifically the development of organ-specific lesions of many organs and systems, the problems of preventive measures and treatment of DM are of particular importance [Geller, L. I., 1975; Baranov, V. G., 1983; Mazoveckiy, A. G., 1987; Demidova, I. Y., 2000; Williams, G., 2003; Ametov, A. S., 2005; Dedov, I. I., 2006; Shestakova M. V., 2012; Zimmet, P., 1999; Tenerz, A., 2001; Wild, S., 2004; Yuji K., 2013; Phung O. J., 2014]. For instance, according to the International Diabetes Federation (IDF), by 2010 the total number of patients with DM in the world was 239.4 million people, and by 2025 - will be 380 million. More than 90% of patients suffer from type 2 diabetes of this number. In Russia there are about 300 thousand people with type 1 diabetes and more than 2.5 million with type 2.

Today WHO experts classify diabetes as an epidemic of noncommunicable disease. There are works indicating that mortality of patients with DM from non-specific lung diseases in Russia is up to 5.8%, and in some countries this number is higher. The data obtained testify that pulmonary dysfunction with asymptomatic DM are more than 60% in patients who are officially registered [Titova, E. A. et al, 2008; Shishkova V. N., 2015; Kaparianos, A., 2008]. At the same time the condition of the respiratory system with this pathology has been understudied [Kodlova, I. M., 1982; Shcherbak, A. V., 1986; Balabolkin, M. I., 1994; Titova E. A. and others, 2008]. It is considered that the main role in DM is played by hyperglycemia. As far back as the 1990s, scientists established that there is a kind of "point of no return" in the development of the DM, after which it is almost impossible to influence the progression of complications associated with the disease. It has been suggested that the effect of high blood glucose concentrations over a relatively short period of time forms a metabolic memory that reserves even after normalization of its

level [Baranov, V. G., 1983; Dmitriev, L. F., 2005; Matthaei, S., 1986; Ciriello, A., 1999; Fonseca, V., 2011].

Alongside this, hyperglycemia has a negative effect on the morphofunctional condition of B cells of the pancreas. The pathogenetic basis of type 2 diabetes is insulin resistance (IR), which causes different metabolic disturbances. Often as a result of IR, hyperinsulinemia occurs, causing endothelial dysfunction and vasospasm [Saltykov, B. B., 1984; Genyk, S. N., 1989; Balabolkin, M. I., 2000; Sazonova, O. V., 2000; Popov, D., 2001; Balabolkin, M. I., 2004; Bashkirova, Y. V., 2008; Lukyanchikov, V. S., 2009; Veneman, T. F., 2012; Lieveise, A. G., 2013]. In the setting of hyperglycemia, the level of lipid peroxidation in the body is activated; this leads to the excess formation of free radicals, which do a cytotoxic action on the cells and tissues of the body. Oxidative stress leads to the development of angiopathies, as a result, the most active induction of free radical oxidation in the vascular bed. Free radicals damage the cellular and non-cellular structures of the vessel wall leading to angiopathies [Suhanova, L. Y., 1988; Lyaifer, A. I., 1993; Bobireva, L. E., 1996; Dedov, I. I., 2003; Churchill, L., 1993]. In this setting, capillary-trophic insufficiency appears; gas exchange is disrupted and, as a result, pronounced hypoxia emerges, which further aggravates the lesion of the vessel wall. Therefore, an assigned role in the development of all diabetic complications is attributed to hypoxia [Galenok, V. A., 1985; Lukyanova, L. D., 2004; Khnychenko, L. K., 2006; Sokolov, E. I., 2008; Mazo, V. K., 2014].

According to many researchers, widespread vascular lesions (diabetic macro- and microangiopathies) with DM in most organs already occur in its early stages. I.e., diabetic angiopathies are the morphological substrate in the setting of which pathological changes develop [Balabolkin, M. I., 2000; Balabolkin, M. I., 2000; Dedov, I. I., Melnichenko, T. A., 2008; Lipatov, D. V., 2012; Ditzel, J., 1979]. Initially, they are scattered in nature, and therefore remain compensated and appear under certain specific conditions, in particular when lung diseases occur. It is known that

acute pneumonia in patients with DM is characterized by a large spread of the process, significant severity and prolonged course [Kodolova, I. M., 1982; Lysenko, L. V., 1990; Arthur, C.W., 2004; Kaparianos, A., 2008]. Developing in type 2 diabetes chronic hyperglycemia and hypoinsulinemia induce the pro-inflammatory activity of the cellular and humoral effects of the immune system [Nazhmutdinova, D. K., 2000; Lukyanchikov, V. S., 2009].

For a long time treatment of type 2 diabetes was limited to controlling the symptoms of the disease[Gendeleka, G. F., 1989; Gorbenko, N. I., 1999; Alexandrov, A. A., 2004; Smolyanskiy, B. L., 2004; Khnychenko, L. K., 2006; Zhestovskiy, S. S., 2007; Zilov, A. V., 2007; Balabolkin, M. I., 2008; Gavrovskaya, L. K., 2008; Havinson, B. H., 2008; Shishkova, V. N., 2008; Ametov, A. S., 2009; Dedov, I. I., 2009;Shestakova,E.A. 2012;Blinkova,T.M., 2015;Hansen, S. H., 2001; Faerch, K., 2009; Veneman,T.F., 2012]. At the present timeconsiderable success has been achievedwith regard to diabetes treatment, but there are still a lot of unresolved issues and thus there is a need for a comprehensive correction of pathogenetic factors that lead to structural changes in tissues and organs.The modern tactics of treating patients with strict control of blood glucose level does not lead to the achievement of the desired result; in lightof this it is impossible to avoid the development of various complications.There is a need for additional impact on various parts of the pathological process by reducing tissue hypoxia and the reaction level of lipid peroxidation (LPO).Lack of efficacy of glycemetic control alone makes it necessary to search for drugs that can actively affect various parts of the pathogenesis of DM, both for preventive measures and treatment.This will reduce the progressive decrease of B cells of pancreas and activate their functions.

There is evidence indicating that in the complex therapy of DM and its vascular complications, the use of antioxidants, in addition to reducing the intension of LPO, led to the stabilization of carbohydrate metabolism and the improvement of the clinical state of patients [Dedov, I. I., 1992; Bobyreva, L. E., 1998; Gorbenko, N. I.,

1999; Dedov, I. I., 2003; Volchegorskiy, I. A., 2008; Paolisso, G., 1993; Fonseca, V., 2011; Lieverse, A.G., 2013]. In addition, antioxidant drugs can have a normalizing effect on the blood rheology, the glycemic index, contributing to faster normalization of blood glucose levels in the setting of the use of smaller doses of glycemic agents. Thus, on the one hand, antioxidants are able to prevent the development of hypoxia, and on the other hand, to improve the survival of cells under these conditions. It is important to evaluate the efficacy of drugs based on the results of a morphological examination of experimental animals taking into account the duration of antioxidant use. These drugs are among the most advanced ones since the use of vasoprotectives in the setting of antihyperglycemic therapy does not give a proper result and leads to the progression of diabetic angiopathies [Efimov, A. S., 1989; Galstyan, G. R., 2002; Dedov, I. и др., 2003; Williams, G., 2003; Chernikova, N.A., 2010; Rogovskiy, V.S., 2013; Adler, A. I., 2000; Estacio, R.O., 2000]. Therefore the issue of morphofunctional state value of the vascular bed of the respiratory organs in case of DM in the setting of the use of antioxidant drugs becomes particularly important. The most appropriate in this case is the use of already created drugs that have high antioxidant activity. Phytogenic medications of flavonoid nature, in particular dihydroquercetin, make the difference. It has an antioxidant activity, is resistant to auto-oxidation and is low-toxic; it also reduces vascular permeability and positively affects the hemostatic system [Teselkin, Y. O., 1996; Lukyanova, L. D., 2007; Uminskiy, A. A., 2007; Zhanataev, A. K., 2008; Mazo, V.K., 2016; Blostein-Fujii, A., 1999; Nijveldt, R. J., 2001; Wang, J.Y., 2014].

Thus, the use of the drug can be very useful with the aim of preventing the progression of diabetic complications, because type 2 diabetes is a chronic disease that leads to functional and structural disorders of various organs and systems, which requires long-term and targeted treatment.

CHAPTER 1. Rationale for the application of the model of experimental hyperglycemia in rats

The study of the effect of drugs means involving the use of laboratory animals and the application of the method of experimental modeling.

Carbohydrate metabolism disorder and the production of hyperglycemia, capable of initiating biochemical and structural disorders similar to those observed in patients with DM, were the main condition of this study. In our work it was necessary to cause permanent disabilities in carbohydrate metabolism, i.e. an increase in the glycemic index for a long time, leading to the appearance of a phenomenon such as glucotoxicity, which results in the damaging action of glucose on various structures of cells and tissues. One of the ways to implement the phenomenon of glucotoxicity is to increase the reaction of peroxidation of glucose, as well as lipids and proteins, accompanied by an increase in the level of extremely reactive free radicals. Furthermore, it should be considered that in the conditions of hyperglycemia the activity of individual links of the antioxidant defense system decreases, and this ultimately leads to the destruction of many organs and systems. Taking into consideration these circumstances, it was necessary to comply with a number of fundamental conditions: the glycemia should be high enough, its duration during the day should be several hours, and the total duration of the violation of the carbohydrate status - several months.

There is a wide range of experimental models for creating hyperglycemia, but in most cases, these methods are based on the destruction or significant metabolic disturbances of B cells of pancreatic islets.

The model of alloxan diabetes and diabetes caused by streptozotocin are traditional and generally accepted in experimental endocrinology. As its significant deficiencies, a direct cytotoxic effect on B cells can be called, as well as high toxicity of these drugs, inducing severe damage to internal organs, in particular the liver, which significantly limits the life span of experimental animals and does not allow the

development of complications, the appearance of which is associated with the duration of hyperglycemia.

At the department of Pharmacology of the Amur State Medical Academy, experimental work was carried out to create hyperglycemia in rats and the maximum possible non-lethal dose of carbohydrate loading was determined based on the experiment, which was 600 mg of glucose/100 g of the animal's weight. The administration of glucose solution at the indicated dose led to the development of sustained hyperglycemia, along with a long enough hyperglycemic period, the duration of which was on average about 4 hours, and the use of a double injection allowed increasing the total daily hyperglycemia to 8 hours. Confirmation of this served as indicators of blood glucose, estimated in the fasting state, after 30 minutes and every hour before their normalization [Bitiutckaya, L. G., 2005]. The difference of current model is the absence of direct damage to the islet apparatus of the pancreas, and the severity animals' condition in the experiment is due to significant and prolonged hyperglycemia. Taking into consideration this circumstance, in our work we have created a hyperglycemic state in experimental animals using this dose.

In consideration of the foregoing premises it was decided that the most convenient and appropriate way to create high and prolonged hyperglycemia is the intraperitoneal administration of glucose solution. But, unfortunately, the intraperitoneal administration of such an amount of glucose into the body of experimental animals, in addition to the growth of glycemia, led to a disruption of the water-electrolyte balance during the first four weeks, the development of water depletion and the appearance of crystalluria in 25% of rats, and by the 8th week - the appearance of stone formation in the kidneys.

But it should be noted that there are other alternatives with which an imbalance in carbohydrate metabolism can be caused; this is the creation of artificial hyperglycemia in animals using different ways of administration of glucose solutions into the body of experimental animals - peroral through a probe [Bitiutckaya, L. G., 2005] and parenteral. This technique enables to avoid double intraperitoneal

administration of a glucose solution and consequently to reduce the degree of disturbance of water-electrolyte balance and water depletion, especially in the early stages of the experiment.

In our work, we also took into account the fact that absorption of glucose from the gastrointestinal tract leads to the greatest stimulation of B cells and the release of insulin, than when glucose enters the blood, bypassing the gastrointestinal tract. Taking into account this circumstance, we believe that this is critically important for the creation of a more prolonged hyperglycemia.

For this reason we tried to create a state of hyperglycemia in a way that eliminated substantial damage to the structures of internal organs and allowed us to control the severity of the disturbance of carbohydrate metabolism, which is highly important for a long experiment for 8-16 weeks.

The main criteria for assessing the state of hyperglycemia in our work were glucose levels in the peripheral blood of rats in the fasting state in the period from 8.00 to 8.30, i.e. before glucose intake, which was measured weekly during the experiment. These data are presented on the table below, and during the first two weeks of the experiment the glucose content of rats was increased in the fasting state, but the data had sizable fluctuations in different animals. By the 4th week of the experiment, the stabilization of glucose content was noted in most rats. A significant increase of the glucose level to 5.9 ± 0.58 mmol/L in experimental animals was noted at the 4th week of the experiment (Table 1). At the same time limits the natural application of the glucose solution by peroral way leads to an increase of its level in the blood after 60 minutes to 11.5 ± 0.85 mmol/L, with a high level maintained for at least 2 hours. At 8 weeks of hyperglycemia, the glucose level in the fasting state rose to 6.6 ± 0.61 mmol/L, and 60 minutes after peroral administration it was 12.8 ± 0.73 mmol/L (table 1). This testifies that during this experiment we obtained a model with a hyperglycemic syndrome and this allows us to study the effect of drugs with the following background.

Table 1

**CONCENTRATION OF GLUCOSE OF BLOOD RATS
IN THE FASTING STATE AND 60 MINUTES AFTER THE PERORAL
ADMINISTRATION OF GLUCOSE (MMOL / L)**

Groups of animals Type of experiment		Hyperglycemia during:				Intact
		4 weeks	6 weeks	8 weeks	16 weeks	
Hyperglycemia 8 weeks	In the fasting state (control)	5,9 ± 0,58*	6,2 ± 0,37*	6,4 ± 0,53*	-	3,1 ± 0,24
	After taking glucose	11,5 ± 0,85**	-	-	-	
Hyperglycemia 16 weeks	In the fasting state (control)	-	-	6,6 ± 0,61*	7,1 ± 0,63*	3,4 ± 0,26
	After taking glucose	-	-	12,8±0,73**	-	

* p< 0,05 in comparison with intact animals

** p< 0,05 in comparison with animals with hyperglycemia in the fasting state

Thus, unlike other methods that cause disturbance of carbohydrate metabolism, this model allows obtaining a steady rise in the glucose level in the peripheral blood in the setting of peak rises of this indicator for a sufficiently long period, in the absence of damaging effects on the B cells of pancreatic islets.

CHAPTER 2. Morphofunctional characteristics of pancreatic islets

Overview of pancreatic islets

The endocrine portion of the pancreas is represented by peculiar clusters of glandular cells forming islets that are scattered among the acini of the exocrine part. Pancreatic islets make up from 2 to 10% of the total mass of the pancreas, they do not have excretory ducts; the hormones secreted by them are secreted into the blood. The islets have a round or oval shape, and their diameter varies from 50 to 500 microns. Most large pancreatic islets are surrounded by a thin connective tissue capsule separating them from the acinar tissue. Small islets do not have such capsule and they are in close contact with exocrine cells. The number of glandular cells (islet cells) in different islets varies considerably, depending mainly on the size of the islets [Gordienko, V. M., 1978; Baranov, V. G., 1983; Balabolkin, M. I., 1994; Lacy, P.E., 1974; Orci, L., 1974; Tushuizen, M. E., 2007].

The islet is represented by several types of cells, differing in size, shape, nucleus structure, nucleoli and cytoplasmic components. The cells are located between capillaries, abundantly anastomosing with each other, organizing a kind of sinusoidal network. In the central part of the islets there are numerous sinusoidal capillaries, which are bounteously fenestrated, that apparently discharges the intake of hormonelike materials from the cytoplasm of islet cells into the bloodstream and determines the rate of response of the islets to metabolic signals. Endothelial cells of capillaries are separated from islet cells by a fairly wide periendothelial space, in which two basement membranes underlying the secretory cells on one side and the endothelial cells on the other are clearly defined [Puzyrev, A. A., 1974; Baranov, V. G., 1983; Kondratiev, Y. Y., 1986; Mazovetskiy, A. G., 1987; Chumasov, E.I., 2015; Lacy, P.E., 1967; Orci, L., 1971; Veld, P., 2015].

The predominant type of islet cells in most mammals are B cells, which amount 75-80% of the total number of islet cells; the number of α -cells is 15-20% while the

portion of D cells is not more than 2-5%. In intact animals there are from 3-4 to several hundred B cells in pancreatic islets. α -cells are located mainly on the periphery of the islet. D cells are found not in all islets, but mainly in medium and large ones [Gordienko, V. M., 1978; Lacy, P.E., 1974; DominguezBendala, J., 2009]. Ultrastructural criteria for the identification of different types of islet cells were first developed by P. Lacy (1967, 1974), who used serial ultrathin sections and then studied them under an electron microscope, that enabled to draw a clear distinction between the main types of islet cells.

Characteristics of B cells

B-islet cells are the main cells of the islets of the pancreas; their cytoplasm is selectively stained with aldehyde-fuchsin according to Gomori in blue-violet color. These cells usually occupy a central position in the pancreatic islets, comparatively often they are found near the acinar cells, ducts and peripheral capillaries; they can be presented between α -cells [Puzyrev, A. A., 1974; Puzyrev, A. A., 2006; Barabanov, V.M., 2014; Lacy, P.E., 1967; Govendir, M., 1999]. B cells are usually polygonal or irregular in shape and are the largest in size. The nucleus of B cells is usually eccentrically located, it is large, and contains numerous granules of chromatin. In the cytoplasm of B cells there are numerous secretory granules that have a significantly lower electron density in comparison with α -cells. In addition, the boundary membrane is separated from the contents of the secretory granule of the "core" by a wider bright rim, and it is located, as a rule, somewhat eccentric. The boundary membrane of B granules usually has sinuous contours; the "core" of granules is round, of medium electron density and fine granular structure. In some B cells, in addition to numerous granules of average electron density, denser ones also occur. Sometimes there is a close contact of secretory granules of medium density with the plasma membrane and the release of their contents into the intercellular spaces or periendothelial space of the capillary [Gordienko, V. M.,

1978; Severgina, E. S., 1992; Hellman, B. O., 1974; Johnston, C., 1987; Elbein, S. C., 1988; Dominguez Bendala, J., 2009].

Each B cell contains about 13,000 secretory granules that are at different developmental stages and are a kind of insulin repository. In addition to insulin, other peptides, amylin, monoamines, enzymes and various minerals are also found in the secretory granules of B cells.

The species specificity of the morphology of secretory granules in B cells should be noted. Thus, the morphology of secretory granules described above is characteristic of B cells of pancreatic islets of rat and mouse.

The rough endoplasmic reticulum is well developed; it is formed by short tubules, as well as by small vacuoles, on the membranes of which there are bound ribosomes. There is also a significant number of free ribosomes, located singly or in small groups between cell organelles. All of this makes the cytoplasm of B cells more "dark" in appearance in comparison with α -cells. Mitochondria are elongate, contain obliquely located cristae, they are numerous and concentrated mainly near the Golgi apparatus, which is well developed and occupies a large area of the cell [Puzyrev, A. A., 2006; Orci, L., 1971; Aerts, L., 1998; Bouwens, L., 2005].

B-islet cells can be represented by "light" cells, in the cytoplasm of which there are few granules that have different sizes and densities. They are usually arranged in the cytoplasm or concentrated in one of the poles. Organelles are represented by single cisterns of the granular endoplasmic reticulum, elements of the Golgi apparatus and small elongated mitochondria. "Dark" B cells contain a large number of granules of different sizes, varying intensity of color, equally located in the cytoplasm. In these cells there are few organelles, small mitochondria and some densely located small lipid inclusions are usually found there. The third type of cells, which can be defined as "intermediate", has an equal distribution of the average number of granules, a typical set of elements of organelles, small lipid inclusions, vacuoles. Among the three types of B cells, the cells with obvious signs of

destruction can be found: a sharp vacuolization of the cytoplasm, the lipid inclusions that sometimes displace the cytoplasm [Puzyrev, A. A., 1974; Utekhin, V. I., 1979; Puzyrev, A. A., 2006; Barabanov, V.M., 2014].

Regeneration of islet cells

During the fetal life endocrine and exocrine cells are formed from stem cells, i.e., they can be developed from the pancreatic ducts. Consequently, in the postnatal period the formation of endocrine cells from the cells of the pancreatic ducts is possible. In embryogenesis the islets, apparently, grow owing to the proliferation of precursor cells and their differentiation into the cells of islets; the increase in the total mass of islet cells in the period of postnatal growth is due to the mitotic division of these cells themselves. A number of studies have shown that the formation of endocrine cells in the pancreas of an adult occurs due to the mitotic activity of endocrine cells themselves or by differentiation of duct cells. Normally, the mitotic activity of endocrine cells of islets is small [Vesnina, I. A., 2001; Adler, A. I., 2000; De Haro-Hernandez, R., 2004; Chong, A.S., 2006; Wu, X., 2009; Garber, A. 2011].

For many years it was believed that B cells differentiate toward the end of the prenatal period and their number in postnatal life does not change [Apple, A., 1977; Baranov, V. G., 1983; Dominguez Bendala, J., 2009]. However, owing to the numerous experimental studies and new technologies, it has become clear that the total pool of B cells in the pancreas is unstable, it is dynamic and the number of B cells changes (increases or decreases) to maintain glucose homeostasis depending on various external and internal factors. It is proved that the increase in the number of endocrine cells, usually observed during the fetal life, is carried out not only by means of the replication of existing islet cells, but also through their neo-transformation from the pool of rapidly dividing the cells of gland ducts [30, Goldberg, E. D., 2006].

This is proved by data in which it was shown that cytokeratins are the markers of differentiation of duct cells and the process of neogenesis of islets in the pancreas of neonatal rats. Studies using this technique made it possible to follow up and confirm the formation of islets from the cells of the exocrine part of the pancreas [Kolesnik, Y. M., 1996; Dedov, I. I., Melnichenko, T. A., 2008].

Pancreatic islets of adult animals and humans are also characterized by low values of cell reproduction. Accordingly, the regeneration of the islet cell population takes place in 103 days [Gordienko, V. M., 1978]. Under the conditions of experimental and clinical pathology, the process of rearrangement of acinar epithelium in endocrine cells is observed, which develops in several cells of one or several adjoining adenomeres at once. The final result of this change is the formation of new pancreatic islets.

In general, the recovery processes in the endocrine apparatus of the pancreas are carried out by the formation of new islets as a result of the acini-insular rearrangement and by increasing the proliferative activity of present islet cells [Balabolkin, M. I., 1994; Kolesnik, Y. M., 2004; Butler, A.E., 2003]. It is considered that the adult has a slow renewal of the B cell population. Normally the number of B cells in the islet in the postembryonic period depends on the balance of their neoplasms and apoptosis, which, first of all, is determined by the level of glycemia.

The new formation of islet cells is mainly due to the activation of the division of already differentiated B cells [Teta, M., 2007; DominguezBendala, J., 2009]. Hyperglycemia has a mitogenic effect on B cells. With diabetes there is a lack of B cells in order to compensate for their loss because they lost the ability to proliferate at a rate commensurable with the rate of their loss. Therefore, there may come a moment when the remaining B cells can no longer completely ensure the body's need for insulin [Vesnina, I. A., 2001; 30, Zakiryanov, A. R., 2008; Chumasov, E.I., 2015; Lipsett, M., 2002; Rومان, I., 2002].

Brief description of insulin biosynthesis

The insulin production is regulated by the negative feedback mechanism, depending on the concentration of glucose in the blood plasma. Rising glucose levels contribute to the increase in production of insulin; in conditions of hypoglycemia, the formation of insulin, on the contrary, is inhibited [Ivanova, V. F., 2006; Hellman, B. O., 1974; Bolaffi, J. L., 1990; Abe, N., 2002].

The bulk of pancreatic islet cells produce insulin, which is an albuminous compound with a molecular weight of about 60,000. Each molecule of insulin is connected to three zinc atoms, which reduces its solubility and promotes the transition of insulin into a crystalline form.

On the basis of evidence [Gordienko, V. M., 1978; Bolaffi, J. L., 1990], it can be assumed that the synthesis of insulin in B cells begins on the ribosomes of the endoplasmic reticulum, then the precursor of insulin (proinsulin) is transferred to the Golgi apparatus, where it is reacted to form insulin, which accumulates in the mature secretory granules. Under certain conditions, the formation of secretory granules can take place either in elements of a rough endoplasmic reticulum or in the Golgi apparatus. If the granulation normally ends in the Golgi apparatus, then with a sharp increase in the secretory activity of islet cells, when the body needs an increased amount of the hormone, the latter can be partially or completely synthesized and formed into secretory granules in the tubules of the endoplasmic reticulum. It may be possible that the above granule formation mechanisms in islet cells do not exclude each other [Lacy, P.E., 1967; Hellman, B. O., 1974].

At the present time, there are also two points of view on the way to remove the contents of secretory granules from the islet cells into the blood. According to the first point of view, the release of the secret granules happens by means of their dissolution (granulolysis) near the plasma membrane. In the granulopoiesis stage, the granules have a high electron density. In the stage of preparation for secretion they reach their maximum value and gradually lose the electron density. With a

decrease in the density of secretory granules, the phase of granulolysis begins, accompanied by the release of the granule contents through the perforations of its boundary membrane into the cytoplasm. The released hormone enters special areas of the plasma membrane – “active sectors”, which contain certain enzymes that promote the movement of the hormone through the plasma membrane into the pericapillary space and cytoplasm of the endothelial cells.

On the other hand, a number of researchers believe that the removal of the contents of secretory granules from the islet cells occurs by means of exocytosis (emiocytosis). The results of electron microscopic studies show that the secretory granules are transferred to the cell surface by intact ones. Then the granule membrane fuses with the plasma membrane of the cell, an opening is formed at the fusion site, through which the granule contents enter the intercellular spaces or into the pericapillary space, where its solution occurs. During the studying of the small mechanisms of emiocytosis it was noted that in stimulated B cells, secretory granules often form chains provided that the granule in contact with the plasma membrane can release its contents. Sometimes the connection of granules between themselves can be observed, as well as with a plasma membrane by means of microtubules and microfilaments [Galstyan, G. R., 2008; Lacy, P.E., 1974; Kaparianos, A., 2008].

The main action of insulin consists of enhancing the transport of glucose through the cell membrane. The enhancement with insulin leads to an increase in the rate of glucose intake inside the cell in 20 - 40 times. In healthy individuals, there is a constant basal secretion of insulin, even then, when there are no exogenous stimulation pulses for insulin secretion. In most mammalian cells, this process is carried out by means of diffusion of carrier proteins.

Insulin reduces the sugar content in the blood of a healthy person by changing the metabolism in the body tissues, in addition, the following changes appear: 1) absorption of sugar in the gastrointestinal tract after taking generous fare would

significantly increase the sugar content in the blood, if part of it was not deposited in the hepatocytes and muscle cells in the form of glycogen, i.e. insulin promotes the conversion of sugar into glycogen; 2) excess sugar is also removed from the blood as a result of its transformation into fat, which accumulates in various fat stores; 3) insulin also stimulates the metabolism of carbohydrates in muscle cells, i.e. the acceleration of the utilization of carbohydrates in the muscles leads to a decrease in the concentration of sugar in the blood [Galenok, V. A., 1985;Kendysh, I. N., 1985; Ametov, A.S., 2008;Gordiunina, S.V. 2012;Bouwens, L., 2005;Kahn, S. E., 2009].

It has been established that insulin regulates the metabolism of lipids in the lungs, where specific receptors of it are identified in the membrane structures of normal lungs of rats. Insulin interacts with these receptors rapidly, and saturation capacity is reversible and depends on time and temperature. In experimental diabetes mellitus, the incorporation of glucose in neutral fats and phospholipids decreases by 40% in the lung tissue of rats, which may cause a decrease in the synthesis of surfactant, and also increases the content of non-esterified fatty acids (NEFA). Histochemical and electron microscopic studies have shown the deposition of triglycerides in the endothelium and smooth muscle cells of the pulmonary artery with DM [Kodolova, I. M., 1982; Lysenko, L. V., 1990].

Characteristics of alpha cells

Acidophilic cells (α -cells) are usually irregular in shape, while Gomori's stain in their cytoplasm reveals a red granularity. In pancreatic islets of rats, α -cells have a rounded, oval, rarely polygonal shape and they are arranged in a single layer along the periphery of the islets. A characteristic feature of α -cells is the presence in their cytoplasm of numerous secretory granules, which are made as round bodies of high electron density, surrounded by a clearly discernible smooth membrane. Between the thick contents of the secretory granule and its boundary membrane there is a narrow electron-transparent zone (halo). The electron dense "core" of granules is usually of a regular rounded shape; its contents have a fine-grained appearance. The

nucleus of α -cells is rounded, located somewhat eccentrically. Mitochondria have an elongated rod-like shape and sinuous contours. In the cytoplasm of some α -cells, there is sometimes a small amount of glycogen granules [Puzyrev, A. A., 1974; Gordienko, V. M., 1978; Mazovetskiy, A. G., 1987; Lacy, P.E., 1974; Veld, P., 2015].

Some researchers marked a decrease in the secretory activity of α -cells of pancreatic islets in diabetes. In such animals, in the setting of high hyperglycemia in the cytoplasm of α -cell, numerous lysosome-like structures appear that contain α -granules, which are at different stages of decomposition. It is known that glucagon is not only the most powerful glycemic factor, but it also has a stimulating effect on the state of B cell secretion, which is one of the compensatory mechanisms in diabetes mellitus. In addition, the hypersecretion of glucagon is possibly related to the loss of regulating action of insulin, since the level of the latter plays an important role in supporting adequate activity of α -cells [Baranov, V. G., 1983; Mazovetskiy, A. G., 1987; Puzyrev, A. A., 2003; Williams, G., 2003].

Characteristics of other islet cells

D cells in pancreatic islets may be found quite rare, they are located singly or in small groups throughout the islet, have a polygonal or stellate shape and long cytoplasmic processes. D cells either directly are in contact with the capillaries, or send their processes to them. A characteristic feature of D cells is the presence in the cytoplasm of specific secretory granules, the size of which varies considerably (from 200 to 400 nm). The greatest accumulation of granules is observed in the cytoplasmic processes and at the vascular pole. The nucleus of D cells is large, has a round or somewhat elongated shape and contains a compact nucleolus. The contents of the granules are somatostatin, which has the ability to inhibit the secretion of insulin and glucagon, and also limit the absorption of glucose in the intestine. Perhaps this plays an important role in the conditions of a pronounced hypersecretion of glucagon in order to limit its hyperglycemic effect. This effect

somatostatin can perform, acting as a local hormone, i.e., paracrinely [Ogneva, V. V., 1972; Gordienko, V. M., 1978; Kolesnik, Y. M., 2004].

During the electron microscopic examination of pancreatic islets of intact rats, it was possible to observe single PP cells with an angular shape, usually located near the capsule, which contain very small secretory granules (80 nm) in their cytoplasm. The latter are usually arranged in a single line along the plasma membrane [Gordienko, V. M., 1978; Baranov, V. G., 1983].

Acinar-islet cells are located on the boundary between islet cells and acinar cells and are very rarely found inside the islets. In the cytoplasm of such cells, there are two types of secretory granules, mitochondria and elements of the rough endoplasmic reticulum, characteristic for both endocrine and exocrine cells of the pancreas. Secretory granules in acinar-islet cells are represented by large zymogen granules and small granules with a distinct light rim, characteristic of islet cells. Acinar-islet cells with one pole can be in contact with the capillary, and the other - with the duct. In this case, the bulk of the endocrine secretory granules is concentrated on the vascular pole of the cell, and the zymogen granules are concentrated near the duct.

Acinar cells with structural features of islet B cells generally have a non-regular distribution of granules in the cytoplasm. It should be noted that acinar-islet cells in higher vertebrates, in particular in the human pancreas, are rare. Their number increases noticeably with various pathological conditions, when the body's need for hormones produced in islet cells is significantly increased. This may serve as evidence that the exocrine epithelium is among the main sources of islet tissue formation [Kolesnik, Y. M., 1996; Kolesnik, Y. M., 2004; Ivanova, V. F., 2006; Snigur, G. A., 2008].

Hyperglycemia and its importance in the development of complications of diabetes mellitus

Hyperglycemia is the result of a carbohydrate metabolism disorder, in which the level of glucose entering the body exceeds its consumption by organs and tissues. The cause of hyperglycemia may be an increase in glucose excretion, or a decrease in the utilization of glucose by tissues, or, finally, a combination of these effects [Geller, L. I., 1975; Kendysh, I. N., 1985; Mazovetskiy, A. G., 1987; Balabolkin, M. I., 1994; Demidova, I. Y., 2000; Dedov, I. I., 2006; Shestakova, E. A., 2012; Marzo, V., 2008; Panzram, G., 1987; Zimmet, P., 1999; Fonseca, V., 2011].

In humans and animals, in spite of hyperglycemia, the intake of glucose in the tissue is disrupted, and cells experience carbohydrate deficiency, energy shortage. The body responds by secretion of metabolic hormones (glucagon, adrenaline and others), which are aimed at mobilization of glucose from the available reserve - to activate the glycogenolysis in the liver. However, the intake of additional amounts of glucose in the blood only intensifies hyperglycemia, but does not lead to the desired result - the glucose uptake into the tissues.

It is known that the regulation of glucose depends on the feedback mechanism in the pancreatic B cell system - liver - peripheral tissues. In light of this, hyperglycemia in type 2 diabetes mellitus is caused by a disruption of the normal relationship between the function of the pancreatic B cells and insulin sensitivity at the level of peripheral tissues or liver [Baranov, V. G., 1965; Dmitriev, L. F., 2005; Zanchetti, A., 2002].

Chronic hyperglycemia can cause a dysfunction of B cells (glucose toxicity), inducing the acceleration of glycosylation processes of various proteins and lipids. An increase of glucose level in blood intensifies the insulin resistance condition and, possibly, leads to a decrease in the sensitivity of B cells, therefore causing dysinsulinism. A vicious cycle is developing: increasing glucose levels enhances insulin resistance, which contributes to the development of even more

severe hyperglycemia [Balabolkin, M. I., 2000; Ametov, A. S., 2002; Balabolkin, M. I., 2003; Tenerz, A., 2001].

It is well known that in the human body there is an insulin-mediated glucose uptake (IMGU) and non-insulin-mediated glucose uptake (NIMGU). At basal (in the fasting state) NIMGU predominates, it is responsible for almost 70% of the total distribution of glucose in the human body. Normally, in order to increase IMGU by 2 times, less than double hypersecretion of insulin is required. On the contrary, in case of type 2 diabetes mellitus, by reason of the presence of insulin resistance, an increase in insulin levels by 5 to 6 times is necessary to the IMGU boost. Due to the fact that in patients with type 2 diabetes mellitus the possibilities for an acute increase in IMGU are limited, postprandial glycemia will be significantly increased. It must be emphasized that postprandial hyperglycemia develops and exists for several years before the development and appearance of fasting hyperglycemia. In type 2 diabetes, due to the weak sensitivity of insulin receptors to its hormone and/or weak intensification of the hormonal signal, the liver is unable to serve as a buffer in regulating the content of glucose in the blood plasma, and here one of the crucial tasks is to find ways to activate glycolysis. With hyperglycemia the glucose metabolism shifts toward the formation of sorbitol, which is unable to leave the cell quickly. The latter leads to a change in the osmotic pressure in the cells and to the disruption of the glyco- and phospholipid composition of cellular membranes due to the accumulation of sorbitol. In metabolic disorders with DM, the appearance of the so-called "vicious circle" due to "error", i.e., inappropriate response of regulatory mechanisms, can be traced. In chronic hyperglycemia the glycosylation process serves as a pathogenetic background of the development of complications, the frequency and severity of which is directly dependent on the level and duration of hyperglycemia [Galenok, V. A., 1985; Balabolkin, M. I., 1994; Dmitriev, L. F., 2005; Matthaei, S., 1986; Vlassara, H., 1995; Bensellam, M., 2009].

Morphological changes of the pancreas in clinical and experimental hyperglycemia

Pancreatic islets in patients with type 2 diabetes mellitus, both in volume and in cell structure, do not differ from pancreatic islets of apparently healthy individuals of the same age, although the total volume of endocrine tissue in them is significantly reduced. In these patients, the loss of the compact structure of the islets is observed. The islets are separated by fibrous septa; the number of B cells in them is reduced. Detailed studies have shown that the extensive relationships of α -, B-, and D cells in pancreatic islets of patients with type 2 diabetes correspond to developmental norms, but the total cell volume is smaller due to a decrease in the number of islet tissue. The bulk of B cells has one or another signs of destructive changes: various degrees of vacuolization of the cytoplasm, lipid inclusions. Degenerating B cells are in frequent contact with macrophages, the number of which increases significantly in comparison with the norm. As a rule, a sharply thickened capsule is found around these clusters. In the islets of the pancreas in diabetic patients, hydropic (waterborne) degeneration can appear later along with the constantly occurring degenerative processes. The hormone level in α -cells increases, which depends on the severity of the disease and is apparently determined by the degree of decrease in insulin secretion, and is one of the compensatory mechanisms in diabetes mellitus. In the pancreas of more than 60% of patients with type 2 diabetes mellitus pancreatic arterial sclerosis is diagnosed. The advanced fibrosis of the entire pancreas is observed. Fibrotic changes in pancreatic islets are associated with vascular sclerosis. Often in the stroma of the islets of the gland, there are accumulations of hyaline or amyloid. The concentration of amyloid in the islet of the pancreas with diabetes leads to a deterioration of B cells function. During the electron microscopic examination in the focus of sclerosis, multidirectional collagen fibers are determined, which formed "couplings" around

the capillaries [Mazovetskiy, A. G., 1987; Balabolkin, M. I., 1994;Kolesnik, Y. M., 1996; Titok, T. G., 1999; Dedov, I. I., 2006;Lipatov, D.V., 2012].

In animals with mild diabetes mellitus, the signs of destruction of B cells are discovered in 2 weeks, which come into sharp focus after 5 weeks [Bitiutskaya,L. G., 2005]. To a greater extent, large islets were damaged at this, while small ones remained practically intact. The decrease of the insulin level of these animals was also marked [Gordienko, V. M., 1978; Kolesnik, Y. M., 1996;Ivanova, V. F., 2006;Snigur, G. A., 2008].

Brief information about the pathogenesis of diabetes mellitus

In a healthy person, the insulin secretion is described in terms of two characteristics: constant secretion and secretion of insulin, which has a discrete character throughout 24 hours.Discrete insulin secretion occurs in response to an increase in glucose levels observed postprandially and after absorption of glucose from the intestine into the blood.Such peaks of hypersecretion of insulin after ingestion are performed in the setting of basal insulin release from the pancreas at a rate of 1 to 2 units of activity per hour within 24 hours.Diabetes mellitus is a chronic disease caused by absolute or relative insulin insufficiency, leading to a breakdown in all types of metabolism, primarily carbohydrate metabolism, vascular damage (angiopathy), and pathological changes in various organs and tissues [Dedov, I. I., 2006; Dedov, I. I., Melnichenko,T. A., 2008; Ametov, A. S., 2009;Khalimov, Y.S., 2012;Schneider, S. H., 1988;Hadjiliadis, D., 2005;Phung, O.J., 2014].

Present knowledge about the pathogenesis of type 2 diabetes mellitus indicate that it can develop both as an insulin-sensitive and as an insulin-resistant variant[Mazovetskiy, A. G., 1987; Balabolkin, M. I., 1994].The insulin-sensitive variant is characterized by a diminished function of the pancreatic B cells in relation to the secretion of insulin. In the meantime, the action of insulin on organs and tissues in terms of regulation of glucose homeostasis is intact.This option can develop in the setting of a number of defects associated with a breakdown of the

“recognition” of glucose or sensitivity to glucose at the level of B cells of the pancreas, or ion channels disorders, or disorders of the synthesis of insulin. Essential type 2 DM is a heterogeneous and polygenic disease, in the development mechanisms of which several factors participate - genetic and epigenetic or external environment [Baranov, V. G., 1983; Demidova, I. Y., 2000; Balabolkin, M. I., 2003; Gordiunina, S. V. 2012].

According to the currently accepted point of view, in the pathogenesis of type 2 DM, two components are involved: 1 - insulin resistance of peripheral tissues (fat and muscular) and the liver, which is primary and whose presence has been proved practically in all patients early during the stage of pre-diabetes. 2 – B cell dysfunction, being expressed by a decrease of the first phase of insulin secretion and/or disappearance of pulsatile secretion of insulin, as well as B cells depletion and an apparent insufficiency of insulin secretion with a simultaneous modest increase of glucagon secretion [Baranov, V. G., 1965; Balabolkin, M. I., 2003; Ametov, A. S., 2008].

At the early stages the organism tries to compensate for the heightened need for insulin tissues by means of starting the processes of reparative regeneration and hypertrophy of the residual B cells, that is expressed by a temporary (up to 7-10 months) clinical remission of the disease, known as the “honeymoon” phase. A certain contribution to keeping hyperglycemia in type 2 DM makes an excessive formation of glucose by the liver, which allows one to consider the violation of the glucose-forming liver function as the third element in the pathogenesis of type 2 DM. It should be emphasized that the increased glucose formation by the liver results from the dominance of catabolism, i.e. the decay of liver glycogen (glycogenolysis) and the increase in the rate of glucose formation by the liver (gluconeogenesis). Long-term hyperglycemia promotes the development of insulin resistance and has a damaging action on cells (the phenomenon of glucotoxicity), leads to a decrease in carrier proteins of glucose and secretory activity of B cells. All

of this reduces the carbohydrate utilization by tissues and causes breakdown of other types of metabolism. As a result, with diabetes mellitus, progressive damage of various organs and tissues takes place [Ametov, A. S., 2002; Balabolkin, M. I., 2003; Francini, F., 2001; Yuji, K., 2013].

Angiopathies

The key reason of early disability and mortality of patients with pathology of carbohydrate metabolism is vascular damage, which is of generalized nature. It has been established that along with the vascular lesion of large and medium-size (macroangiopathy), large changes occur in the vessels of the microcirculatory bloodstream (microangiopathy), which is characterized by a thickening of the basement membrane, a violation of its selective permeability, proliferation of smooth muscle cells. Endothelial cells are essential to the regulation of normal vascular function. The manipulations that cause damage or dysfunction of the endothelium may lead to the development of severe vascular disorders. In particular, an increase in the osmotic pressure in the endothelium of the capillaries leads to fluid entering the cytoplasm, swelling, edema, and luminal narrowing of small vessels.

A certain role in the progression of microangiopathy is attributed to hypoxia. In patients with various forms of disturbance of carbohydrate metabolism, a decrease in the efficiency of the oxygen transportation system was noted, which is to a certain extent due to the presence of capillarotrophic insufficiency syndrome. In hyperglycemia, there are significant changes in the shape of erythrocytes, there is a tendency towards hemolysis, adhesion to the luminal surface of the endotheliocytes and sometimes to their basement membranes, the appearance of an irregular form of aggregates, erythrocytes such as mulberries [Bobyreva, L. E., 1996; Sazonova, O. V., 2000; Galstyan, G. R., 2002; Jialal, I., 1989; Vlassara, H., 1995].

High glucose concentration in DM changes the metabolism of proteins and sulfoglycoproteins of the basement membrane and intercellular matrix. The

characteristic of it permeability increase of the basement membrane of the vessels, regardless of the presence and type of angiopathy, led to the assumption of the universal role of these disorders in the development of diabetic angiopathies. In macrovessels, the changes in the intima in the form of its thickening of varying length and degree were most pronounced. Muroid swelling and proliferation of smooth muscle cells of the intima often lead to a significant thickening. Among the proliferating smooth muscle cells, there are "obese" and decaying ones, which is associated with their capture of low density lipoprotein (LDL) modified by malondialdehyde by means of uncontrolled endocytosis, after which they become "foam cells". In small arteries of the muscular type, a widespread hyalinosis of the intima or the entire vessel wall develops [Kupriyanov, V. V., 1979; Genyk, S. N., 1989; Saltykov, B. B., 2000; Bregovskiy, V. G., 2001; Lipatov, D.V., 2012; Phung, O.J., 2014].

It is testified that with DM changes similar to the ones in other organs that are the most pronounced and common in the long course of the disease develop in lung vessels. In the wall of small arteries, arterioles and veins, there are granuloma formations consisting of macrophages, lipofagans, among which there were giant cells, fibroblasts located around the products of insudation, represented by homogeneous anhistoc masses [Efimov, A. S., 1989; Balabolkin, M. I., 2000]. In the arterioles, the phenomena of plasmorrhagia, the proliferation of endothelial cells with its exfoliating into the lumen of the vessels, as well as the proliferation of adventitia cells were observed. Along with these changes in the alveolar septa there were peculiar pericapillary nodules that look like eosinophilic, hyaline-like masses of round shape, spherically covering the capillary whose lumen is constricted.

In other words, diabetic microangiopathy in the lungs has a morphological singularity: changes in the arterioles of the pulmonary artery and capillaries of the alveolar septa predominate, evidently under the conditions of the pathology of the byproducts involved in excretion into the wall and lumen of the alveoli [Saltykov, B. B., 2000]. Often in the capillaries we can observe the red blood cell adhesion, the

accumulation of platelets closely in contact with the endothelium, which leads to a vessel constriction, and sometimes to its obstruction. According to several authors, a decrease in the number of functioning capillaries caused microcirculatory hypoxia. The basement membrane of the blood capillaries often thickened and lost clear boundaries. Dystrophic changes in endothelial cells are observed, which is characterized by the formation of vacuoles, mitochondrial swelling, and expansion of the tubules of the cytoplasmic reticulum. Lipid drops appear in the cytoplasm of the epithelial cells of the capillaries of the alveoli. They are also found in the cytoplasm of polymorphonuclear leukocytes, in capillary lumens, alveolar macrophages, type II alveolocytes and fibroblasts of alveolar septa [Lysenko, L. V., 1990; Balabolkin, M. I., 2000; Dedov, I. I., 2006].

Thus, with hyperglycemia along with nonspecific changes in the vascular wall (plasmorrhagia, hyalinosis, dystrophy, proliferation and cell atrophy), there is also a characteristic symptom complex for diabetes mellitus: basement membrane thickening of the endothelial lining due to the accumulation of PAS-positive substances and, first of all, type IV collagen [Galenok, V. A., 1985; Efimov, A. S., 1989; Lukyanchikov, V. S., 2009; Adler, A. I., 2000; Estacio, R. O., 2000].

CHAPTER 3. Histological, histochemical, electron microscopic and morphometric characteristics of the islets of the pancreas of rats

Morphofunctional characteristics of pancreatic islets in intact rats

The islets of the pancreas of the rat have a different shape and size, they are separated from the acinar tissue by a thin connective tissue capsule (Fig. 1). The number of cells in the islet on the section is different and this allowed them to be divided into three groups according to the number of islet cells in their structure: small- $12,3 \pm 1,4$; medium - $75,2 \pm 2,5$; large - $110,3 \pm 3,1$ (Table. 2). It should be pointed out that islets of medium size are found much more often, their number is more than 50%. B cells mainly occupy the central part of the islet. On semi-fine sections it can be seen that the cytoplasm of B cells is more basophilic than in α -islet cells, most of which are located along the periphery of the islet (Fig. 2). Electron-diffraction patterns show that B cells have a shape close to prismatic, and numerous granules are contained in their cytoplasm. Their number over an area of $10 \mu\text{m}^2$ amounts to $44 \pm 2,3$, along with this the number of granules with an average density predominates – $24,6 \pm 2,07$. The area of secretory material in 1 granule is $39400 \pm 223 \text{nm}^2$. The granules have dense contained “core”, a wide bright bezel and a membrane. The contents of the granules are located somewhat eccentrically, has a different density. In a number of cells, the content of the granules released into the intercellular space is observed. Numerous tubules of the endoplasmic reticulum are revealed in the cytoplasm. The nucleus of the cell is rounded, intensely colored, located eccentrically, chromatin is mainly located near the nuclear membrane and in a smaller amount in the center (Fig. 3).

Capillaries between cells have a fairly wide periendothelial space, numerous fenestra appear in the endothelium.

α -cells are oval in shape, their nuclei rather large, round in shape, lighter than in B cells, the nucleolus is compact. The cytoplasm is colored lighter than in B-islet cell, contains numerous granules located in groups and near the plasma membrane.

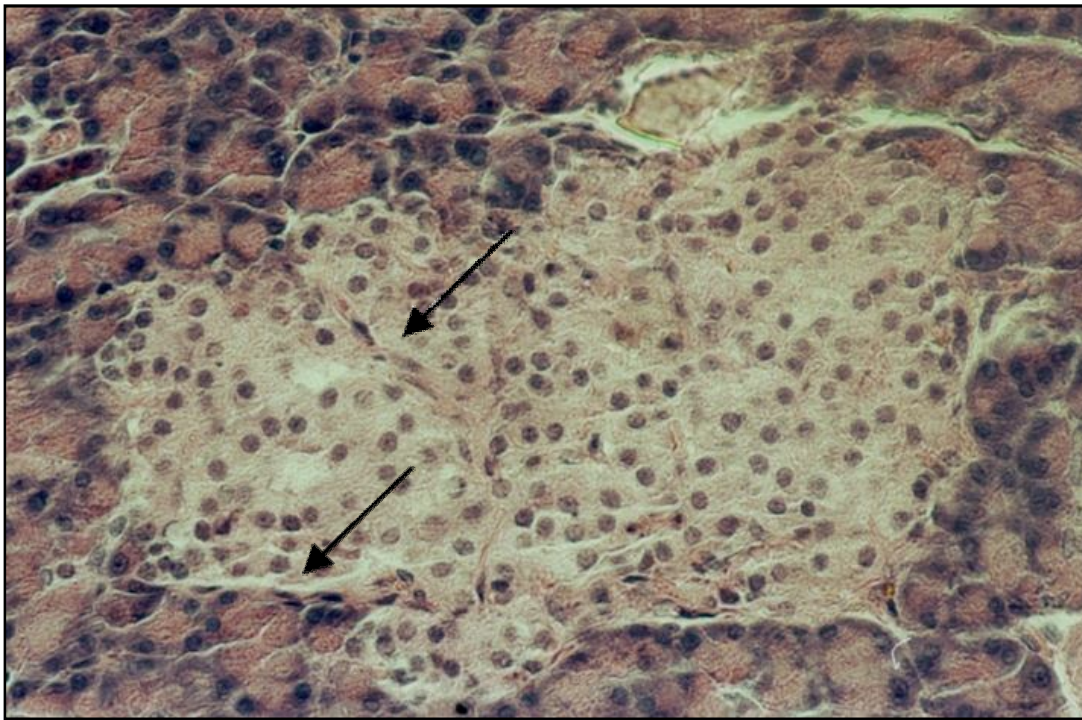


Fig. 1. Pancreas of an intact rat

A large islet contains numerous large cells. Connective tissue capsule is thin (↑).

Staining: hematoxylin and eosin.

Magnification: 400X.

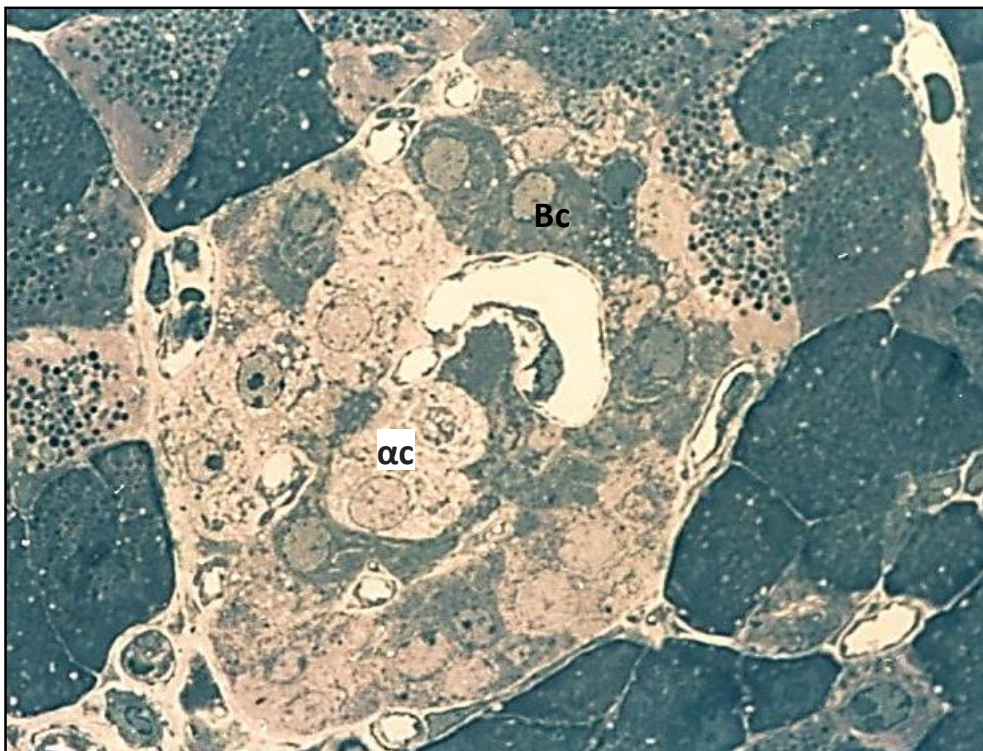
Fig.2. Pancreas of an intact rat

Bcells (Bc) are localized mainly in the center of the islet, their cytoplasm is basophilic. α -cells (αc) have lighter cytoplasm and a round shape.

Semi-fine section.

Staining: methylene blue.

Magnification: 1000X.



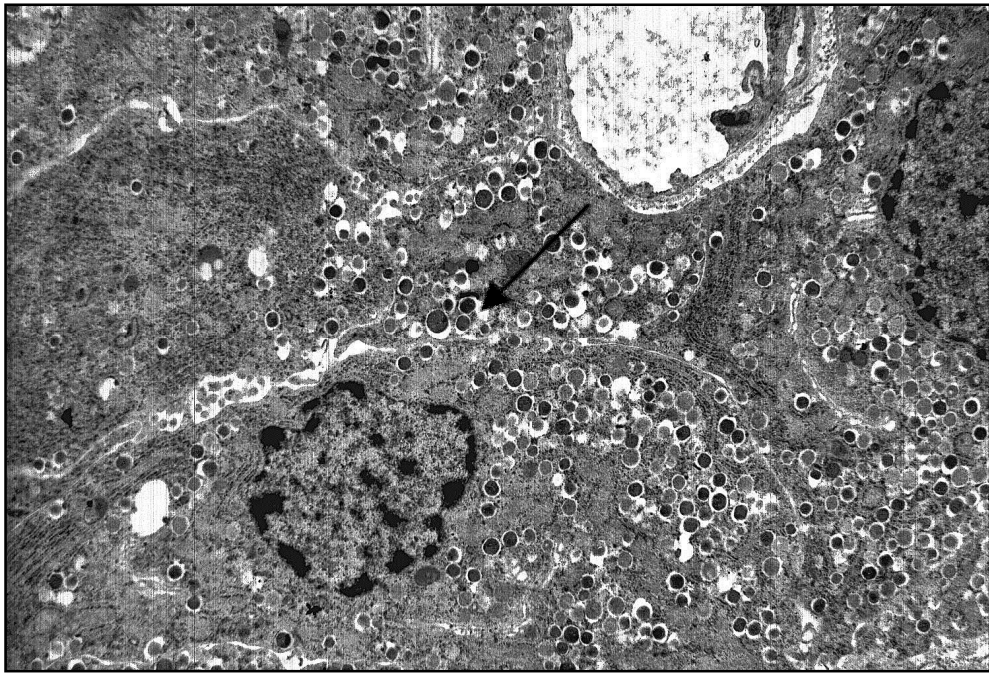


Fig.3. Pancreas of an intact rat

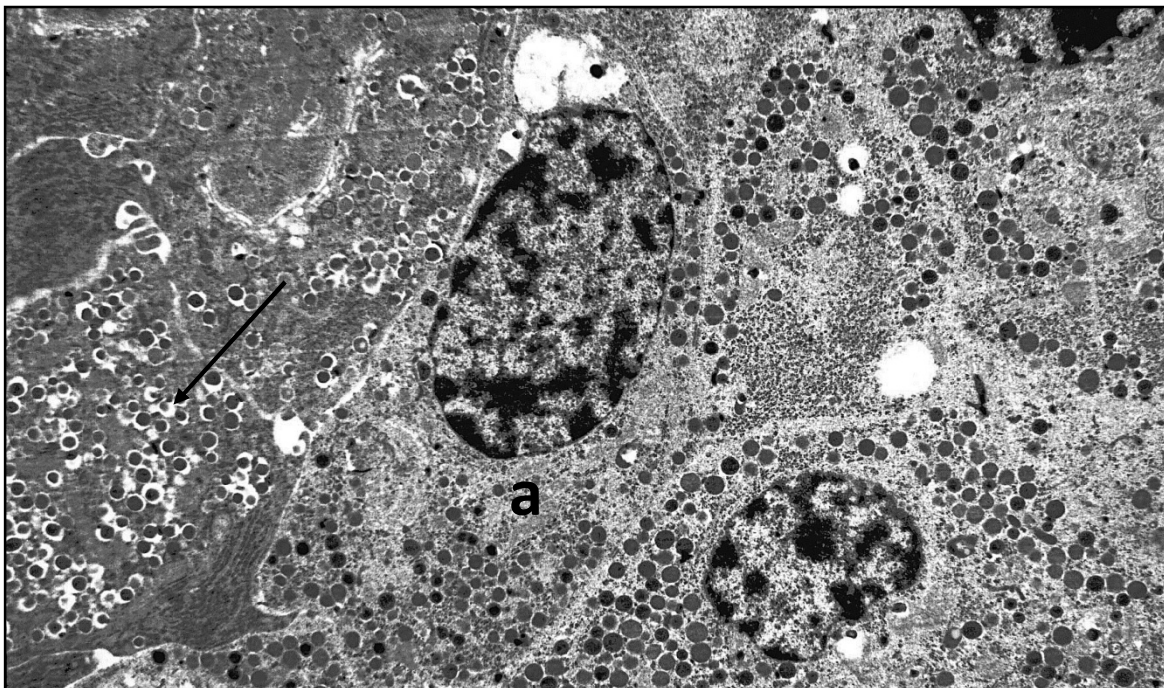
In the cytoplasm of B cells, the number of granules is different, they are located in foci. There are signs of cytoplasmic vacuolization, secretion of granules into the intercellular space (↑).

Staining: uranyl acetate, lead citrate. Magnification: 4000X.

Fig.4. Pancreas of an intact rat

α -cells (α). The nuclei are located eccentrically, the granules are mostly near the cell membrane. The borders are clear. Nearby there is the B-cell (↑) with a large number of granules. Staining: uranyl acetate, lead citrate.

Magnification: 4000X.



Almost all of them have an equally high electron density (Fig. 4). In all structures of the islet, a low intensity of staining on glycosaminoglycans is revealed. The reaction level to PAS-positive substances is the highest in the capsule and in the wall of the capillaries of the islets (Table 4).

SUMMARY. Thus, the structure of pancreatic islets of intact rats studied by us practically does not differ from the structure plan described in the literature [Ogneva, V. V., 1972; Puzyrev, A. A., 1974; Gordienko, V. M., 1978; Utekhin, V. I., 1979; Kolesnik, Y. M., 2004; Barabanov, V.M., 2014; Govendir, M., 1999; DominguezBendala, J., 2009]. The largest number is islets of medium size. As a component of the islets, B islet cells predominate, generally containing granules with an average electron density (55.8%). It should be noted that in most granules, the area occupied by the secretory material is approximately equal.

Morphofunctional characteristics of pancreatic islets in rats during the experiment

With hyperglycemia for 8 weeks

The study of the pancreas testified that in experimental hyperglycemia there is an increase of 30.5% in the number of mostly small islets and the preservation of a considerable number of medium-sized islets. In the latter, the number of cells is accurately reduced to 50.2 ± 5.6 , in intact – $75,2 \pm 2,5$ (Table 3). During aldehyde fuchsin staining, a decrease in the number of B cells in the islets is discovered (Fig.5). The greatest changes were observed in large islets (Fig. 6), in which the islet cells are mostly arranged by groups, and focal accumulations of small cells with a light cytoplasm and large rounded nuclei are identified around the capsule. In most islet cells the enlightened cytoplasm, its vacuolization and dystrophic changes in the nuclei are observed. Usually the nuclei make an irregular shape, are hypertrophied, have clear, but irregular boundaries; they are intensely colored, with a considerable number of heterochromatin granules. The area of the nuclei varies, in 22.4% of B-

islet cells it ranges from $12.6 \pm 2.7 \mu\text{m}^2$ to $23.2 \pm 4.5 \mu\text{m}^2$ (in intact ones this index is $15.2 \pm 3.7 \mu\text{m}^2$). The study of B cells made it possible to distinguish significant variations in the distribution of granules and the intensity of their staining (Fig. 7). Small islets are generally located near the excretory ducts (Fig.8). In some cells, dystrophic changes are observed in the islet architecture: cytoplasm vacuolization, chromatin condensation in the nucleus, or its leaching (Fig. 9, 10). An electron microscopic study showed that in these cases the architecture of B cells is characterized by significant structural changes.

In some elements, which were marked as cells of the first type, the number of granules is sharply reduced (Fig. 10,11) and there is an increase in the width of the electron-transparent gap between the membrane and the secretory material (the "core"), whose electron density varies, but primarily has a high osmiophilicity (73.1%). In these cells, the total number of granules can decrease to 14.5 ± 1.8 , whereas in intact cells this value is 44 ± 2.3 (Table 4). The area of the secretory material in the granules significantly decreases to $25,800 \pm 337 \text{ nm}^2$ (in intact - $39400 \pm 475 \text{ nm}^2$).

In other cells, the secretion of granules has the usual osmiophilicity; they are arranged by groups, merging into conglomerates near the cell membrane (Fig. 11). In the third ones, the granules are filled with osmiophilic contents, the electron density and the volume of them are different. In a number of instances, granules do not have secretory material and they appear optically empty.

The B-islet cells, which we classified as the second type, are 62.3% in the large islets, 46.4% in the medium ones; they retain the usual plan of the structure and contain 46.6 ± 3.8 granules in an area of $10 \mu\text{m}^2$, and the area of the secretory material in the granules is $37000 \pm 475 \text{ nm}^2$. In some B cells, the number of vacuoles increases, the intercellular spaces expand considerably; degeneration and swelling of mitochondria are observed (Fig. 12). α -cells are localized mainly in large and medium islets, are arranged by groups and contain a large number of intensely

stained granules (Fig. 13). Between the acinar cells there are single large D-islet cells, irregularly shaped, with a light cytoplasm, containing numerous granules (Fig. 14), as well as B-islet cells and acinar-insular elements (Fig. 15). The layers of connective tissue inside the islet are usually thickened; they have a fairly high PAS-positive activity (Fig. 16). A large number of PAS-positive granules is detected in the wall of blood vessels and in a capsule. The content of glycosaminoglycans slightly increases in the layers of connective tissue and in the wall of blood vessels (Fig. 17). In large islets, the reaction to glycosaminoglycans in capillaries is focal (Fig. 18). Electron diffraction patterns show that in the connective tissue of the islet and in its capsule, a focal increase in collagen fibers is observed, some of which are homogenized and decayed, and there are significant areas of mucoid swelling. Blood vessels are usually dilated and in the layers of connective tissue there are numerous mast cells containing a large number of granules (Fig. 19). Clumps of erythrocytes in the form of columns or conglomerates are revealed in the lumen of the vessels (Fig. 20). In most blood vessels, especially arteries, perivascular edema and hyperelastosis are revealed (Fig. 15). In the capillaries of the islet there is a focal extension of the pericapillary spaces, endothelial cells are enlarged in size, especially in the nucleated part.

SUMMARY. Hyperglycemia for 8 weeks leads to an increase in the number of mostly small islets. The number of cells in the islets decreases and some of them undergo a dystrophic change. Morphological and morphometric data made it possible to identify the appearance of two types of B-islet cells. The number of granules in B cells decreases, most of them show a high density of osmiophilic contents. In the connective tissue, the intensity of the reaction to PAS-positive substances increases, mucoid swelling zones appear, and the number of collagen fibers increases focally. Changes in the wall of blood vessels are revealed, especially in capillaries, specifically, perivascular edema; also there is an expansion of the nearendothelial space and stasis of the formed elements in them.

Table 2**NUMBER OF CELLS AS PART OF DIFFERENT ISLETS OF PANCREAS OF INTACT AND EXPERIMENTAL ANIMALS**

Object	Size of islets		
	Large	Medium	Small
Groups of animals			
Intact	110,3 ± 3,1	75,2 ± 2,5	12,3 ± 1,4
Hyperglycemia for 8 weeks	95,1 ± 4,8	50,2 ± 5,6*	7,8 ± 2,1
Hyperglycemia for 16 weeks	85,4 ± 5,1*	35,2 ± 4,9*	7,4 ± 2,6

* p < 0,05 in comparison with intact animals

Table 3**MORPHOMETRIC CHARACTERISTICS OF B CELLS OF PANCREATIC ISLETS IN INTACT AND EXPERIMENTAL ANIMALS (on an area of 10 μm²).**

Indices	Total number of granules	Granules with high density		Granules with an average density		Area of secretory material of one granule in nm ²
		Quantity	in %	Quantity	in %	
Groups of animals						
Intact	44 ± 2,3	19,5 ± 1,05	44,2	24,6 ± 2,07	55,8	39400 ± 223
Hyperglycemia for 8 weeks						
-1 st type of cells	14,5 ± 1,8*	10,6 ± 1,7*	73,1	3,8 ± 0,8*	26,7	25800 ± 337*
-2 nd type of cells	46,6 ± 3,8	34,6 ± 2,7*	74,2	12,1 ± 0,8*	25,9	37000 ± 475
Hyperglycemia for 16 weeks	34,6 ± 2,7*	21,8 ± 1,87	63,0	12,8 ± 1,5*	37,0	36600 ± 517 16450 ± 306*

* p < 0,05 in comparison with intact animals

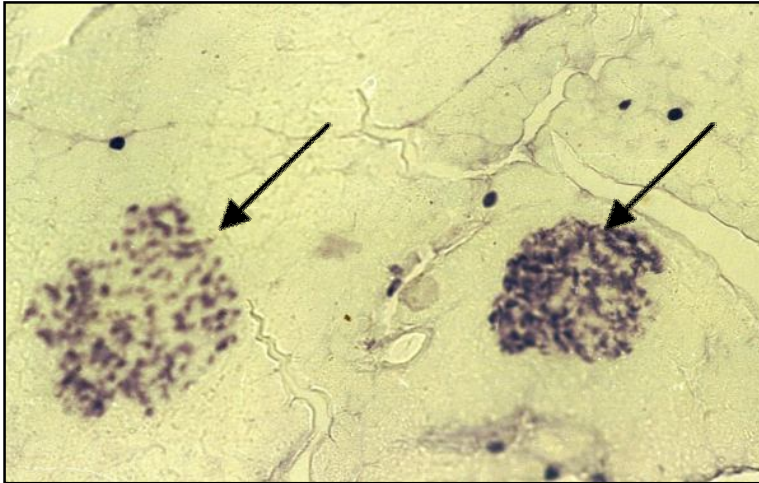

Fig.5. Rat pancreas at 8 weeks of hyperglycemia.

The number of B cells and their distribution in the islets (↑) vary.

Staining: aldehyde-fuchsin by Gabe.

Magnification: 300X.

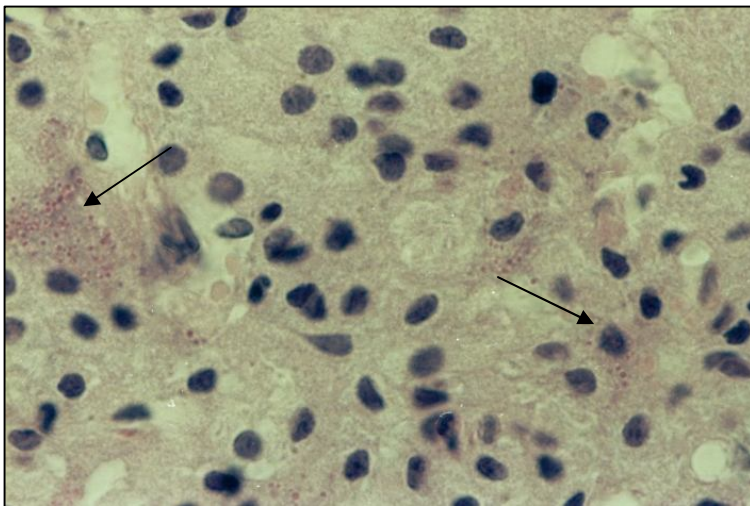


Fig.6. Islet of pancreas of rat. Hyperglycemia for 8 weeks.

The distribution of cells in the islet is focal (↑). In most islet cells, the cytoplasm is enlightened and the dystrophic changes in the nuclei are observed.

Staining: hematoxylin and eosin.

Magnification: 1000X.

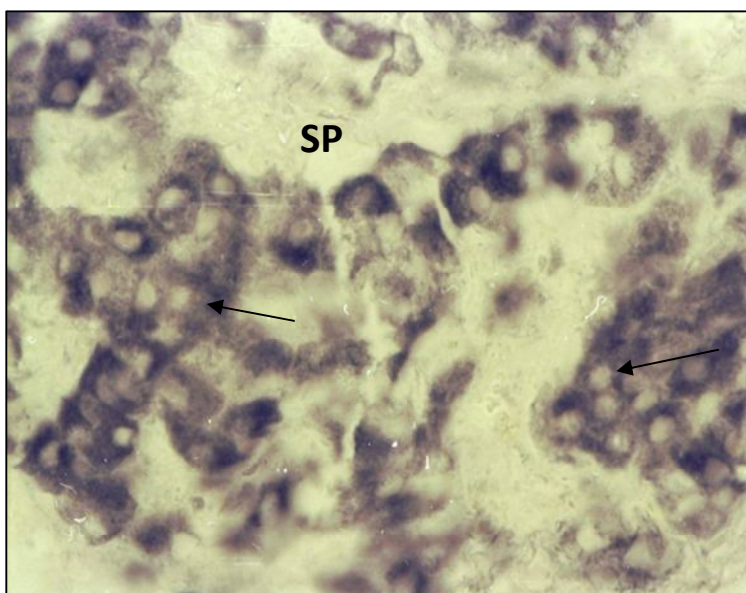


Fig. 7. Large pancreatic islet of rat at 8 weeks of hyperglycemia.

The localization of B cells (↑), the distribution of granules and the intensity of staining in them varies. In the cytoplasm of some B-islet cells, a large number of basophil granules are detected. The space (SP) between B cells is significant.

Staining: aldehyde-fuchsin by Gabe. Magnification: 1000X.

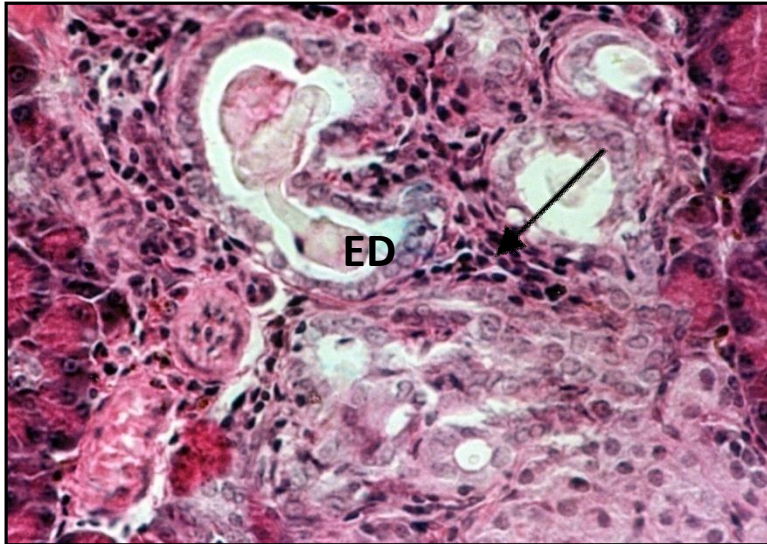


Fig.8. Rat pancreas at 8 weeks of hyperglycemia.

Around the excretory ducts (ED), small cells with intensely stained nuclei (↑) are revealed.

Staining: hematoxylin and eosin.

Magnification: 400X.

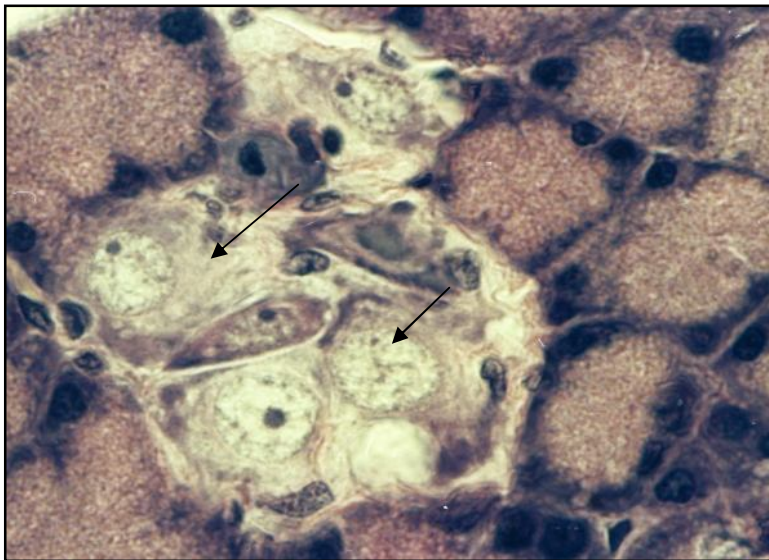


Fig.9. Rat pancreas at 8 weeks of hyperglycemia.

In some small islet cells, signs of dystrophic changes in the nucleus and cytoplasm are revealed (↑).

Staining: hematoxylin and eosin.

Magnification: 1000X.

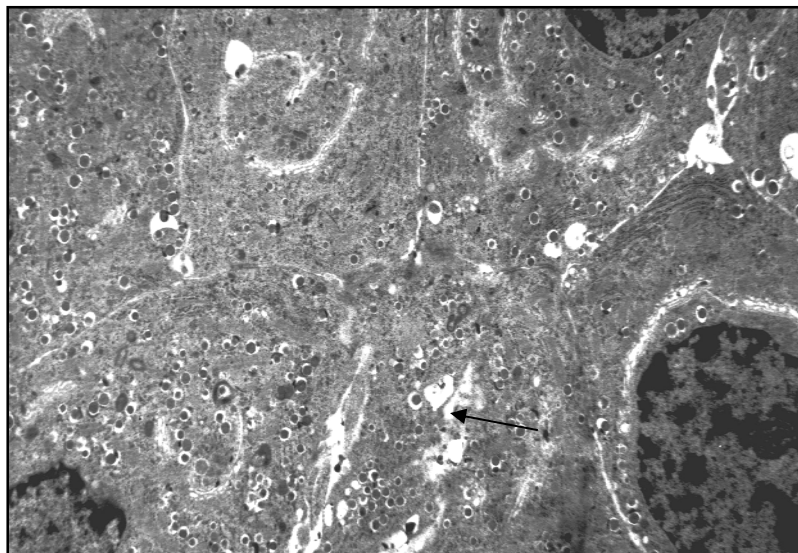


Fig.10. Rat pancreas at 8 weeks of hyperglycemia.

B-islet cells (Bc) are detected with a small number of diffusely arranged granules. In cells, the number of vacuoles increases (↑). Focal enlargement of intercellular spaces.

Staining: uranyl acetate, lead citrate.

Magnification: 4000X.

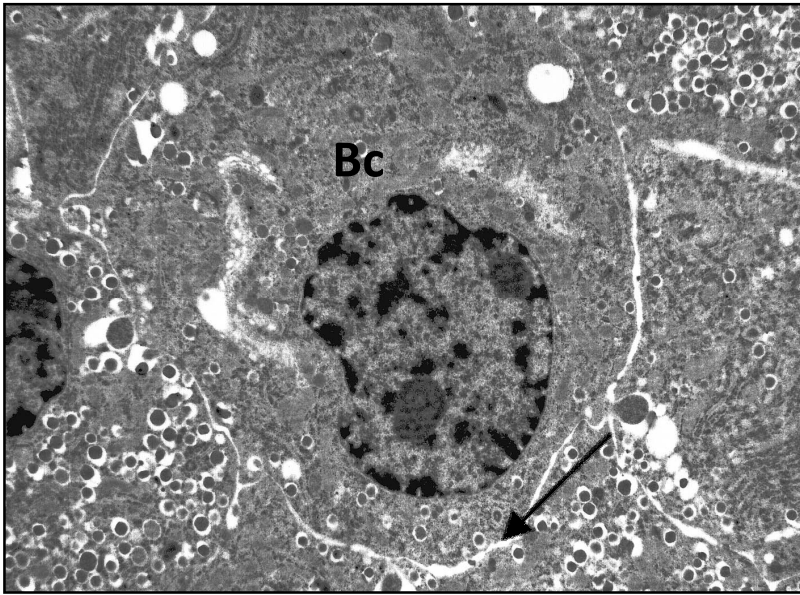


Fig.11. Rat pancreas at 8 weeks of hyperglycemia.

Granules in B cells are of various sizes, partially empty, are assembled into chains, located near its coat. In this cell (Bc) there are signs of dystrophy, many vacuoles, granules are singular. Focal enlargement of intercellular spaces (↑).

Staining: uranyl acetate, lead citrate.

Magnification: 4000X.

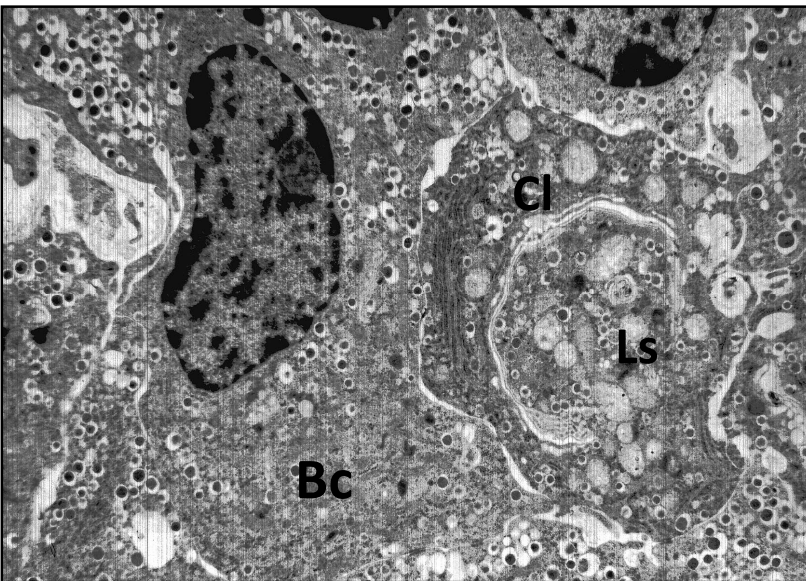


Fig.12. Rat pancreas at 8 weeks of hyperglycemia.

B cells (Bc) with a moderate quantity of granules that are localized near the cell membrane. In the cytoplasm of this cell (Cl) granules are singular, there are many vacuoles.

Degeneration and swelling of mitochondria. The presence of lysosome-like structures (Ls).

Staining: uranyl acetate, lead citrate. Magnification: 4000X.

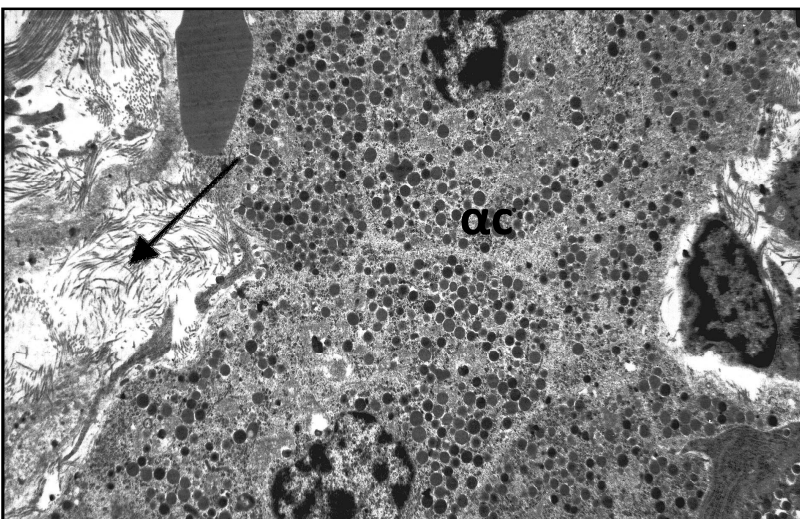


Fig.13. Rat pancreas at 8 weeks of hyperglycemia

α -cells (αc) contain numerous, intensely stained granules, concentrated mainly around the cytolemma. In the capsule there is a focal increase in the number of collagen fibers (↑), as well as the growth of mucoid swelling areas.

Staining: uranyl acetate, lead citrate. Magnification: 4000X.

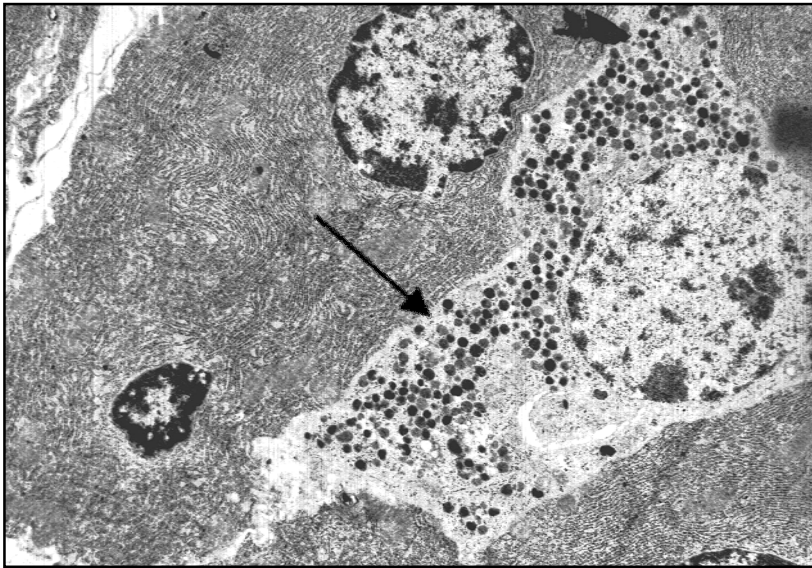


Fig.14. Rat pancreas at 8 weeks of hyperglycemia

Between the acinar cells there is Dcell (↑), irregularly shaped with a large number of granules arranged in groups near the cell wall.

Staining: uranyl acetate, lead citrate. Magnification: 5000X.

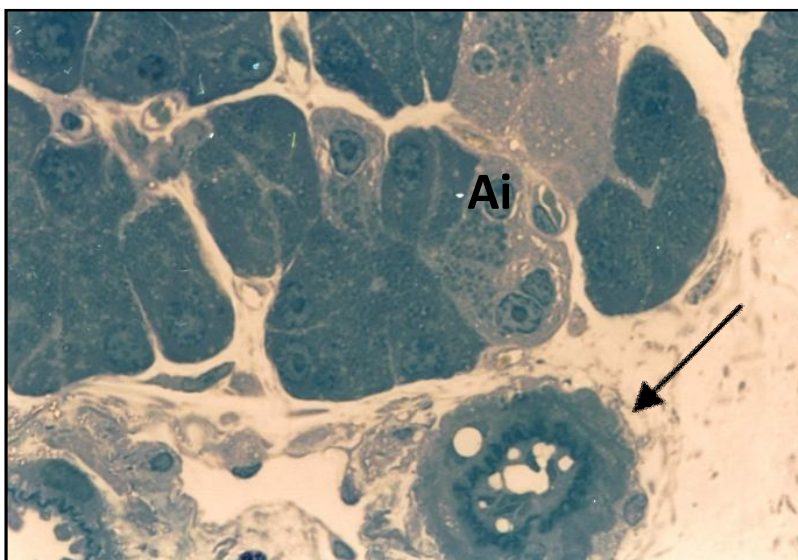


Fig.15. Rat pancreas at 8 weeks of hyperglycemia

Hyperelastosis and perivascular edema of the artery are identified (↑). Between the acini, single B-islet cells and acinar-insular cells appear (Ai)

Semifine section

Staining: methylene blue.

Magnification: 1000X.

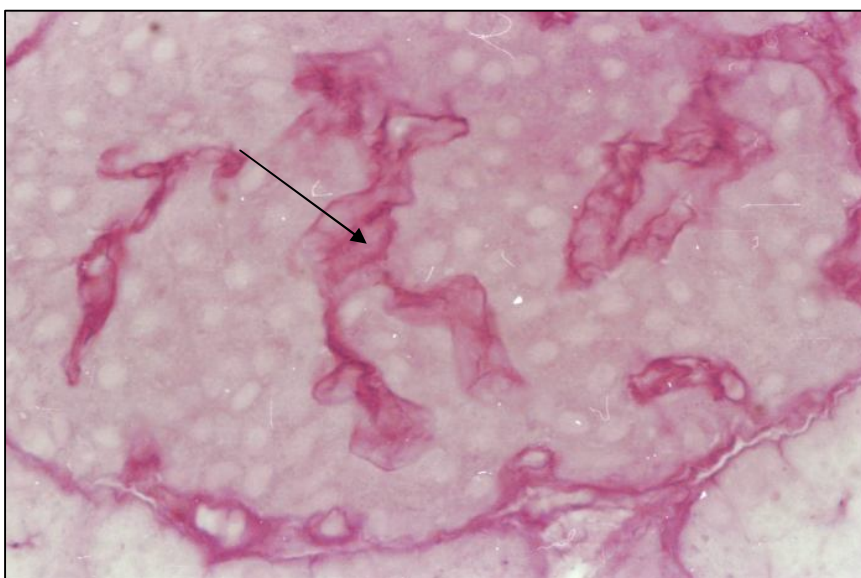


Fig.16. A large islet of the pancreas. Hyperglycemia for 8 weeks.

In the interlayers of the connective tissue of the islet and the wall of the hemocapillaries, a high intensity of the PAS-reaction is identified (↑). Staining: PAS-reaction of McManus

Magnification: 1000X.

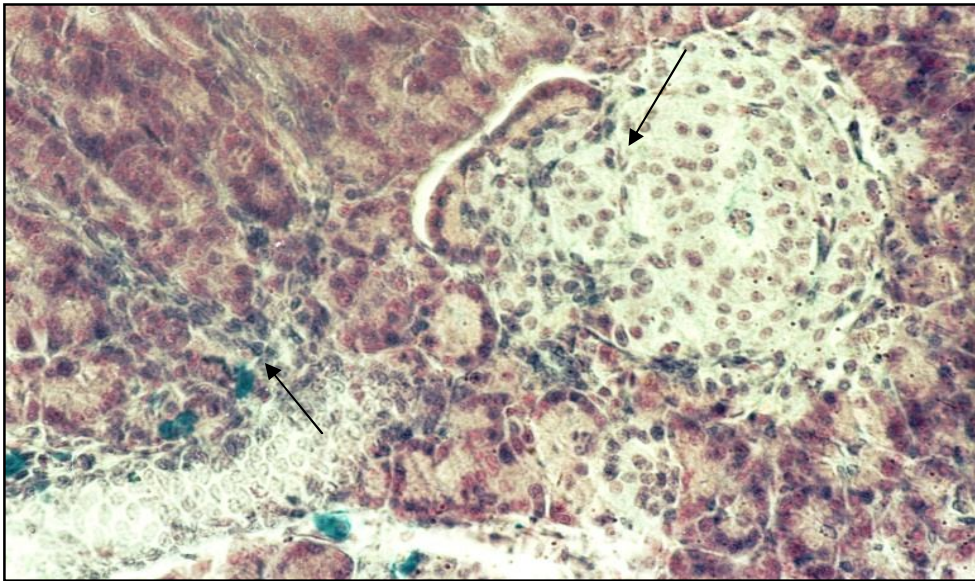


Fig.17. Rat pancreas at 8 weeks of hyperglycemia

Near the excretory duct (↑), the number of islet cells increases. The reaction to glycosaminoglycans in the capsule and in the connective tissue layers of the islet is moderately expressed. Along the vessels there is a large number of mast cells.

Staining: alcyan blue after Stidman.

Magnification: 400X.

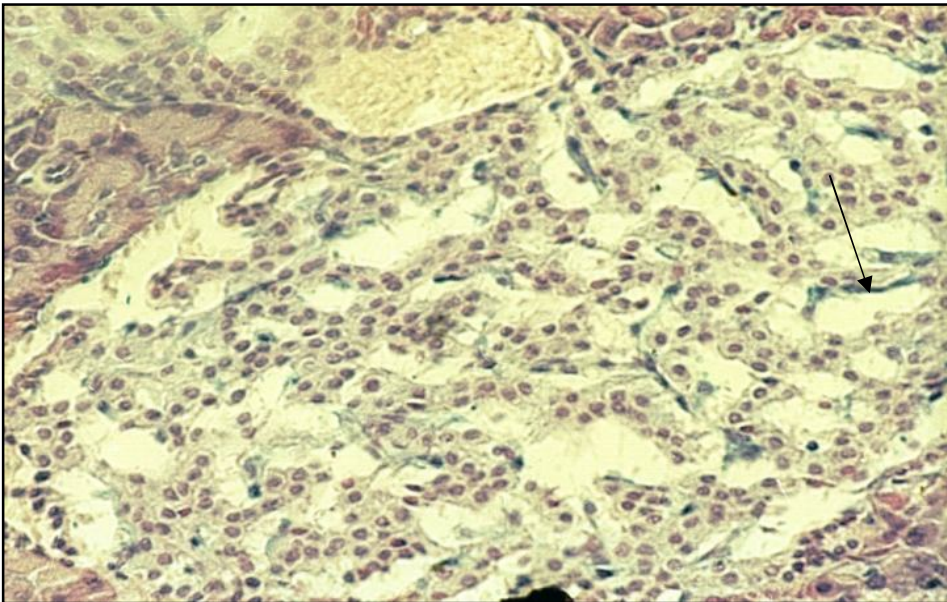


Fig. 18. A large islet of the pancreas of a rat at 8 weeks of hyperglycemia.

The blood vessels of the islet are significantly expanded, in their wall a focal enhancement of the reaction of GAGs is identified (↑).

Staining: alcyan blue after Stidman.

Magnification: 400X.

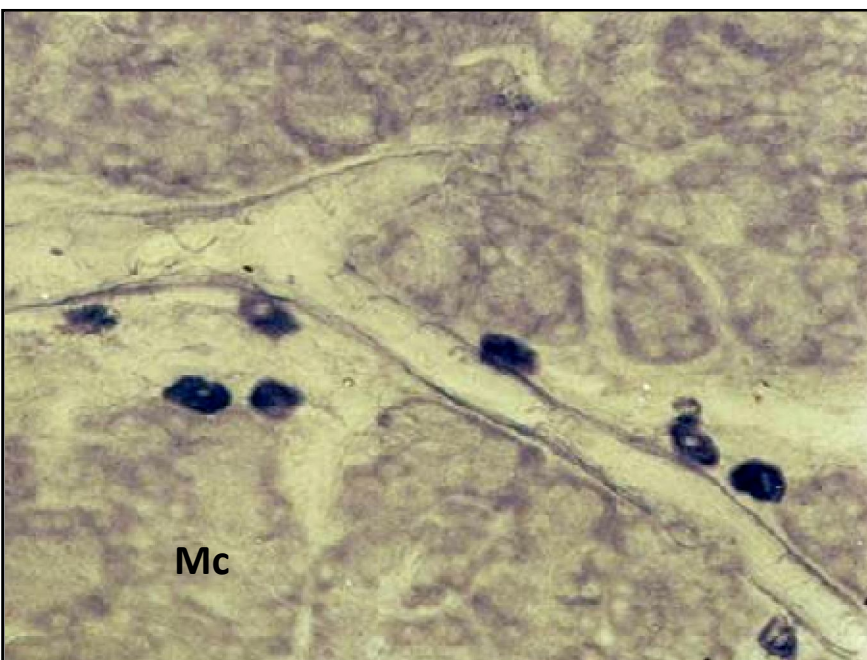


Fig. 19. Rat pancreas at 8 weeks of hyperglycemia

Greatly enlarged blood vessels around which there are numerous mast cells (Mc).

Staining: aldehyde-fuchsin after Gabe.

Magnification: 400X.

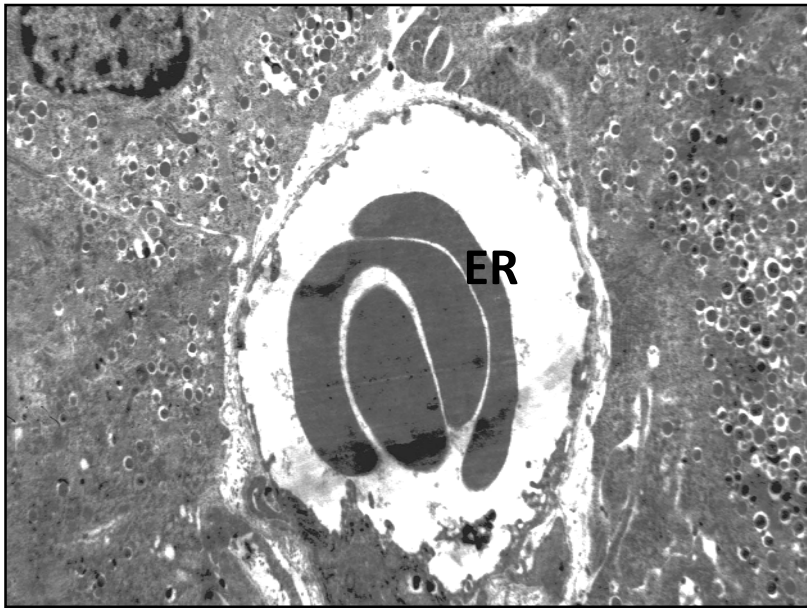


Fig.20. Rat pancreas at 8 weeks of hyperglycemia.

In the capillary there is an aggregation of erythrocytes (ER). Pericapillary space is focally extended. B cells contain a moderate quantity of granules arranged by groups.

Staining: uranyl acetate, lead citrate. Magnification: 4000X.

With hyperglycemia for 16 weeks

Under conditions of experimental hyperglycemia, a significant number of islets is revealed in the pancreas. In the setting of maintaining the size of the islets, there is a statistically significant decrease in the number of cells: in large ones, up to 85.4 ± 5.1 ; in the middle - to 35.2 ± 4.9 ; in small - to 7.4 ± 2.6 (Table2). This picture in the majority cases is associated with an increase in the size and number of hemocapillaries in the islet. Islet cells of the islet are arranged by groups (Fig. 21). In large islets in the subcapsular zone there are accumulations of small cells. In most islet cells, dystrophically altered nuclei and vacuolated cytoplasm are revealed (Fig. 22). When the B cells are stained with aldehyde-fuchsin, it can be seen that most cells contain a small number of granules (Fig. 23). In small islets, there is a similar tendency, the blood capillaries are enlarged, there is an aggregation of red blood cells, and some of the islet cells are dystrophically altered (Fig. 24). The size and shape of B cells are different, the number of specific granules in them decreases to 34.6 ± 2.7 on an area of $10 \mu\text{m}^2$, while in intact cells, this index is $44 \pm 2,3$ (Table3). At the same time, the number of average density granules is statistically-valid reduced to 12.8 ± 1.5 on

an area of $10 \mu\text{m}^2$. In some cells the granules are located near the membrane, there are signs of secretion. The area of the secretory material in the granule varies considerably from $16450 \pm 306 \text{ nm}^2$ to $36600 \pm 517 \text{ nm}^2$ (in intact - $39400 \pm 123 \text{ nm}^2$). Most granules have a small size and quite a considerable electronic density. In the cytoplasm of B cells, vacuoles of various sizes are revealed; the intercellular spaces are focally widened. In a number of instances, two types of B cells are clearly differentiated. Some have a light cytoplasm with a large number of vacuoles, dystrophically altered, with vacuolated mitochondria and singular granules. In other the cytoplasm is darker; specific granules are located either diffusely, or have focal localization. In these cells, granules are of a larger size (Fig. 25).

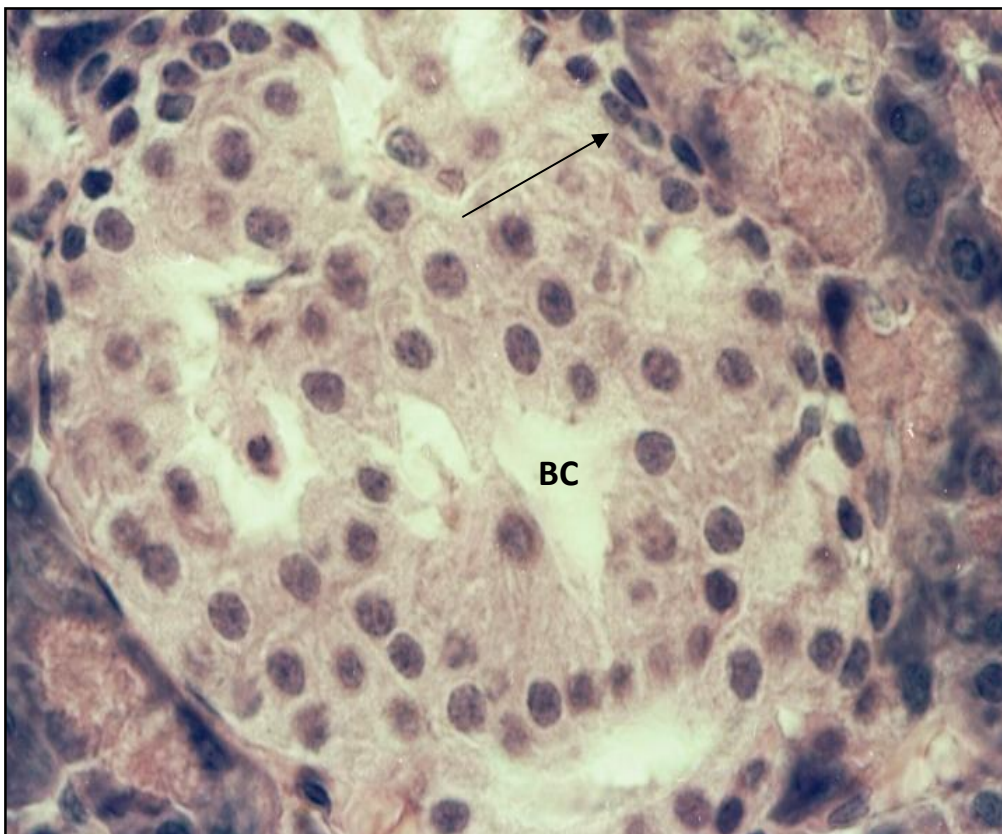
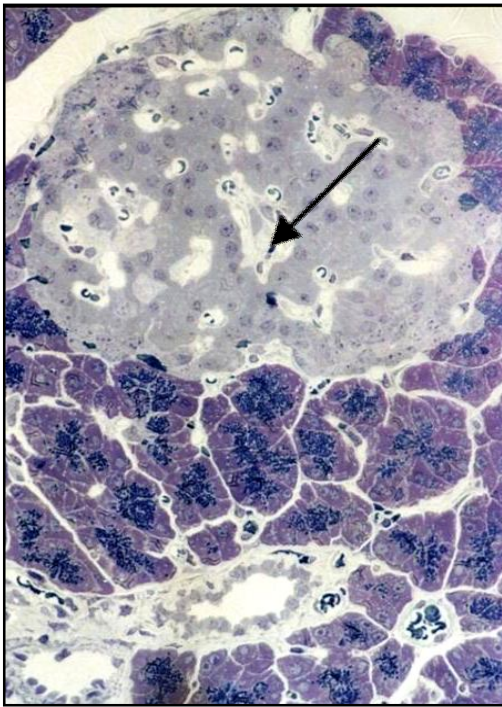


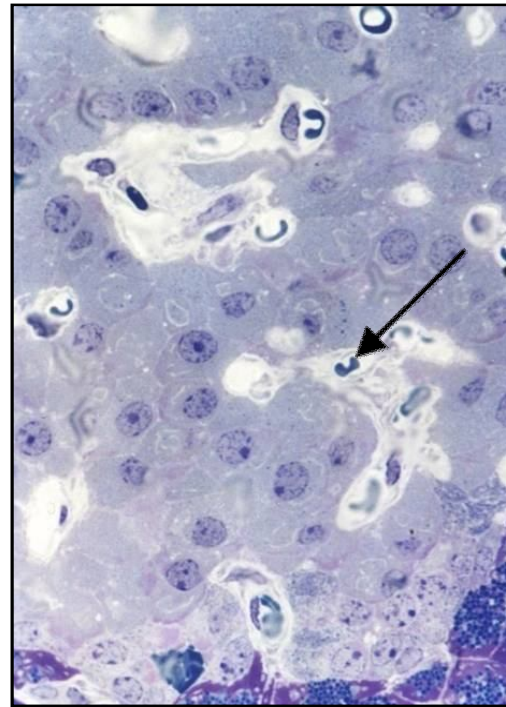
Fig.21. Pancreas of the rat at 16 weeks of hyperglycemia.

As part of the islet, cells are unevenly distributed; some of them have dystrophically altered nuclei and vacuolated cytoplasm. Blood capillaries (BC) are focal-enlarged. In the subcapsular zone of the islet there are areas consisting of small cells (\uparrow).

Staining: hematoxylin and eosin. Magnification: 1000X.



A



B

Fig.22. Pancreas of the rat at 16 weeks of hyperglycemia.

In a large islet, some cells have a vacuolated cytoplasm and obscure boundaries. The lumen of the capillaries varies and in some of them the abnormal red blood cells (↑) are detected.

Semi-fine section.

Staining: toluidine blue.Magnification: A– 600X; B– 1000X.

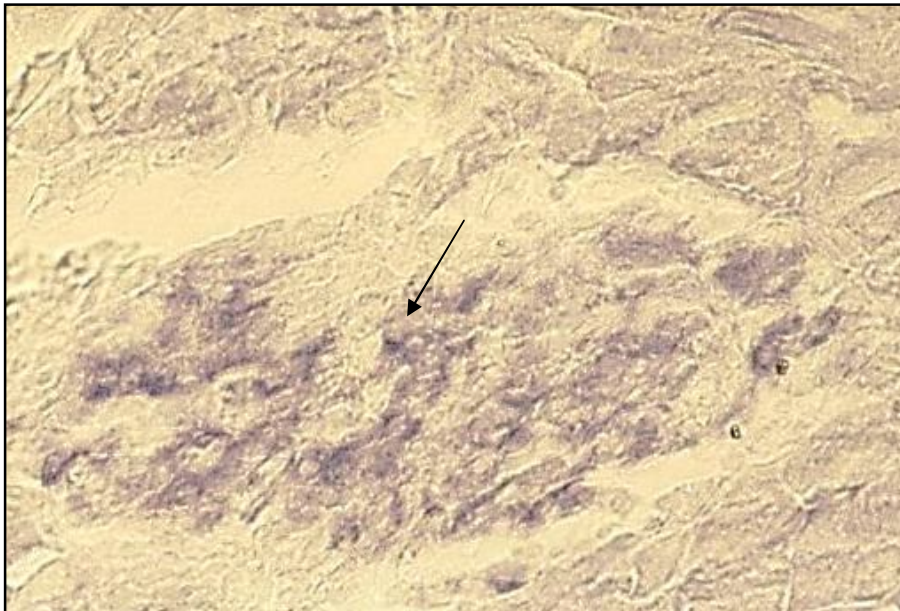


Fig.23. Pancreas of the rat at 16 weeks of hyperglycemia.

As part of a large islet (↑), there is a moderate quantity of B cells focally located, with a small number of granules, the distribution of which in the cytoplasm varies.Staining:aldehyde-fuchsin by

Gabe.Magnification: 1000X.

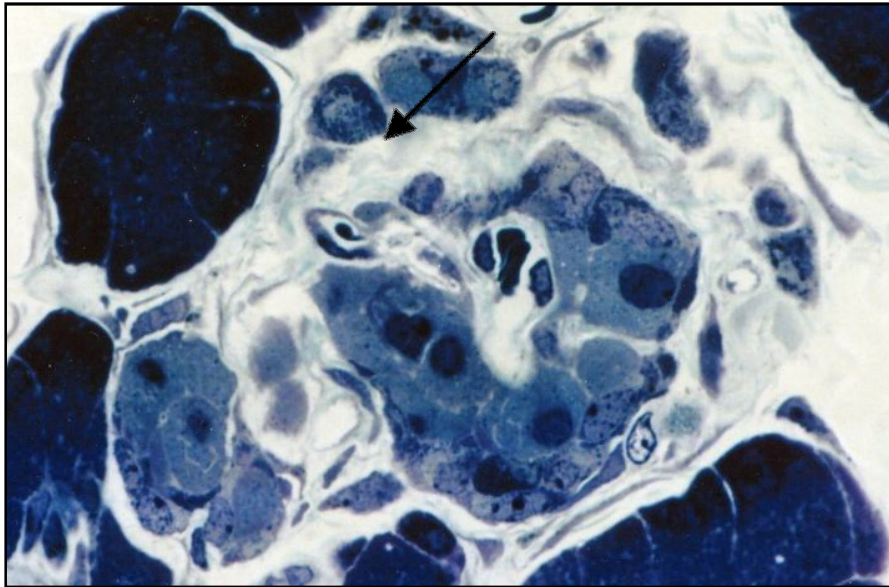


Fig.24. Pancreas of the rat at 16 weeks of hyperglycemia.

Cells in the small islet are focally located, between them there are well developed interlayers of connective tissue (↑) with signs of mucoid swelling. The structure of the cells is dystrophically altered.

Semi-fine section. Staining: toluidine blue. Magnification: 1000X.

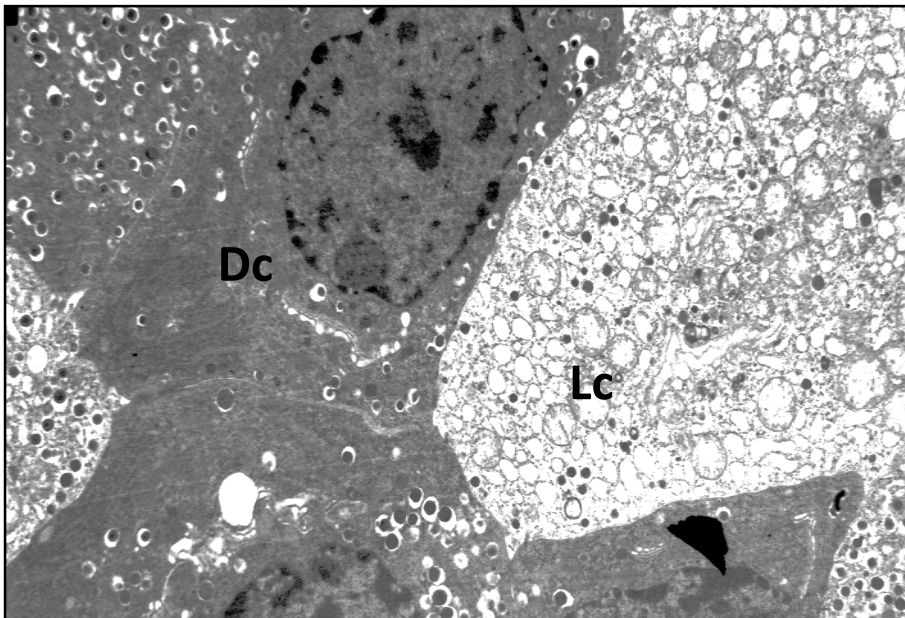


Fig.25. Pancreas of the rat at 16 weeks of hyperglycemia.

Light and dark B cells. Light islet cell (Lc) contains many vacuoles, dystrophically altered and vacuolized mitochondria, few granules. In dark islet cells (Dc), granules have focal localization and singular vacuoles.

Staining: uranyl acetate, lead citrate.

Magnification: 4000X.

The nuclei of B cells are generally hypertrophied, round in shape, and have abrupt but clear boundaries. In α -cells, the number of granules varies. In some cases, they are located mainly near the cell membrane, in others they are diffusely scattered along the cytoplasm (Fig. 26). Between the acini, large cells with a light vacuolated cytoplasm are identified, located singly or in small groups. Acinar-insular cells appear in the structure of the acini. Between the acini, large D cells are generally located alone, several of them are binucleated, contain singular granules. A part of the large and medium islets have a well-defined capsule and developed connective tissue interlayers that extend toward the interior (Fig. 27). In their

structure, numerous bundles of collagen fibers located in groups are identified (Fig. 26). The lumen of the blood capillaries is usually constricted due to endothelial cell hypertrophy. In their lumen, erythrocytes of various forms are detected. The periendothelial space is diffusely expanded. In the interlayers of the connective tissue of the pancreas, most blood vessels are enlarged in size and filled with a large number of formed elements (Fig. 28). Erythrocytes are usually adhered together in conglomerates. In arterial vessels, hyperelastosis, swelling of endothelial cells, increased thickness of the muscular membrane, perivascular edema and intensive PAS-positive reaction, especially in the intima are identified (Fig. 29, 30). In all islets, a significant number of PAS-positive granules in the capsule and in the wall of the blood capillaries are revealed (Fig. 30). The intensity of the reaction to glycosaminoglycans along the blood capillaries of the islet is moderately strengthened and has a focal nature (Fig. 31).

Summary. Thus, prolonged hyperglycemia is accompanied by a decrease in the number of cells in all islets, dystrophic changes in B-islet cells, a decrease in the number of mature granules in their cytoplasm.

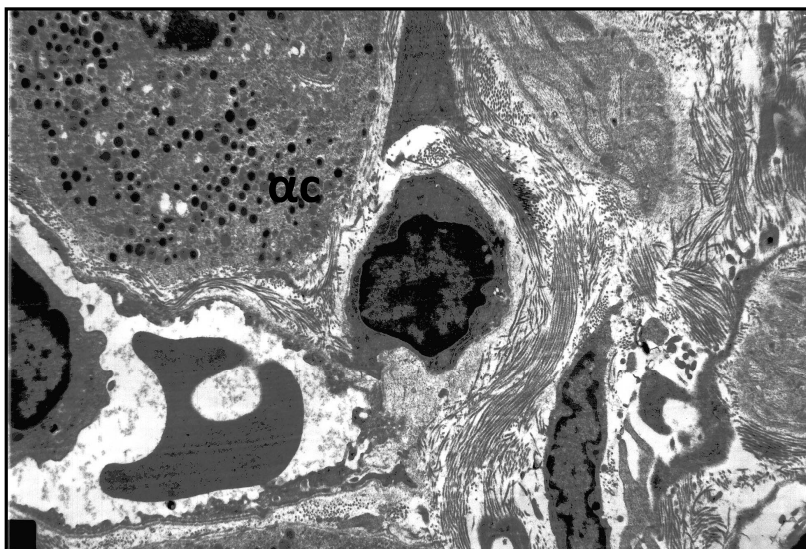


Fig.26. Pancreas at 16 weeks of hyperglycemia

In the interlayer of connective tissue, the amount of collagen fibers is increased. Pericapillary space is widened. α cell (α c) contains a moderate amount of granules diffusely located in the cytoplasm.

Staining: uranyl acetate, lead citrate. Magnification: 4000X.

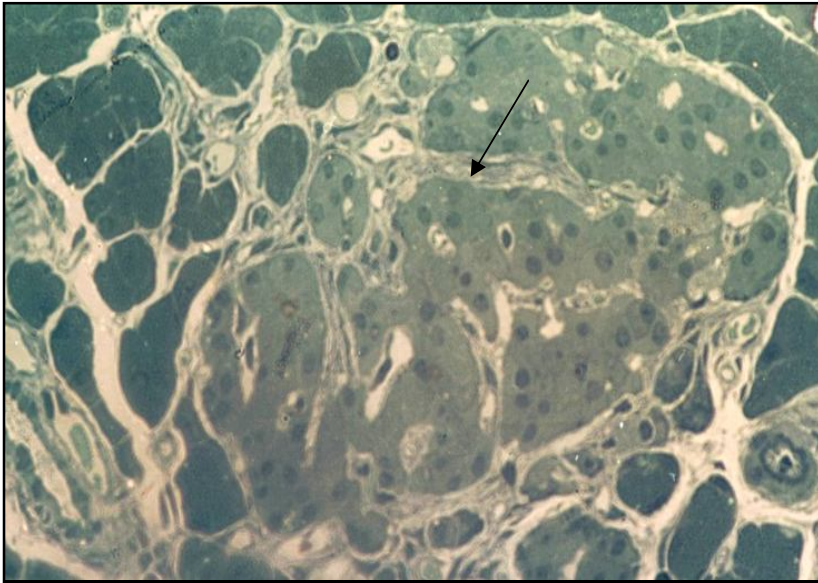


Fig.27. Pancreas of the rat at 16 weeks of hyperglycemia. The large islet has a well-defined connective tissue capsule from which numerous interlayers (↑) come off. The lumen of the blood vessels in the islet varies.

Semi-fine section.
Staining: methylene blue.
Magnification: 400X.



Fig.28. Pancreas of the rat at 16 weeks of hyperglycemia.

In the interlayers of the connective tissue, the blood vessels are expanded and filled with a large number of formed elements in the form of aggregations(↑).

Semi-fine section.
Staining: methylene blue.
Magnification: 400X.

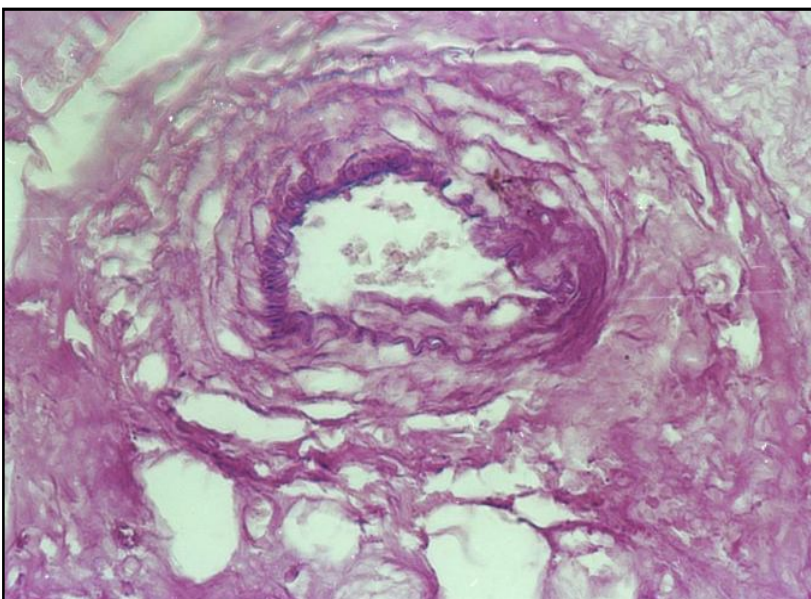


Fig.29. Pancreas of the rat at 16 weeks of hyperglycemia. In all layers of arteries and in interlayers of connective tissue, a high response to PAS-positive substances is revealed. A particularly large number of granules is localized in the intima (↑), and partially in the middle layer. Staining: PAS-reaction of McManus Magnification: 400X.

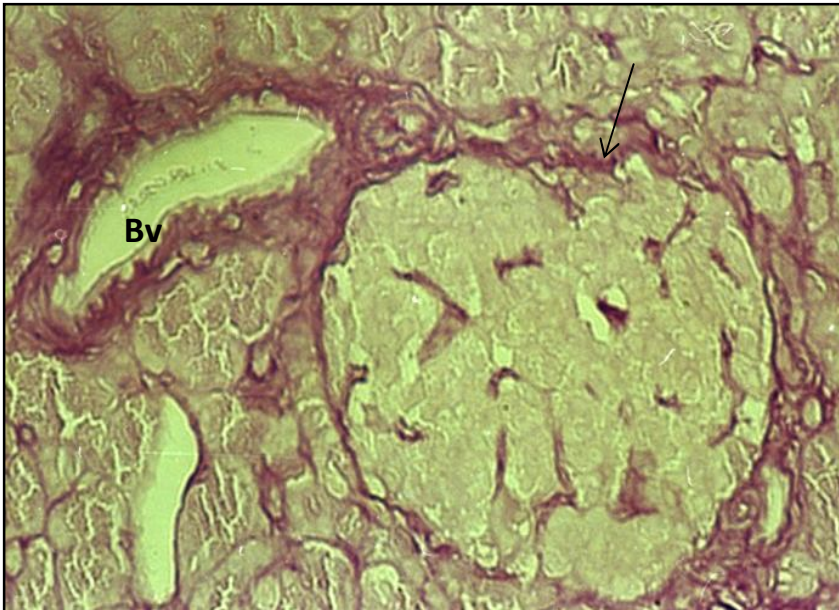


Fig.30. Pancreas of the rat at 16 weeks of hyperglycemia. An islet is of medium size with a well-defined capsule, in which an intense reaction to PAS-positive substances is detected (↑).

There is a diffuse increase in neutral polysaccharides in the walls of blood vessels (Bv).

Staining: PAS-reaction of McManus
Magnification: 400X.

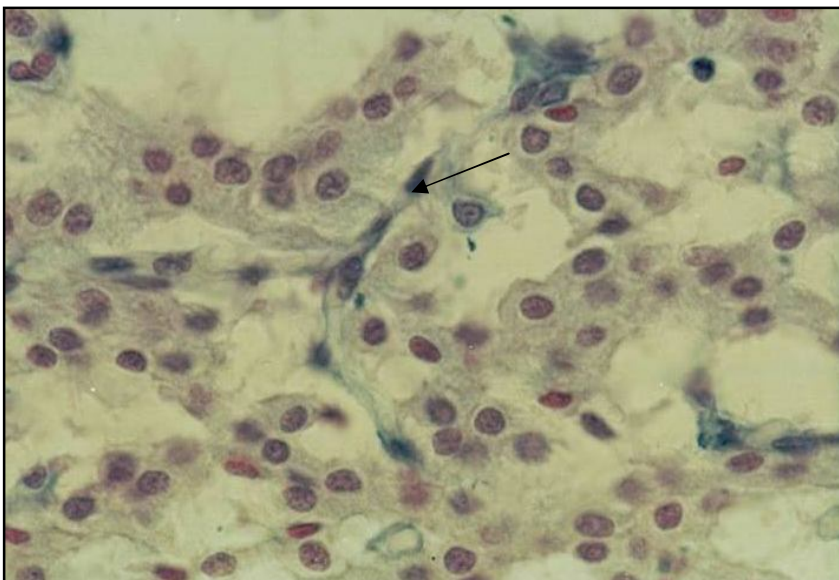


Fig.31. Pancreas of the rat at 16 weeks of hyperglycemia.

In some parts of the islet, the cells are unevenly distributed, the lumen of the capillaries is sharply widened in a focal point. The reaction to glycosaminoglycans along the blood vessels has focal localization (↑).

Staining: alcyan blue after Stidman.

Magnification: 1000X.

Two types of B cells with different structures appear. Numerous granules are found in α cells. In D-islet cells, granules are singular. Acinar-insular cells appear. The lumen of the capillary capillaries of the islet is focally constricted; the engorgement of the formed elements, endothelial cell hypertrophy, plasmorrhagic basement membrane lesions, pericapillary edema are revealed. In the interlayer of connective tissue, the amount of collagen fibers increases. In the wall of the arteries, the thickness of the muscular membrane increases and dystrophic changes in the smooth muscle cells are detected. The intensity of the reaction to PAS-positive

substances in the wall of blood vessels increases, and this is especially expressed in the vessels of the microcirculatory bloodstream.

The study of the effect of hyperglycemia on the pancreatic islets through the administration of glucose seems to be the most reasonable, since it creates the targeted functional load on insulin-producing B-endocrine cells.

In our study, hyperglycemia during 8 weeks is accompanied by a decrease in the number of B cells in all islets. But at the same time, there are quite numerous small islets, in which there are mainly B cells that have an intense staining of the cytoplasm. The number of B cells in the islet normally in the postembryonic period depends on the balance of their neoplasm and apoptosis, which is primarily defined by the level of glycemia. The new formation of B cells is mainly due to the activation of the division of already differentiated B-islet cells [Gordienko, V. M., 1978; Vesnina, I. A., 2001; Adler, A. I., 2000; Lipsett, M., 2002; Rooman, I., 2002; Chong, A.S., 2006; Veld, P., 2015]. Hyperglycemia has a mitogenic effect on B cells in diabetes mellitus, thence they lose the ability to proliferate at a rate commensurate with the rate of their decrease. And as a corollary to this, a new formation of B-islet cells occurs by differentiating the cells of the ducts of the pancreas [Demidova, I. Y., 2000; Goldberg, E. D., 2006; Wu, X., 2009].

During the experiment, in most islet cells dystrophic changes in the cytoplasm are observed. There is a significant variability in the structure of B cells, and along with this the most pronounced changes are noted in the granules. In most cases, the number of granules in B cells decreases sharply; the electron density of the secretory material increases and the area occupied by it increases. It has been established that under the preparation for secretion, the granules lose their electron density, the process of granulolysis starts, which is accompanied by the release of the contents of the granules into the cytoplasm and then into the pericapillary space. Taking into consideration all above, there is reason to believe that the capacity of these B cells has decreased. In some cases, the secretory material in the

granules is practically absent. The appearance of small islets containing a large number of granules with high osmiophilia of the secretory material seems to indicate the activation of granulopoiesis in the islet cells. It is likely that in this case there may be periodic increases in insulin levels, which probably leads to hyperinsulinemia [Gordienko, V. M., 1978; Puzyrev, A. A., 2006; Galstyan, G. R., 2008]. α -cells in this period are quite numerous and contain a large number of secretory granules, promoting suggestions about their secretion of glucagon. It is necessary to take into account the fact that glucagon has a stimulating effect on the state of secretion of B cells.

In large and medium-sized islets, the interlayers of connective tissue increase, in which the number of PAS-positive granules increases, and zones of mucoid swelling are observed. Blood vessels and especially capillaries in the islets are dilated, large erythrocyte accumulations are often detected in them. There is pronounced perivascular and pericapillary edema. All these signs indicate the damage of both large vessels and vessels of the microcirculatory bloodstream. Neutral polysaccharides mainly come from the blood channels, so an increase in the PAS-positive substances in the wall of the blood vessel is at a faster rate under the conditions of hyperglycemia. And as a result, transport of interstitial fluid through the vascular wall slows down, metabolic processes are disrupted, perivascular and pericapillary edema occur [Genyk, S. N., 1989; Bobyрева, L. E., 1996; Saltykov, B. B., 2000; Jialal, I., 1989]. The constant presence of an increased amount of glucose in the blood, its "peak" rises lead to the growth of significant structural damage to blood vessels.

With an extension of the experiment to 16 weeks, the number of cells in the islets is significantly reduced. It is considered that the adult has a slow renewal of populations of islet cells, and in diabetes mellitus B cell deficiency appears. It is proved that in diabetes mellitus the death of B cells occurs by means of apoptosis. It

has been established that B cells divide and develop slowly; their specific feature is a very long pre-replication, refractory period [30, Wu, X., 2009; Veld, P., 2015].

More often, dystrophic changes are detected in the cytoplasm and nuclei of B cells. In the latter, the number of specific granules can even increase, most of which have a small size and high electron density of the "core". Chronic hyperglycemia significantly reduces the ability of the remaining B cells to respond to insulin secretion to acute stimulation of glucose, resulting in the accumulation of secretory granules in the cytoplasm of islet cells. Structural changes in α -cells are observed; quite often their granules are localized near the cell membrane, which indicates their secretory activity. The increase in the hormone level in α -cells depends on the severity of the process and is determined, apparently, by the degree of decrease in insulin the secretion, because it is known that glucagon is not only the most powerful glycemic factor, but it also has a stimulating effect on B cells, which is one of the compensatory mechanisms during hyperglycemia. Numerous insular-acinar cells with signs of functional activity appear, probably this is the result of compensation with a decrease in tumor formation of islet cells, or a way of doubling structures to ensure a diminished function of the organ [Gordienko, V. M., 1978; Kolesnik, Y. M., 1996; Kolesnik, Y. M., 2004]. In the connective tissue of the islets, the number of collagen fibers increases, the response to glycosaminoglycans (GAGs) increases, the number of PAS-positive substances increases (Table 6).

It has been established that prolonged hyperglycemia is accompanied by the development of metabolic disorders, in particular, the nonenzymatic glycosylation of proteins, and, in the first place, the blood proteins, in particular, hemoglobin, is enhanced. And this, eventually, leads to a deterioration in the oxygen-transport function of the blood and the development of tissue hypoxia, especially those that provide trophic support [Genyk, S. N., 1989; Bregovskiy, V. G., 2001; Shestakova, E.A. 2012; Estacio, R. O., 2000]. There are data indicating that in diabetes mellitus the relationship between the processes of anabolism and catabolism of GAG in the

basement membranes of blood vessels is broken. It has been established that free radical oxidation products, and their quantity increases with hyperglycemia, cause disorganization of connective tissue, in particular, these products affect GAG, the decay of which can lead to degeneration of the extracellular matrix and increase its permeability. According to several authors, the increase in sclerotic processes in diabetes mellitus is a consequence of the imbalance between the formation and destruction of collagen fibers in the setting of changes in carbohydrate metabolism [Geller, L. I., 1975; Baranov, V. G., 1983; Dedov, I. I., 2006; Lipatov, D.V., 2012]. With prolonged hyperglycemia, narrowing of the blood capillaries is observed, due to a diffuse increase in the subendothelial spaces. Most blood vessels are dilated, filled with a large number of formed elements, agglutinated together in conglomerates. In the arterial vessels there is a thickening of the muscular membrane, perivascular edema and an increase in the level of reaction to PAS-positive substances. The high concentration of glucose has a multidirectional effect on the biosynthesis and metabolism of proteins and GAG of the basement membranes of the vessels, as well as the intercellular matrix, which eventually leads to an increase in permeability and the development of angiopathies, in the morphological appearance of which there are several important points. Firstly, there is a thickening of the basement membrane, the significance of which for the vessels of the microcirculatory bloodstream is great, since it provides the structural stability of the vascular wall, as well as the endothelial cells adhesion to its regenerating layers, which is necessary to restore the inner layer of blood vessels after their damage. It is the increase of glucose concentration that leads to an increase in the biosynthesis of such components of the basement membrane of endothelial cells, as fibronectin, collagen IV and laminin, which apparently causes its thickening [Saltykov, B. B., 1984; Efimov, A. S., 1989; Saltykov, B. B., 2000; Bregovskiy, V. G., 2001; Podgrebelniy, A. N., 2005]. Quite often, along with the thickening of the basement membrane, its segregation into layers is observed, between which collagen fibers are defined.

Secondly, there is an increase in vascular permeability, caused by dysfunction of endothelial cells and the extracellular matrix. And since the cells of the vascular endothelium are insulin-independent by the consumer of glucose, in hyperglycemia, the intracellular content of this monosaccharide also sharply increases, so the endothelial cells become the predominant targets of glucotoxicity [Geller, L. I., 1975; Lysenko, L. V., 1990; Saltykov, B. B., 2000; Balabolkin, M. I., 2004; Gordiunina, S.V. 2012].

The nature of morphological changes with sustained hyperglycemia in the setting of developing compensatory-adaptive reactions is indicative of the progression of pathological processes in the cells and blood vessels of the islets of the pancreas. Thus, the biological essence of compensatory-adaptive reactions in some cases may be appropriate and lead to positive results, in others it may turn this process into a retroaction of the body leading to the development of damages.

Dihydroquercetin and its role in the treatment of complications of hyperglycemia and diabetes mellitus

The purpose of DM therapy is to achieve the maximum lowering of hyperglycemia to the level observed in a practically healthy person, which should be accompanied by a decrease in the frequency of vascular complications of diabetes. Traditional treatment of hypoglycemia does not interfere with the development of diabetic microangiopathy and only slightly slows it down with solid compensation for metabolic disorders. Even with the use of vasoprotectives and with sufficient stabilization of metabolic shifts the progression of diabetic microangiopathy is marked [Gorbenko, N. I., 1999; Demidova, I. Y., 2000; Nedosugova, L. V., 2004; Smolyanskiy, B. L., 2004; Ametov, A. S., 2005; Dmitriev, L. F., 2005; Zhestovskiy, S. S., 2007; Balabolkin, M. I., 2008; Gavrovskaya, L. K., 2008; Nedosugova, L. V., 2008; Shestakova, E.A. 2012; Estacio, R. O., 2000; Calafiore, R., 2004; Faerch, K., 2009; Fonseca, V., 2011; Phung, O.J., 2014].

Consequently, the drugs affecting mainly hemocoagulation, do not provide sufficient prevention of the damage of microcirculatory bloodstream, which requires further development of drugs that “strengthen” the vascular wall.

Bioflavonoids are natural protectors against “oxidative stress” caused by an increase in the amount of free radicals in the body.

Recent years are characterized by a growing interest of researchers to oxidative stress, as one of the key mechanisms for the development of diabetic microangiopathies [Balabolkin, M. I., 2003; Lukyanova, L. D., 2007; Volchegorskiy, I. A., 2008; Androsova, O.G. 2014; Mazo, V.K., 2014; Orci, L., 1974; Rice-Evans, CA., 1995; Blostein-Fujii, A., 1999; Fushiya, S., 1999; Liang, Y. C., 1999; Wang, J.Y., 2014]. This is not surprising, since high-reactive products of oxidative lipid degradation and free oxygen radicals formed as a result of self-oxidation of glucose have a damaging effect on the vascular endothelium and are involved in the formation of insulin resistance, the main pathogenetic part of type 2 diabetes mellitus. The determination of angiotropism of lipid peroxides led to progress in the field of antioxidant therapy of diabetes mellitus. In particular, it was testified that with the help of antioxidants it is possible to achieve a pronounced clinical effect in patients with diabetes mellitus. Not all antioxidants retard the development of micro- and macroangiopathies to the same extent.

At the present time, the greatest hopes are connected not with synthetic, but natural antioxidants [Nifantiev, E. E. and others., 2002; Uminskiy, A. A., 2007; Volchegorskiy, I. A., 2008; Rogovskiy, V.S., 2013; Mazo, V.K., 2014; Nijveldt, R. J., 2001]. Among the natural antioxidants from plant material, bioflavonoids are of special interest, which not only “catch” free oxygen radicals, its so-called “active forms”, but also have a positive effect on the vascular wall and hemostatic system.

A great scope of work on the search for new antioxidant drugs is represented by combinations with flavonoid nature from plant material, among which dihydroquercetin (DHQ) takes not the last place. It is a lipophilic substance with very

valuable qualities: firstly, DHQ exhibits high antioxidant activity, it is resistant to auto-oxidation and has low toxicity. Secondly, Siberian and Dahurian larch can serve as a rich raw material for industrial production of DHQ. Dihydroquercetin is manufactured by Ametis company according to Technical Requirements 2455-003-4875962-04, has a state registration of medicines of the Russian Federation.

Dihydroquercetin is the main flavonoid compound of Siberian and Dahurian larch, its content is up to 3.5% of dry weight. Flavonoids reduce the aggregation of formed elements, decreasing the negative charge of blood vessel walls; they prevent thrombosis, and also reduce vascular permeability, which explains their antiedematous, anti-inflammatory and antiallergic action [Nifantiev E. E. and others, 2002; Teselkin, Y. O., 1996; Uminskiy, A. A., 2007; Zhanataev, A. K., 2008; Chernikova, N. A., 2010; Nifantiev E. E., 2012].

As a result of the experimental preclinical study of DHQ, it was shown that the medication has antioxidant characteristics, capillaroprotective and antiedematous activity, which exceeds the activity of quercetin. In its chemical analysis DHQ is an exceptionally active antioxidant [Teselkin, Y. O., 1996; Volchegorskiy, I. A., 2008; Mazo, V. K., 2014; Wang, J. Y., 2014], i.e. a substance that connects free radicals and deprives them of harmful activity. At the same time the level of antioxidant activity makes it possible to place it on the first positions among substances of a similar spectrum of action. The antioxidant effect of DHQ is associated with their ability to accept free radicals and/or chelate metal ions that catalyze oxidation processes. It is expected that the mechanism of the antioxidant effect of dihydroquercetin consists of intercepting lipid radicals. A number of studies have shown that increasing the resistance of body tissues to the damaging effect of high blood sugar, caused by DHQ, makes it possible to reduce the likelihood of diabetes and to ease the course of developing complications [Uminskiy, A. A., 2007].

With hyperglycemia in the setting of dihydroquercetin administration during 8 weeks

The administration of dihydroquercetin in the setting of hyperglycemia leads to an increase in the number and size of mostly large and to a lesser degree medium islets, many of which are located near the excretory ducts of the gland (Fig. 32, 33). The number of cells in the islets increases significantly: in large islets up to 150.3 ± 5.4 ; in small ones up to $15,3 \pm 1,8$, in intact rats their amount is correspondingly $95,1 \pm 4,8$ and $7,8 \pm 2,1$ (Table 4). The majority of islet cells have a typical structure, the capsule of the islets is thin, and numerous small cells are diffusely located in the subcapsular zone (Fig. 34). The use of aldehyde-fuchsin for the evaluation of B cells has revealed that they are predominant in the islet structure, have an intensive staining in most cases (Fig. 35). Most of the B-islet cells in their cytoplasm contain numerous granules, the number of which is 48.1 ± 2.3 on an area of $10 \mu\text{m}^2$ (Table 5). Along with this the number of granules having an average density of secretory material is 29.8 ± 3.07 , which is almost 40% more than in hyperglycemia, without the administration of dihydroquercetin. Granules are generally located diffusely, but the largest accumulations are discovered near the cell membrane, in places where there are zones of increased intercellular space and in the perivascular zone (Fig. 36, 37). In most granules, the average area of the secretory material is $48,200 \pm 278 \text{ nm}^2$, while with hyperglycemia in control this index varied from $25,800 \pm 337 \text{ nm}^2$ to $37,000 \pm 475 \text{ nm}^2$ (Table 5). The nuclei of B cells are mainly round in shape, hypertrophied and their area is $28.2 \pm 2.1 \mu\text{m}^2$, with hyperglycemia in control this index varied from $12.6 \pm 2.7 \mu\text{m}^2$ to $23.2 \pm 4.5 \mu\text{m}^2$. The boundaries of the nuclear membrane are abrupt, and in some areas are indistinct. Often there are signs of secretion of granule contents into the intercellular space.

Table 4

**THE NUMBER OF CELLS AS PART OF
VARIOUS PANCREATIC ISLETS
OF EXPERIMENTAL ANIMALS**

Object	Size of islets		
	Large	Medium	Small
Groups of animals			
Hyperglycemia for 8 weeks (control 1)	95,1 ± 4,8	50,2 ± 5,6	7,8 ± 2,1
Hyperglycemia for 8 weeks in the setting of dihydroquercetin	150,3 ± 5,4*	45 ± 3,7	15,2 ± 1,8*
Hyperglycemia for 16 weeks (control 2)	85,4 ± 5,1	35,2 ± 4,9	7,4 ± 2,6
Hyperglycemia for 16 weeks in the setting of dihydroquercetin	185,3 ± 7,5**	72,3 ± 3,7**	18,7 ± 2,2**

* p < 0,05 in comparison with 1st control group

** p < 0,05 in comparison with 2nd control group

Table 5

**MORPHOMETRIC CHARACTERISTICS OF B CELLS OF PANCREATIC
ISLETS IN EXPERIMENTAL ANIMALS (on an area of 10 μm²).**

Indices	Total number of granules	Granules with high density		Granules with an average density		Area of secretory material of one granule in nm ²
		Quantity	in %	Quantity	in %	
Groups of animals						
Hyperglycemia for 8 weeks (control 1)						
-1 st type of cells	14,5 ± 1,8	10,6 ± 1,7	73,1	3,8 ± 0,8	26,7	25800 ± 337
-2 nd type of cells	46,6 ± 3,8	34,6 ± 2,7	74,2	12,1 ± 0,8	25,9	37000 ± 475
Hyperglycemia for 8 weeks in the setting of dihydroquercetin	48,1 ± 2,3	18,2 ± 1,24*	37,8	29,9 ± 3,07*	62,1	48200 ± 248*
Hyperglycemia for 16 weeks (control 2)	34,6 ± 2,7	21,8 ± 1,87	63,0	12,8 ± 2,5	37,0	36600 ± 517
Hyperglycemia for 16 weeks in the setting of dihydroquercetin	51,6 ± 4,05**	25,75 ± 4,1	49,9	25,8 ± 0,7**	50,1	16450 ± 306
						33900 ± 475**

* p < 0,05 in comparison with 1st control group

** p < 0,05 in comparison with 2nd control group

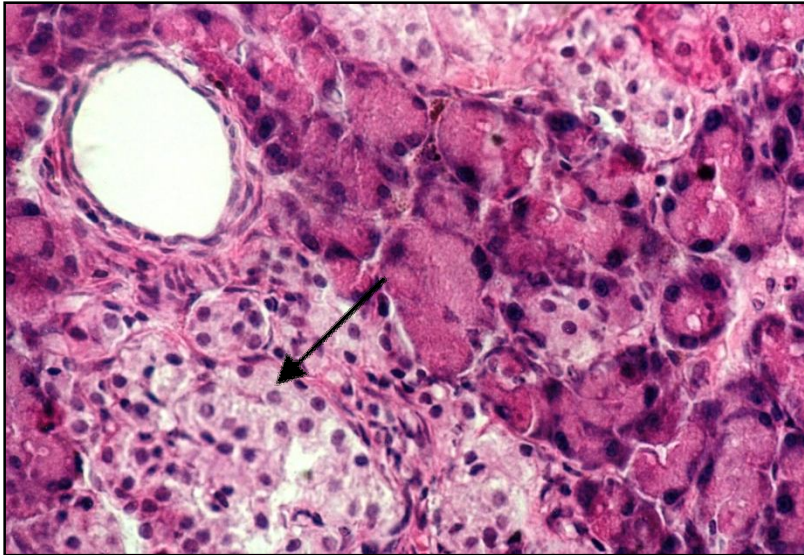


Fig.32. Pancreas of the rat at 8 weeks of hyperglycemia in the setting of the administration of dihydroquercetin.

Large islets (↑) are identified, most of which are located next to the excretory ducts of the gland.

Staining: hematoxylin and eosin.

Magnification: 400X.

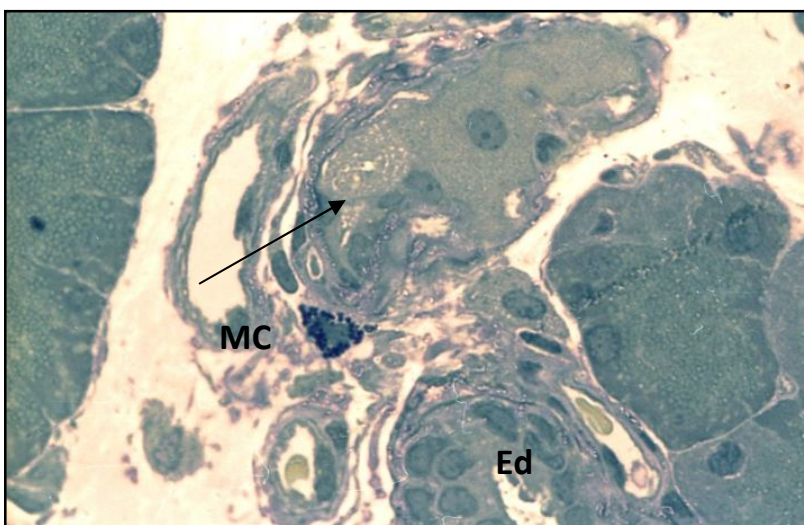


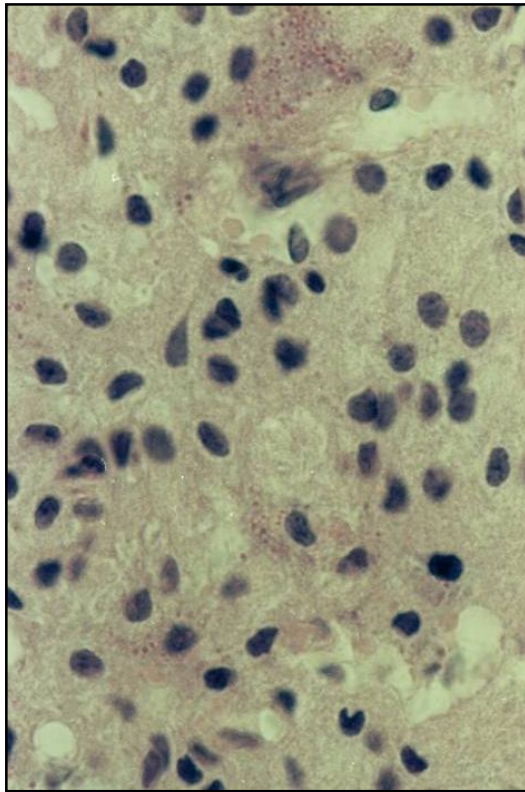
Fig.33. Pancreas of the rat at 8 weeks of hyperglycemia in the setting of the administration of dihydroquercetin.

Near the excretory duct (Ed), between the acini, there is a small islet with a thin capsule, the capillaries of the islet are moderately expanded (↑). In the interlayer of connective tissue there is a mast cell (MC).

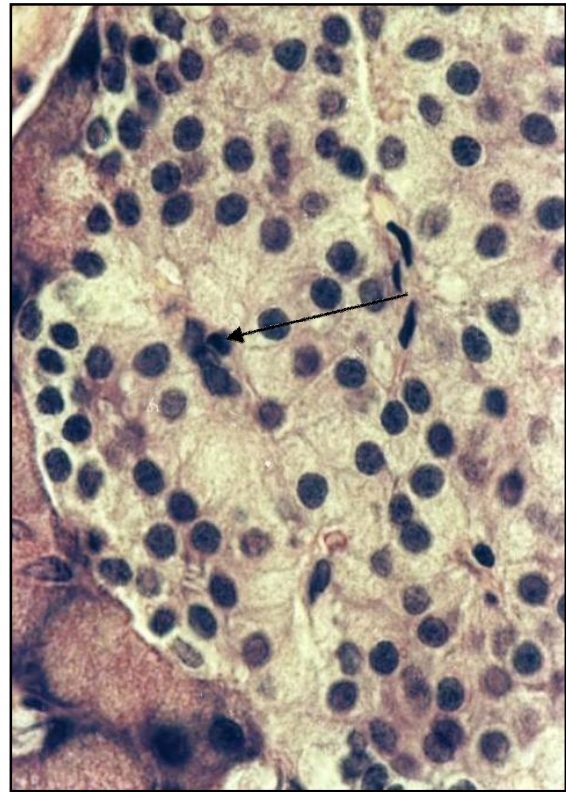
Staining: methylene blue. Magnification: 1000X.

It should be noted that in a number of cells there are signs of vacuolization, organelle dystrophy, a decrease in the number of granules (Fig. 37), but these changes are much less common than in hyperglycemia without the administration of dihydroquercetin. There are few α -cells.

The reaction to glycosaminoglycans in the islet has focal localization and is strengthened in the connective tissue along the blood vessels. The intensity of the reaction to PAS-positive substances in the islets is moderate, tends to decrease, although much higher than in intact animals. The blood capillaries of the islet are enlarged, and singular formed elements are revealed in the lumen. A focal extension of the pericapillary space is observed; usually in this area there is an accumulation of granules in B cells near the cell membrane, also there are signs of secretion.



A



B

Fig. 34 A. Pancreas of the rat at 8 weeks of hyperglycemia.

Fig. 34B. Pancreas of the rat at 8 weeks of hyperglycemia in the setting of the administration of dihydroquercetin.

The large islet contains numerous cells, the interlayers of connective tissue between the cells are thin, and there are a lot of blood vessels. In the subcapsular region, there is a large number of small cells (↑).

Staining: hematoxylin and eosin. Magnification: 1000X.

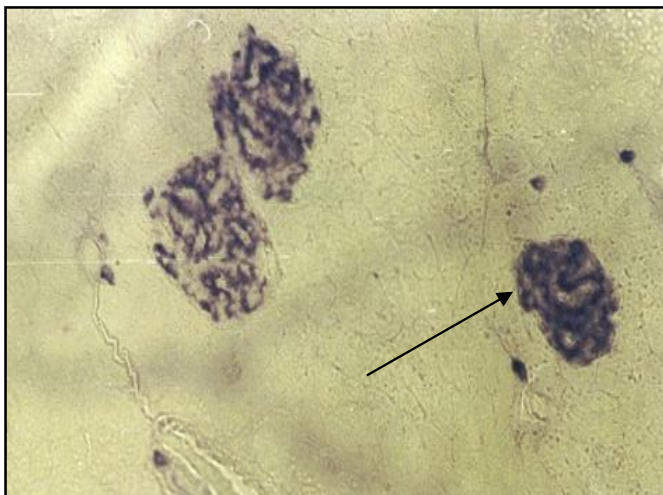


Fig.35. Pancreas of the rat at 8 weeks of hyperglycemia in the setting of the administration of dihydroquercetin.

Between the acini there are small islets containing numerous intensely stained B cells (↑).

Staining:aldehyde - fuchsin by Gabe.

Magnification: 600X.

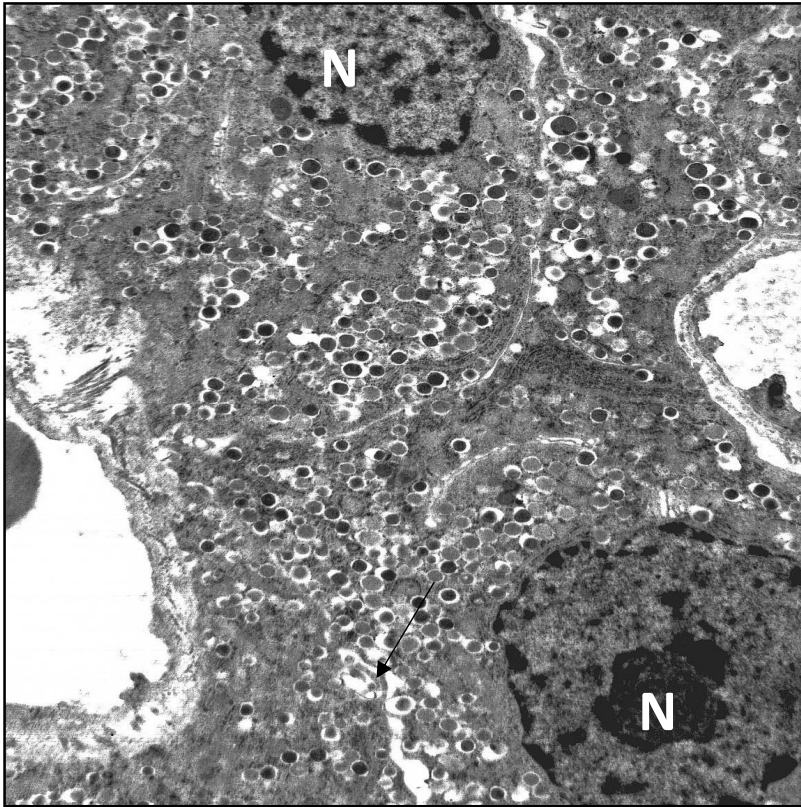


Fig.36. Pancreas of the rat at 8 weeks of hyperglycemia in the setting of the administration of dihydroquercetin.

The nuclei of B cells (N) have uneven contours, the granules in the cytoplasm are located diffusely. There is a secretion of the contents of the granules into the intercellular space (↑). The secretory material of most of them has an average density.

Staining: uranyl acetate, lead citrate.

Magnification: 4000X.

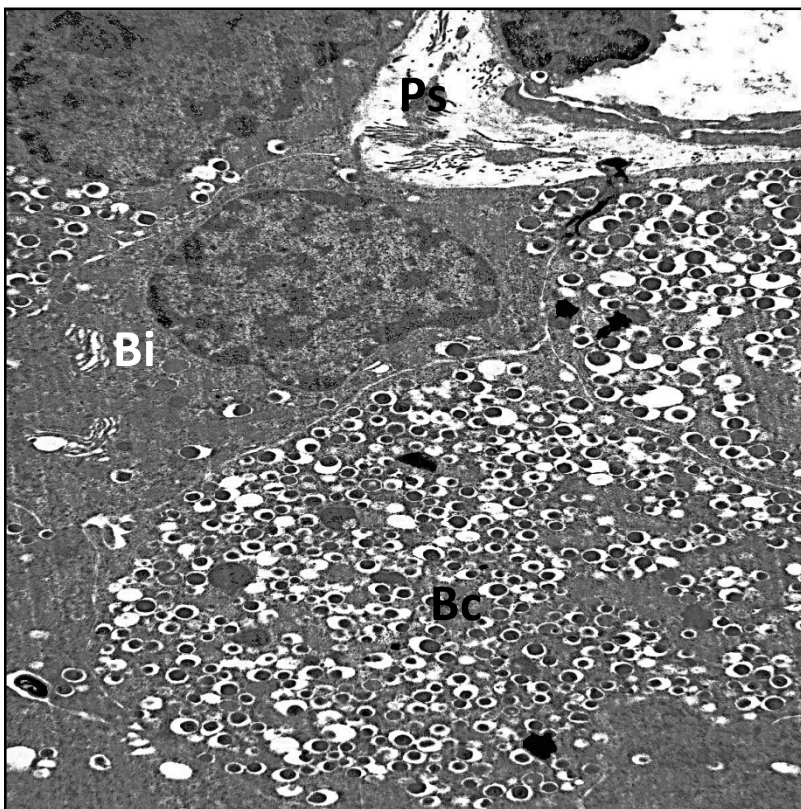


Fig.37. Pancreas of the rat at 8 weeks of hyperglycemia in the setting of the administration of dihydroquercetin.

B cell (Bc) with a large number of granules in the cytoplasm, some of which are located in the membrane space. The pericapillary space (Ps) is widened focally. There are signs of secretion. A nearby located B-islet cell (Bi) contains singular granules.

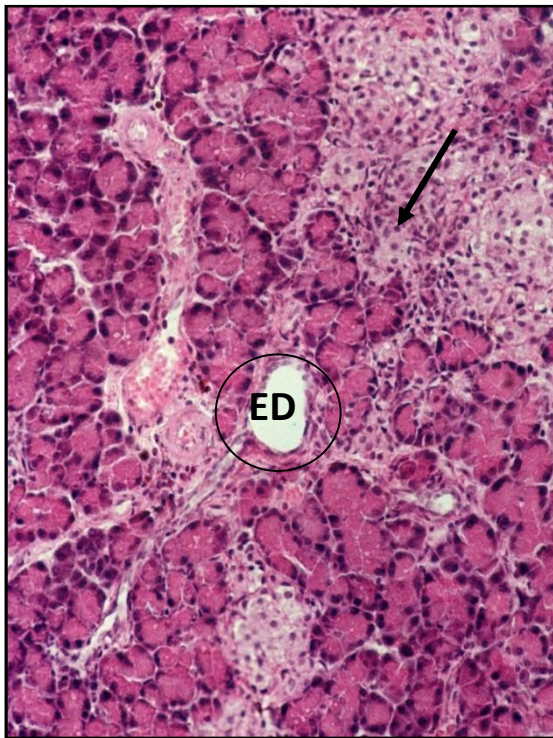
Staining: uranyl acetate, lead citrate.

Magnification: 5000X.

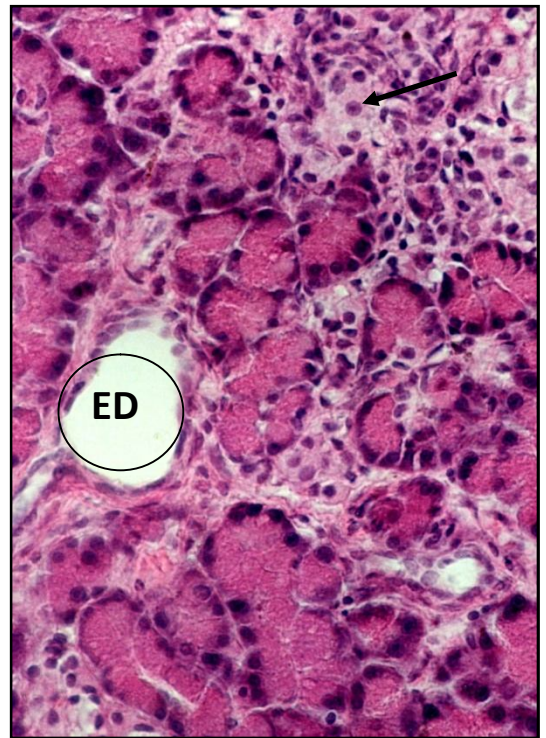
Summary. Thus, with hyperglycemia in the setting of the administration of dihydroquercetin, there is an increase in the number and size of islets, an increase in the number of B cells and the number of granules having an average electron density. The signs of secretion of the contents of the granules are often observed. The content of glycosaminoglycans slightly increases and the intensity of the reaction to PAS-positive substances in the connective tissue and in blood vessel wall decreases.

With hyperglycemia in the setting of dihydroquercetin administration during 16 weeks

In the setting of sustained hyperglycemia, the administration of dihydroquercetin during 16 weeks leads to the appearance of predominantly large islets of various shapes formed around the excretory ducts of the exocrine part (Fig. 38). In the structure of all islets, the number of cells almost doubles: in large cells up to 185.3 ± 7.5 ; in middle ones to 72.3 ± 3.7 ; in small - to 18.7 ± 2.2 (Table 4). The detection of B cells showed that in large islets they are localized more often in the form of foci. In middle islets, B-islet cells are located in the center; most cells contain numerous basophilic granules (Fig. 39). A part of islet cells have a vacuolated cytoplasm (Fig. 40). Between the acini and in the structure of the acini single cells appear; sometimes they are united in small islets with a weakly basophilic cytoplasm, containing small granules (Fig. 41); also there are large cells with a very light cytoplasm, an eccentrically located nucleus and numerous granules accumulated near the cell membrane (Fig. 42). The number of granules in B cells increases to 51.6 ± 4.05 on an area of $10 \mu\text{m}^2$, with hyperglycemia this index is 34.6 ± 2.7 . Along with this, almost equal number of granules of high and medium electron density of osmiophilic contents is contained, while in case of hyperglycemia, granules with high density predominate in control.



A



B

Fig.38 A, B. Pancreas of the rat at 16 weeks of hyperglycemia in the setting of the administration of dihydroquercetin. The islets are mainly located around the excretory ducts (ED), they have an irregular shape (↑). Staining: hematoxylin and eosin. Magnification: A-200X; B-400X.

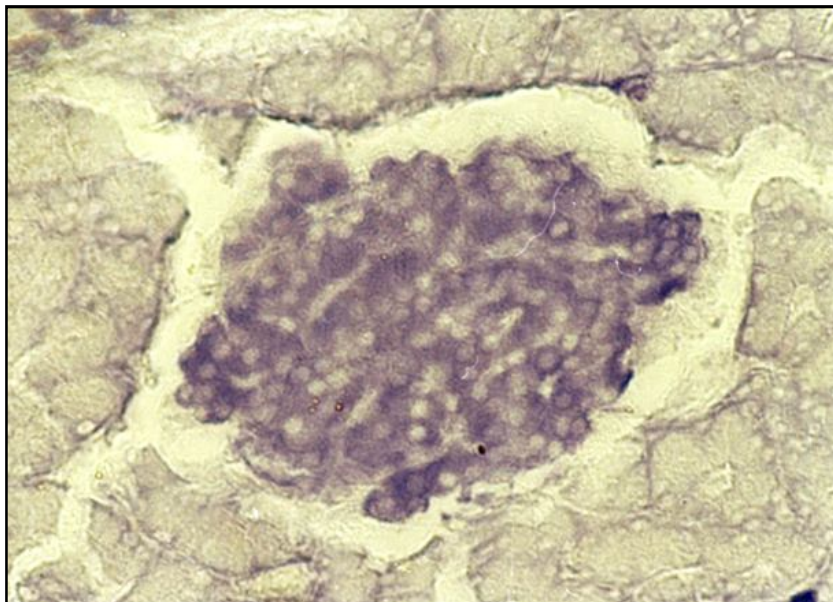


Fig.39A, B. Pancreas of the rat at 16 weeks of hyperglycemia in the setting of the administration of dihydroquercetin.

B cells in large numbers are concentrated in the central part of the islet and have an intense basophilic staining (↑).

Staining: aldehyde - fuchsin by Gabe.

Magnification: 600X.

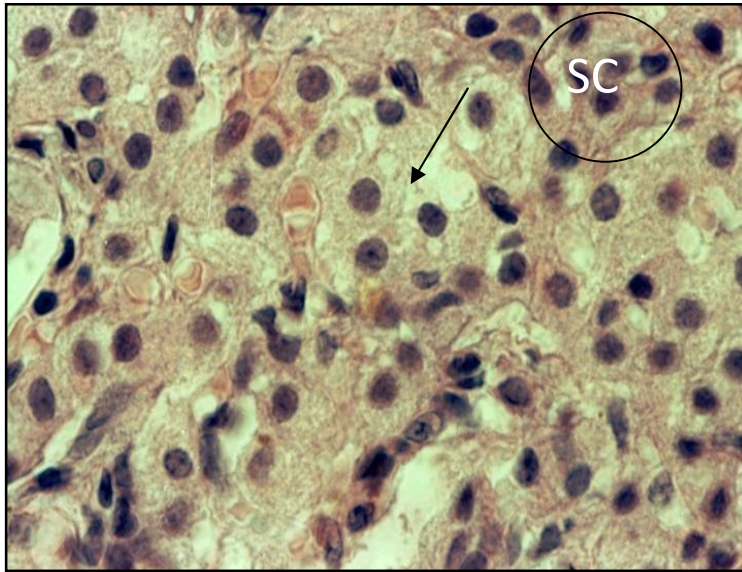


Fig.40A, B. Pancreas of the rat at 16

weeks of hyperglycemia in the setting of the administration of dihydroquercetin.

The large islet contains numerous cells, some of which have a strong vacuolated cytoplasm (↑). In the subcapsular zone, there are small accumulations of small cells (SC)

Staining: hematoxylin and eosin.

Magnification: 1000X.

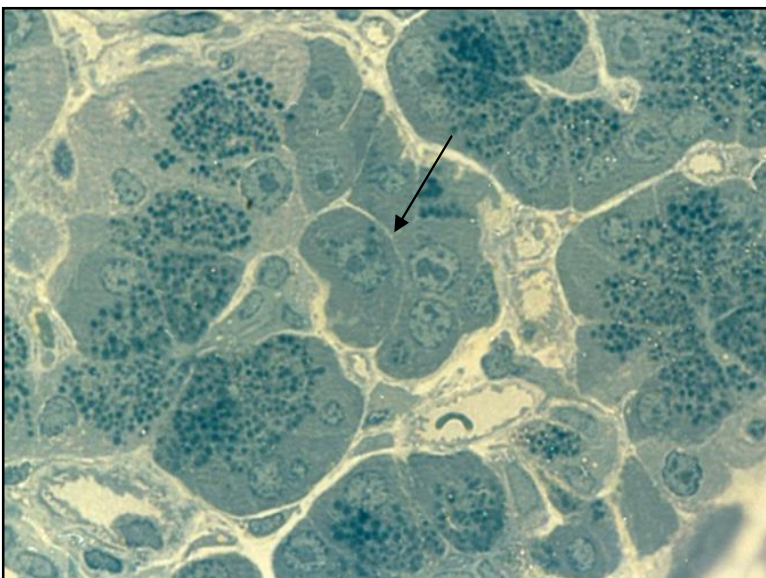


Рис.41. Pancreas of the rat at 16

weeks of hyperglycemia in the setting of the administration of dihydroquercetin.

There are singular cells isolated and collected in the form of small islets with slightly light basophilic cytoplasm in the acinus (↑). Bloody capillaries are located in the interlayers between the cells, they have the usual structure.

Semi-fine section.

Staining: methylene blue.

Magnification: 1000X.

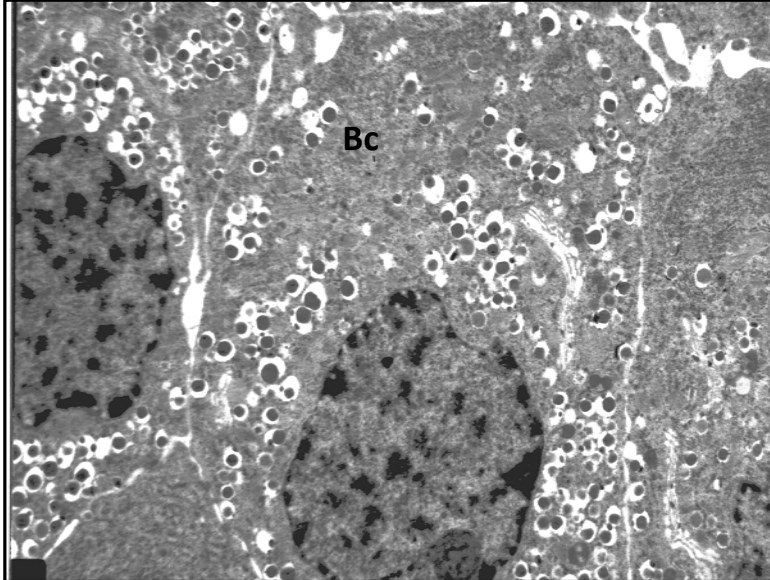


Fig. 42. Pancreas of the rat at 16

weeks of hyperglycemia in the setting of the administration of dihydroquercetin.

The boundaries of B cells (Bc) are clearly visible. There are signs of secretion into the intercellular space, which is focally widened. Specific granules (Gr) are located diffusely, or form large accumulations.

Staining: uranyl acetate, lead citrate. Magnification: 5000X.

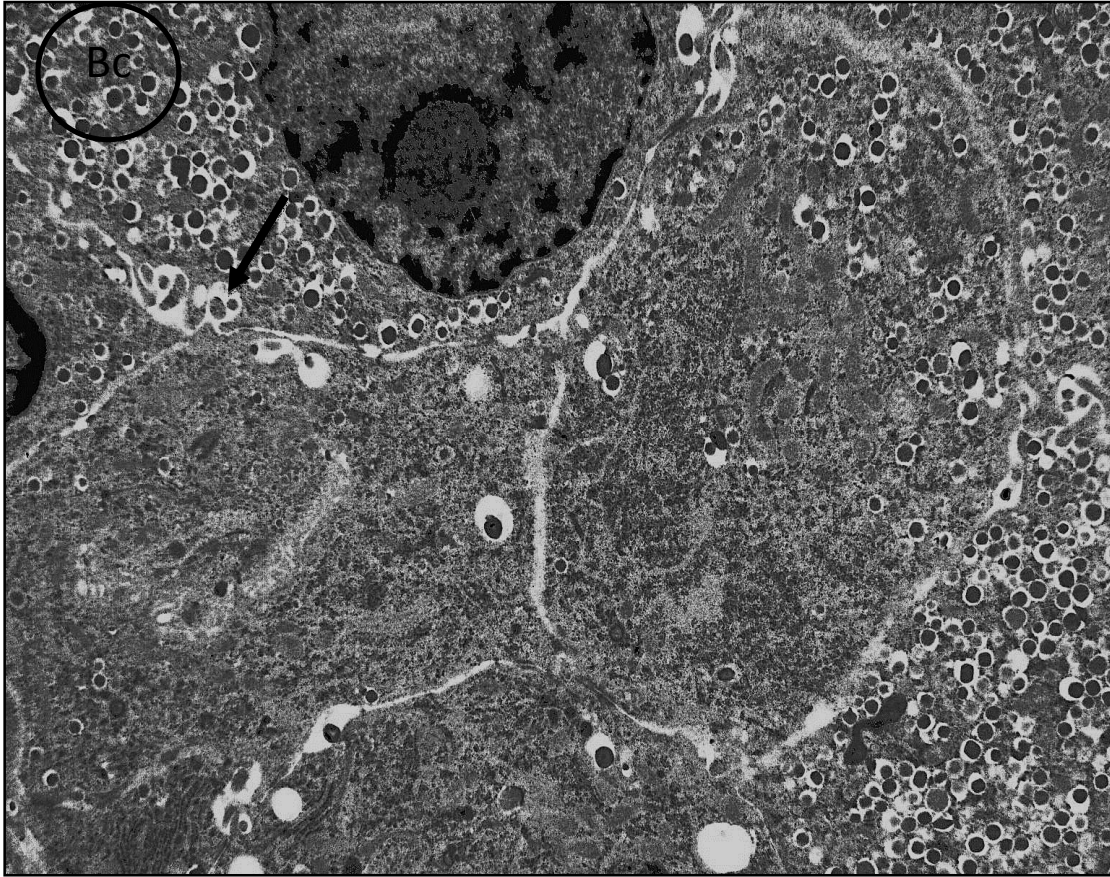


Fig. 43. Pancreas of the rat at 16 weeks of hyperglycemia in the setting of the administration of dihydroquercetin. The boundaries of B cells (Bc) are clearly visible. Most cells contain numerous granules. There are signs of secretion of granules into the intercellular space (↑). In some B-islet cells the number of granules is insignificant, there are dystrophic changes in the cytoplasm.

Staining: uranyl acetate, lead citrate. Magnification: 5000X.

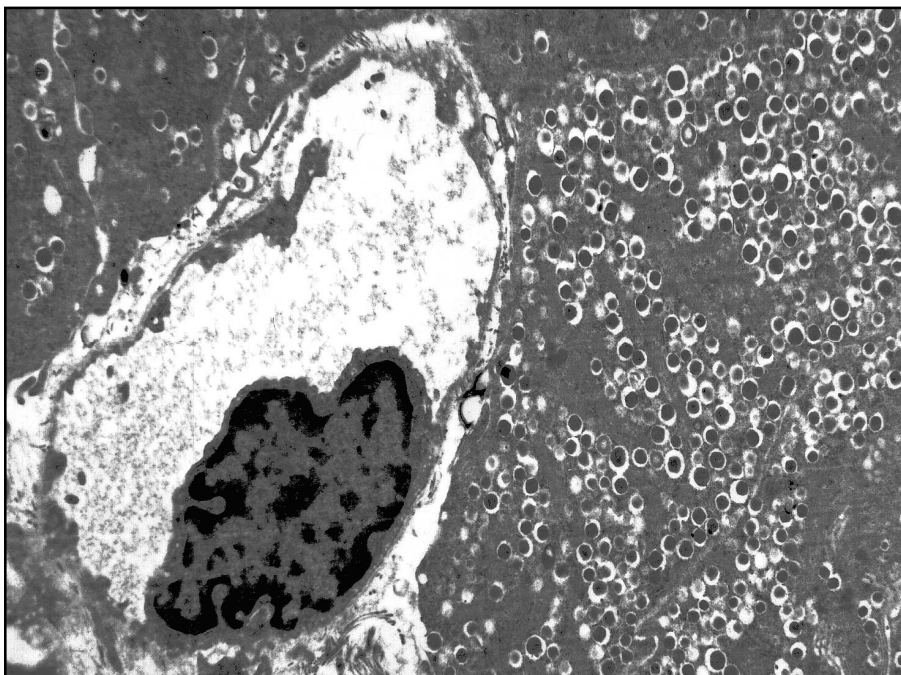


Fig. 44. Pancreas of the rat at 16 weeks of hyperglycemia in the setting of the administration of dihydroquercetin.

weeksofhyperglycemia in the setting of the administration of dihydroquercetin

Numerous granules of B cells (Bc) fill the entire cytoplasm. The nucleus of the endothelial cell is swollen. Nearendothelial space is widened (↑).

Staining: uranyl acetate, lead citrate.

Magnification: 6000X.

B cells contain specific granules in which the average area of the secretory material is $33,900 \pm 475 \text{ nm}^2$ (Table 5). The granules are arranged by groups, sometimes form conglomerates (Fig. 42). The boundaries between the cells are clearly defined, focally expanded; near these areas there is an accumulation of granules and signs of secretion are revealed (Fig. 43). In some cells, there are dystrophic changes, mitochondrial swelling, and the number of granules in them is insignificant. The nuclei of B cells have a round shape, they are hypertrophied, their average area is $26.4 \pm 3.8 \mu\text{m}^2$, and the nucleolus is clearly defined. The cytoplasm of α -cells is light, it contains a few granules. The blood vessels are moderately expanded, have a small diameter with singular formed elements in the lumen; perivascular edema is revealed in the form of small foci. In the blood capillaries, the endothelial cells are hypertrophied, the nearendothelial space is focally widened (Fig. 44). The fascicles of collagen fibers in the interlayers of connective tissue are small. The intensity of the reaction to PAS-positive substances and glycosaminoglycans varies. In the connective tissue and walls of capillaries of islets, the level of reaction to neutral polysaccharides decreases; it has focal localization (Fig. 45). The content of glycosaminoglycans in some capillaries located along the periphery of the islet increases significantly (Fig. 46).

SUMMARY. Under the conditions of this experiment, the number of cells in the islets and the size of the islets themselves are significantly increased. The number of granules in B cells is considerable; along with this half of them are in a more mature state. The signs of dystrophy are noted in a small number of islet cells. The number of acinar-insular cells increases. The changes in the blood vessels, in the

interlayer of connective tissue and the vessels of the microcirculatory bloodstream are substantially fewer than in the control.

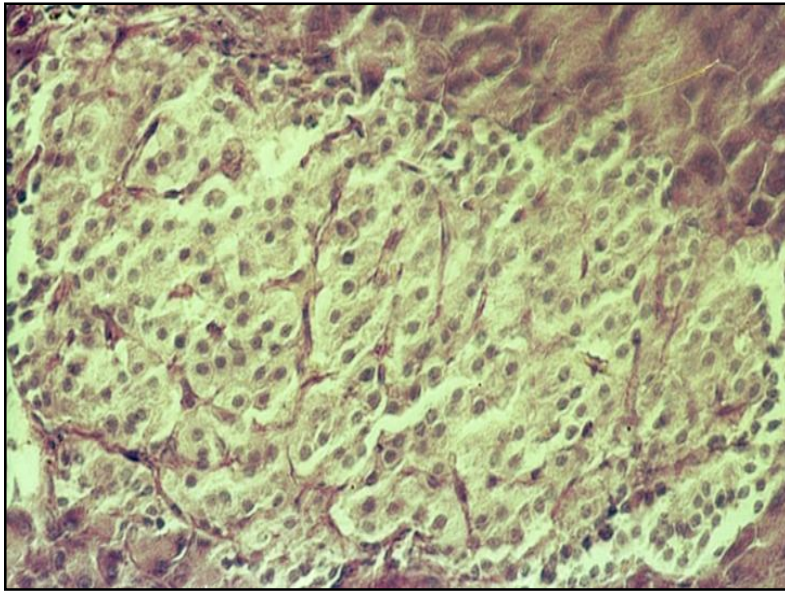


Fig.45. Pancreas of the rat at 16

week of hyperglycemia in the setting of the administration of dihydroquercetin.

The reaction to PAS-positive substances in small interlayers of connective tissue, in the wall of the blood capillaries and in the capsule is expressed moderately (\uparrow).

Staining: PAS-reaction of McManus with hematoxylin staining

Magnification: 200X.

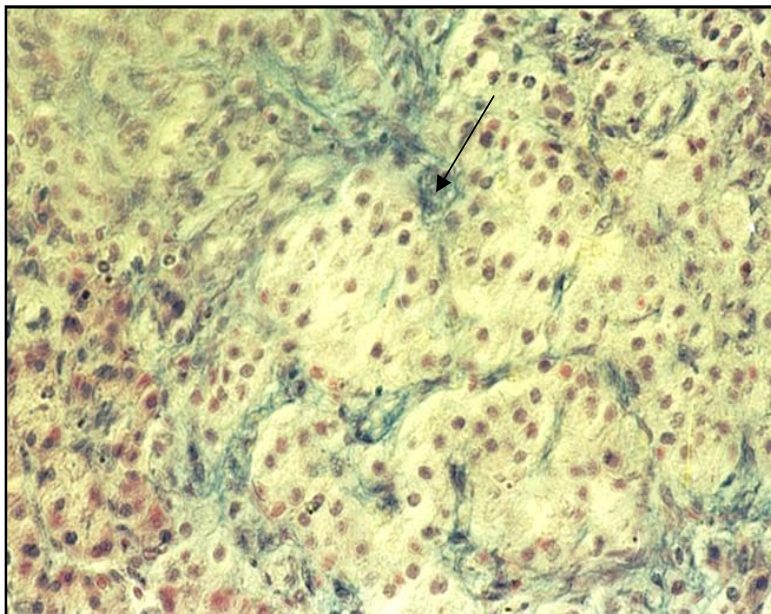


Fig.46. Pancreas of the rat at 16

week of hyperglycemia in the setting of the administration of dihydroquercetin.

The reaction to glycosaminoglycans in interlayers of the connective tissue of the islet and in the capsule is moderately expressed and has a focal nature. A more intense reaction is detected along the blood capillaries (↑) of the islet.

Staining: alcyan blue after Stidman.

Magnification: 400X.

The administration of dihydroquercetin, which has an antioxidant effect, in the setting of hyperglycemia during 16 weeks leads to an increase in the number of islet cells in various islets of the pancreas. The majority of small islets are located near or around the excretory ducts of the exocrine gland. Many researchers indicate that the increase in the number of endocrine cells is not only due to the multiplication of the islet cells, but also with the participation of rapidly dividing cells of the ducts. It is proved that pancreatic ductal epithelial cells differentiate into cells that produce and secrete insulin [Lipsett, M., 2002; Liu, T., 2007].

The critical role in the process of B cell differentiation is played by the high oxygen content which is typical of the natural microenvironment of the islets. The increased oxygen level is a signal for mass maturation of stem cells [Fraker, C. A., 2007]. In the setting of dihydroquercetin effect the number of islet cells significantly decreases, in which dystrophic changes in the nucleus and cytoplasm are revealed in comparison with animals with experimental hyperglycemia. The second positive point that we noted with the administration of dihydroquercetin is that most B cells contain an abundance of granules; along with this the number of granules having an average electron density of the contents increases, as well as the area occupied by the secretory material. Often the accumulation of granules is localized near the cell membrane, there are signs of secretion, i.e. the situation is more typical for intact animals. By all appearances, these changes are associated, on the one hand, with the

antioxidant effect of drug substances on B cells, on the other - the appearance of signs of normalization of connective tissue and blood vessels in the islets.

The changes in the blood capillaries are much lower defined than in the control, more specifically: they are moderately dilated, there are no congestive phenomena in the lumen, there is a slight expansion of the pericapillary spaces and a small focal reaction to PAS-positive substances (Table 6). In other words, the presence of angioprotective activity of the drug substances is evident, which probably reduces the hypoxia of cells and tissues. With the extension of the experiment to 16 weeks, the tendency toward a significant increase in the number of cells in the islets continues, many of which have a basophilic staining, typical of B-islet cells.

In part of the cells of large islets, dystrophic changes are revealed. Numerous secretory granules are preserved in B cells, many of which have an average density of osmiophilic contents. This indicates active granulopoiesis as well as granulolysis of the secretory material in B-islet cells [Gordienko, V. M., 1978; Baranov, V. G., 1983; Ametov, A. S., 2008; Veld, P., 2015]. Quite often numerous granules are localized near the cell membrane, there are signs of secretion. The foregoing allows considering about some compensation for the secretory process that developed in the setting of hyperglycemia. Within this framework, hypersecretion of insulin can promote the reduction of the level and duration of hyperglycemia. In the experiment quite often there are acinar-insular cells located between the acini, in which a small number of B-granules is preserved. According to a number of authors, unregulated compensatory increase in insulin levels in the blood can cause disruption of metabolic processes in insulin-dependent organs [Mazovetskiy, A. G., 1987; Gendeleka, G. F., 1989; Ametov, A. S., 2002; Gordiunina, S. V. 2012; Kaparianos, A., 2008].

In comparison with the previous period of the experiment, we noted minor structural changes on the part of the vessels of different links, i.e. the

angioprotective effect of the drug substances proved to be quite effective in spite of such an extended period of hyperglycemia (16 weeks). This is evidenced by a decrease in the level of reaction to PAS-positive substances in the vessel wall and small foci of perivascular edema, the absence of congestive phenomena in the vessels (Table 6).

In the setting of the administration of dihydroquercetin, structural changes in the connective tissue were less significant. Apparently, the effect of this drug substance is more multifaceted, i.e. it is not only an antioxidant, but also has a capillaroprotective effect; it reduces the aggregation of formed elements, prevents thrombosis, consequently improving blood supply, lowers the level of hypoxia and possibly reduces the effects of intoxication, thus increasing the resistance of cells and tissues to the damaging effect of high blood glucose [Saltykov, B. B., 1984; Sukhanova, L. Y., 1988; Balabolkin, M. I., 2003]. Apparently, this will normalize the delivery of oxygen to the islet cells, which is a signal for the process of regeneration and differentiation of B cells.

Table 6

AUTHENTICITY OF CHANGES OF INTENSITIVENESS OF THE REACTION TO PAS-POSITIVE SUBSTANCES AND GLYCOSAMINOGLYCANS IN ISLETS OF THE PANCREAS OF INTACT AND EXPERIMENTAL ANIMALS (in conventional units)

	Glycosaminoglycans			PAS-positive substances		
	Connective tissue	Blood capillaries	Capsule	Connective tissue	Blood capillaries	Capsule
Hyperglycemia * for 8 weeks (control)	↑	0	0	↑	↑	↑
Hyperglycemia^ for 8 weeks with dihydroquercetin	↑	0	0	↓	↓	↓
Hyperglycemia * for 16 weeks (control)	0	↑	0	↑	↑	↑
Hyperglycemia # for 16 weeks with dihydroquercetin	↑	↑	0	↓	↓	↓

*in comparison with intact animals;

^ in comparison with a control of 8 weeks;

in comparison with a control of 16 weeks;

↑ statistically significant increase; ↓ statistically significant decrease; 0 absence of significant differences.

CHAPTER 4. Histological, histochemical, electron microscopic and morphometric characteristics of rat lung tissue

Morphofunctional characteristics of the lung

The right lung of the rat consists of 4 lobes, the left one - of two. Each major bronchus continues into the caudate lobe of this lung. Before this, the right bronchus makes 3 branches to the middle, cranial and adventive lobes of the lung. Similarly, the left main bronchus gives off a branch that goes to the cranial lobe of this lung. In the hilum of each lung, the main bronchus and its main branches come into close contact with the arteries, which in this area penetrate into the lung and with the veins leaving it. All these tubular formations are surrounded by a dense connective tissue. The whole complex is called the root of the lung. Each of the lobar bronchi is divided into large zonal, and then into intrapulmonary segmental ones [Veibel, E. R., 1970; Techver, Y. T., 1977; Erokhin, V. V., 1987; Chumasov, E. I., 2015].

The lobar and segmental bronchi have a wall consisting of the same membranes as in the main bronchi. The mucous coat includes the epithelium, the basement membrane and lamina propria. Epithelium is multilayered ciliated, contains numerous goblet cells. Its height decreases with the transition from larger bronchi to small ones. Lamina propria is located under the basement membrane and consists of a loose connective tissue containing collagen, elastic and reticular fibers. In all large bronchi, the elastic network is well defined and is located in the form of longitudinal layers under the basement membrane. Among the cellular elements of the lamina propria, there are single fibroblasts, macrophages, mast cells, lymphocytes and plasmocytes. Clusters of lymphatic follicles are revealed.

The specific feature of the mucous coat of the lobar bronchi is the presence of a more developed smooth muscle tissue in comparison with the main bronchi. Smooth muscle cells are grouped in the form of loose parallel beams, separated by a network of elastic fibers. The mucous coat has distinct folds. The submucosa consists of a loose fibrous connective tissue and contains adenomeres of bronchial glands that are located in small groups on both sides of the cartilage. Fibrous-cartilaginous layer is represented by an irregular shape of two or three epiphyseal plates of hyaline cartilage, surrounded by a connective tissue, directly passing into the perichondrium. As the caliber of the bronchus decreases, the size of the cartilaginous plates gradually decreases in it. A dense fibrous layer connecting the cartilaginous plates passes into the adipose tissue. The outer shell is formed by a loose fibrous connective tissue [Chuchalin, A.G., 2007; Fournier, M., 1977].

Segmental and subsegmental bronchi have the structural plan, typical of the bronchial tree, but at the same time a number of features are revealed. The multilayered ciliated epithelium of the mucosa consists of lower cells. In lamina propria, represented by a loose connective tissue, elastic fibers are well developed. The muscle plate is more powerful and consists of muscular fascicles forming almost

closed rings, well-defined longitudinal fascicles [Tekhver, Y. T., 1977; Grappy, Michael, A., 1997]. The mucous coat is folded, which is due to the contraction of muscle layers. The submucosa is represented by a loose connective tissue, with the predominance of collagen and elastic fibers, and in addition to the normal cells, it contains fat cells, the number of which is different. There are small glands in it. Elastic cartilage plates are small; they are located at a considerable distance from each other. The outer adventitial membrane gradually transforms into interlobular connective tissue, where lymphatic follicles are found. The decrease in the caliber of bronchi leads to the appearance of the non-cartilaginous, membranous bronchi located deep in the lung parenchyma; the cartilaginous plates and glands gradually disappear in them. At the same time, the muscle plate becomes relatively more powerful, and therefore the mucosa is aggregated in numerous folds. The wall of these bronchi consists of epithelium, lamina propria and muscle plates, mucous and adventitial membranes. The epithelium is cylindrical, ciliated, more often two-rowed and it is lower than in the previous bronchi. Under the basal layer of the epithelium there is a loose connective tissue and then the smooth muscle elements, between which there are quite numerous elastic fibers [Erokhin, V. V., 1987; Motavkin, P. A., 1998; Tseluyko, S. S., 2000].

Terminal bronchiole is the terminal element of the bronchial tree. The mucous coat of the bronchioles is lined with a single-layered cubic, ciliated epithelium. In the lamina propria, longitudinal elastic fibers are located, between which there are singular fascicles of smooth muscle cells. In small bronchi and bronchioles there are loose, quite extensive accumulations of lymphoid elements, which are especially dense on the border with the alveolar parenchyma [Veibel, E. R., 1970; Erokhin, V. V., 1987; Dedovl. I. et al, 2003; DeDiosEscolar, J., 1994]. The walls of the respiratory bronchioles and alveolar ducts are much thicker than the interalveolar septa; under their epithelium there is a developed basis of elastic and reticular fibers, as well as

smooth myocytes, between which not only capillaries, but also pre- and postarterioles pass.

In different representatives of mammals (mouse, rat), including humans, the researchers did not observe any significant differences in the fine structure of the alveoli of the lung [Polikar, A., 1972; Tekhver, Y. T., 1977; Motavkin, P.A., 1998]. The alveoli are separated by interalveolar septa, in which the blood capillaries pass. Each septum generally simultaneously serves as a wall for two alveoli, on which cells of the alveolar lining are located. The internal surface of the alveoli is covered with respiratory alveolocytes (type 1) and secretory alveolocytes (type 2). Alveolocytes of type 1 have an irregular flattened prolate form. A thicker nucleated part, where most of the organelles are located, and a thin anucleate one are defined in them. On the surface of the cell which faces the alveolar cavity, there are short cytoplasmic outgrowths, and in the cytoplasm there are small mitochondria and pinocytotic vesicles, a limited number of ribosomes and polysomes; microfilaments are dispersed throughout the cytoplasm. The cell has low metabolic activity, it also has a multitude of micropinocytotic vesicles and vesicles [Erokhin, V. V., 1987; Grappy, M.A., 1997]. Alveolocytes of type 2 are cubic in shape, they are considered to be the largest and in addition to the usual organelles they contain osmiophilic lamellated corpuscles. These cells are proliferating; sometimes 2-3 cells are located side by side. Alveolocytes of the 2 type can proliferate and generate either of its kind cells or alveolocytes of type 1. In the wall of the alveoli and on their surface there are macrophages, in the cytoplasm of which there are many lipid droplets and lysosomes. "Brush" cells, or alveolocyte type III, have absorption, contractile, secretory and chemoreceptor functions. Their distinctive feature is the presence of cylindrical microvilli (in the form of a brush) consisting of filaments on the apical surface [Tekher, Y. T., 1977; Tseluyko, S. S., 2000; McDonald, R. J., 1991].

Alveolocytes are located on the basement membrane; from the outside of it there is a septal stroma, in which there is a dense narrow-looped network of

capillaries, elastic and thin collagen fibers and various cells. In some animals with thicker interalveolar septa, for example in rats, the capillaries may be adjacent to one alveolus. Almost all the alveolar interstitial connective tissue is on one side of the capillary, which contains collagen and elastic fibers that create the structural framework of the alveolar walls; it promotes the exchange of fluid in the microcirculatory system. The alveolar barrier is formed by three tissue components: 1) the endothelium lining the blood capillaries of the alveoli; 2) the epithelium lining the alveoli from the side of the airspace; 3) a layer of the basic substance with fibrous structures and connective tissue cells (interstitium) located between the basement membrane of the endothelium and the alveolar epithelium [Polikar, A., 1972; Motavkin, P. A., 1998; Chuchalin A.G., 2007].

The lungs receive blood from the pulmonary and systemic circulation. The pulmonary circulation makes gas exchange. Venous blood enters the lungs through the pulmonary artery, and the arterial blood flows through the pulmonary vein. Bronchial arteries are arteries of the muscular type with a well-developed internal and external elastic lamina. These arteries can be detected up to the level of interlobular bronchi. On the periphery of the bronchial tree, they branch into arterioles, precapillaries, capillaries and they anastomose with vessels of the pulmonary circulation. Subsegmental arteries are divided into arteries of the level of interlobular and intralobular bronchi, terminal and respiratory bronchioles, which refer to arteries of the muscular type [Chuchalin, A.G., 2007, Weibel, E.R., 1984].

Blood capillaries are located in the thickness of the alveolar wall, i.e. they are separated from the alveolar air by means of alveocytes. Unlike endothelium of the bronchial capillaries, the endothelium of the alveolar capillaries forms a continuous fenestrated lining of the vessels. The thickness of the endotheliocyte in the core part is $3 \pm 5 \mu\text{m}$. The extranuclear portion of the cytoplasm of endotheliocytes has a thickness of $200 \pm 500 \text{ nm}$, but can become thinner to 100 nm . The nuclei of endothelial cells are oval or round, the nuclear membrane is moderately plicated. In

the cytoplasm of endotheliocytes, there are rare lysosomes, lipid droplets, Weibel-Palade bodies. Endothelial cells of the alveolar capillaries are on the basement membrane - an electronically dense formation of 150 nm thickness, along with this there are areas with protrusions of basement membranes, type II alveocytes and endotheliocytes in the air-alveolar barrier zone [Tekhver, J. T., 1977; DeDiosEscolar, J., 1994].

The basal layer performs not only a supporting function for endotheliocytes, but also determines the differentiation and stage of the formation of the cell population. If the layer is damaged, the process of restoring the endothelial lining is broken. The basal layer performs the leukocyte migration through the cell wall. The capillaries of the pulmonary artery system anastomose with capillaries of the bronchial artery system and form a single capillary network. After the fusion, the capillaries pass into postcapillary venules with a diameter of 40-50 μm , then into the gathering venules and after that into the veins. The main function of the alveolar blood capillaries is to participate in gas exchange between the alveolar air and the blood of the capillaries. In addition, the endothelium of the capillaries carries out synthesis, secretion, absorption and deterioration of a large number of biologically important compounds [Strukov, A. I., 1990; Chuchalin, A.G., 2007; Riley, D. J., 1987].

Changes in the lung with hyperglycemia and diabetes mellitus

The metabolic disorders that occur in DM lead to disruption of the functions of various parts of the respiratory system. In clinical studies it was demonstrated that with DM lung lesions may be a background for the development of secondary changes of an infectious nature, the emerging pneumoniae in this case proceed longer and are slowly treated. More often, patients with diabetes mellitus suffer from chronic nonspecific lung diseases [Lysenko, L. V., 1990; Shishkova, V.N. 2015; Kaparianos, A., 2008;].

One of the characteristics of diabetes mellitus is an increase in the arteriovenous difference due to a decrease in the oxygen content in the venous blood and an increase of its utilization by tissues, which testifies to tissue hypoxia, which to some extent is compensated by a change in lung function. With DM hyperventilation is detected, but the oxygen utilization coefficient decreases with increasing severity of the disease, which indicates the debilitation of compensation abilities of lung for gas exchange [Kodolova, I. M., 1982; Shcherbak, A. V., 1986; Balabolkin, M. I., 1994; Shoikhet, Y.N. and others, 2008]. In the experimental works of a number of authors it has been established that in diabetes mellitus, as a result of the destruction of connective tissue synthesis in the lungs, changes in the structure and size of the alveoli are observed. At the same time, the volume of DNA decreases, the amount of collagen and elastin increases, the air-filled space of the lungs decreases, the number of alveoli increases, the total amount of phospholipids and phosphatidylcholine decreases. In the lumen of the alveoli, an accumulation of alveolar macrophages, containing PAS-positive material, hemosiderin, and lipoids was observed. The number of macrophages in the lumen of the alveoli depends on the blood sugar level and the severity of vascular changes, i.e., the intensity of plasmorrhagia. With diabetes in conditions of plasmorrhagia and induction, macrophages play an active role in the resorption and removal of byproducts coming from the vascular bed into the wall and the lumen of the alveoli - neutral fat, cholesterol and its esters, polysaccharides [Nathan, C. F., 1982; McDonald, R. J., 1991; Toso, C., 2008]. Resorbing the byproducts, the alveolar macrophages to some extent purify the lung tissue, but as the sclerosis and hyalinosis increase in the vessels of the microcirculatory bloodstream and the alveolar septa due to repeated processes of insudation, the lung tissue is loaded with byproducts, alveolar macrophage deficiency develops, their phagocytic activity decreases.

One of the ways to study the differentiation of macrophages is the identification of lectin receptors on their surface. Lectins are represented by protein

multivalent ligands, which specifically and reversibly bind carbohydrates without causing their chemical transformation. It is based on the formation of molecular complexes of carbohydrates with protein, while the specificity of the interaction is determined by the structure of the active center of the lectin. Specific for macrophages in defining the level of differentiation is the lectin of *Helix pomatia* (HPL). It has been established that for a cell that is capable of morphogenetic transformations, a higher content of carbohydrate residues on the surface is typical [Lupa, H., 1980; Tseluyko, S. S., 2000; Imat, Y., 1995; Imberty, A., 2004; Tielker, D., 2005].

With DM, the dystrophic processes extend to the pulmonary interstitium, where collagen fibers are disarranged; stratification and partial lysis of the elastic fibers are observed. Along with this, the growth of fibroblastic processes promotes the formation of interstitial fibrosis with the development of an incapable fibrous connective tissue. The periarteriolar and peribronchial fibrosis of a diffuse and focal character are microscopically revealed. With electron microscopy, changes are more often found in type 2 alveocytes, their swelling is noted. This is due to a moderate expansion of the tubules of the rough endoplasmic reticulum, which is associated with inhibition of secretion and synthesis in these cells. The consequence of this is a decrease in the oxidation of glucose and a decrease in the rate of its incorporation into neutral lipids and phospholipids. Apparently, insulin plays an important role in the normal function of the rough endoplasmic reticulum of type 2 alveocytes [Lysenko, L. V., 1990; Lysenko, L. V., 1990; Demidova, I. Y., 2000; Nazhmutdinova, D. K., 2000].

Thus, non-specific morphological features of DM are: combined edema (intra-alveolar, interstitial), sclerotic changes in artery walls, foci of interstitial fibrosis, emphysema, accumulation of alveolar macrophages. Specific morphological features include a symptom complex, which involves: pericapillary nodules in interalveolar

septa, granulomatous perivascular formations with cellular inclusions, thickening of the basement membrane of capillaries and small vessels.

The morphological structure of the intralobar bronchi and lung parenchyma of rats practically does not differ from the plan for the organization of these parts characteristic of man and many mammals. Based on the purpose of our study, the features of the structure of subsegmental and intralobar bronchi, as well as the walls of the alveoli were studied. Special attention was given to the structural changes in the large vessels and vessels of the microcirculatory bloodstream. For the objectification of the results of the experiment and taking into account the presence of numerous lymphoid formations in the lungs, the calculation of various classes of cells in their structure was carried out. A loose connective tissue of the bronchi, septal wall and alveoli was described; an evaluation of the intensity of the reaction to PAS-positive substances and glycosaminoglycans was carried out. Various experimental effects did not lead to a change in the general structural plan of a number of structures of the bronchial tree and the respiratory part of the lungs of rats.

Morphofunctional characteristics of the lung in intact rats

Subsegmental bronchus has a typical plan of the structure and from the inside it is limited by the mucous coat lined with multilayered ciliated epithelium. In the lamina propria of mucous membrane there are vessels of the microcirculatory bloodstream and numerous elastic fibers having a longitudinal direction. The mucous membrane is collected in folds due to a well-developed muscle plate. The submucosa is poorly developed. The outer shell passes into the interlobular connective tissue with numerous blood vessels and lymphoid formations. In membranous bronchi, the lamina propria is thin, collected in folds. The muscle plate

of the mucosa is well developed. In the adventitious membrane, the lymphoid cells are located diffusely. The connective tissue of the outer shell is connected to the elastic tissue of the interalveolar septa. In rats, septa between the alveoli are fairly thick and contain numerous blood capillaries (Fig.47). Elastic fibers have approximately the same thickness and are represented by separate fragments. Alveolar macrophages are revealed in the structure of interalveolar septa. Inside the alveolus is lined with type 1 alveolocytes located on the basement membrane, a blood capillary is attached to it from the outside. The largest size of the alveolocyte is located near the nucleus; the thin, elongated, anucleate part contains pinocytotic vesicles (Fig. 48). Alveolocytes of type 2 are the largest and contain a significant number of lamellated osmiophilic bodies. The most intensive reaction to PAS-positive substances (Fig. 49) and glycosaminoglycans is detected in the wall of bronchial vessels and somewhat lower in the interalveolar septum. Calculation of the cells of the peripheral zone of lymphoepithelial formation testified that the largest number belongs to small lymphocytes $49.8 \pm 2.19\%$ (Table 7). The reaction to the lectin of *Helix pomatia* is mainly detected in the form of small accumulations of granules in cells that are located in the lumen of the alveoli, probably in macrophages (Fig. 50).

SUMMARY. Thus, the intralobar bronchi have a typical structure plan. The interalveolar septa are quite wide. The content of glycosaminoglycans and the intensity of the reaction to PAS-positive substances are expressed moderately in the blood vessels and vessels of the microcirculatory bloodstream. In the peribronchial connective tissues being a part of lymphoepithelial formation small lymphocytes dominate. A positive reaction to the lectin of *Helix pomatia* is revealed in the cell membrane, apparently macrophages.

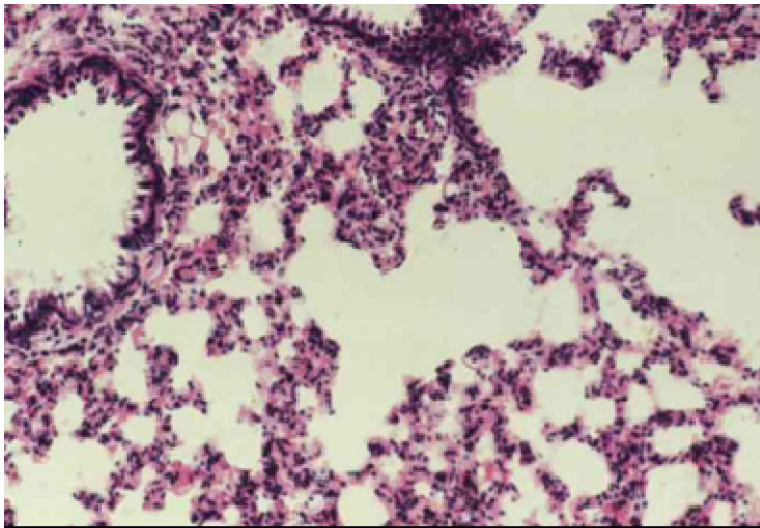


Fig. 47. Respiratory portion of the lung of an intact rat.

The interalveolar septa are quite thick, and numerous blood capillaries are revealed in them.

Staining: hematoxylin and eosin. Magnification: 280X.

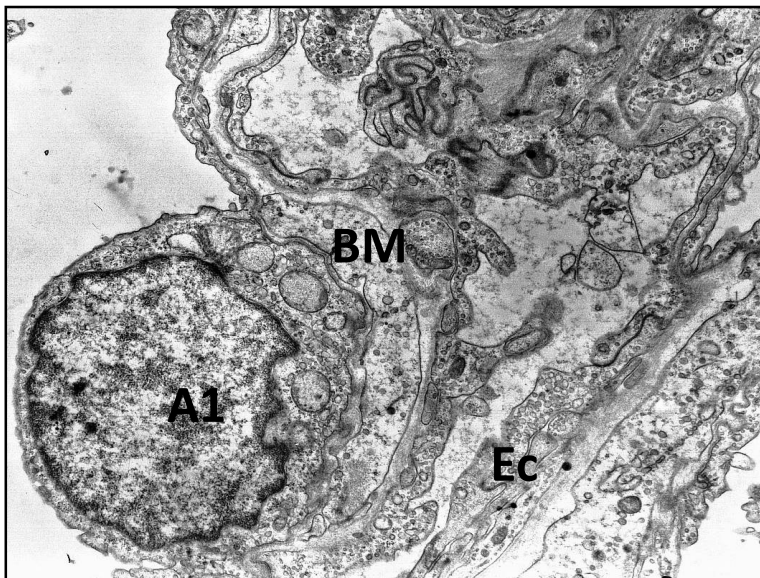


Fig. 48. Respiratory portion of the lung of an intact rat.

In the lumen of the alveoli, the nucleated portion of the alveolocyte of type 1 bulge (A1), located on the basement membrane (BM). On the opposite side, the endotheliocyte of the capillary (Ec) adjoins it.

Embedding: araldite – epon

Staining: uranyl acetate, lead citrate.

Magnification: 20000X.

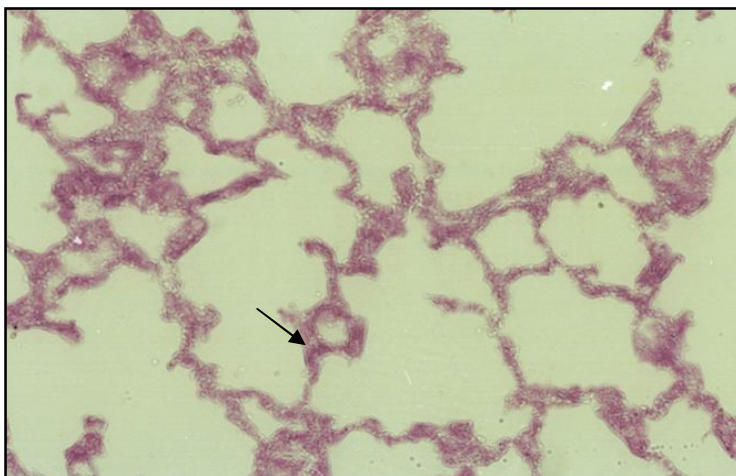


Fig. 49. Respiratory portion of the lung of an intact rat.

The greatest number of PAS - positive granules is detected in the wall of blood vessels (↑). In the alveoli, the reaction is moderate.

Staining: PAS-reaction of McManus.

Magnification: 280X.

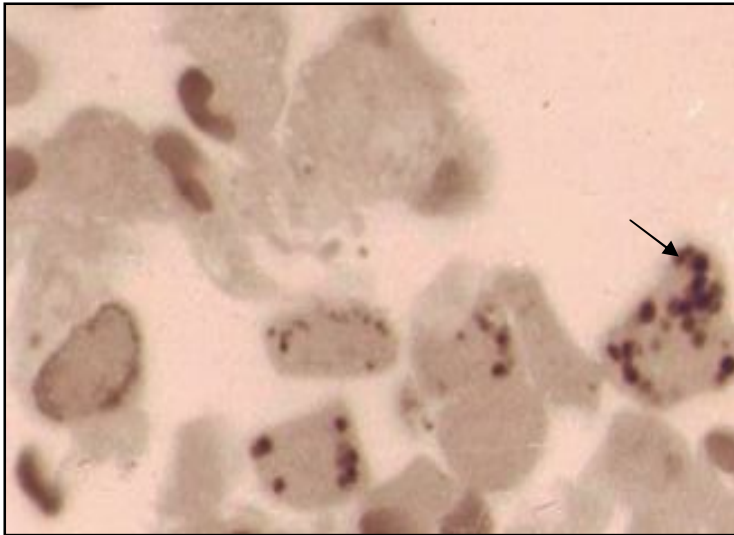


Fig. 50. Respiratory portion of the lung of an intact rat.

A small number of granules of reaction products are detected on the cell surface in the form of accumulations (↑) in the cytoplasm. Semi-fine section.

The reaction to the lectin of *Helix pomatia* in addition to methylene blue staining.

Magnification: 420X.

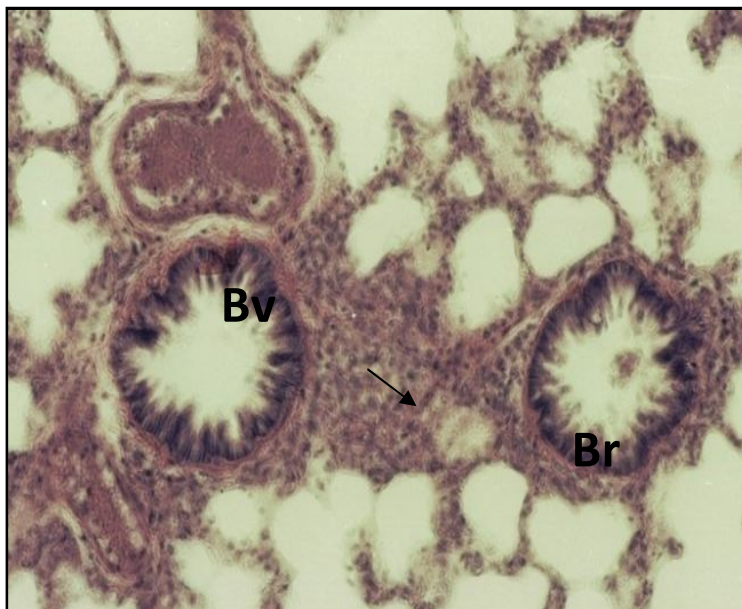


Fig. 51. The lung of rat with hyperglycemia for 8 weeks.

The structure of the bronchi (Br) is not changed, marked folding is noted, the muscle plate of the mucosa is well revealed. Peribronchial connective tissue is infiltrated by numerous lymphocytes (↑). In the lumen of the blood vessels (Bv) there is stasis of the formed elements; the signs of perivascular edema are defined.

Staining: hematoxylin and eosin.

Magnification: 280X.

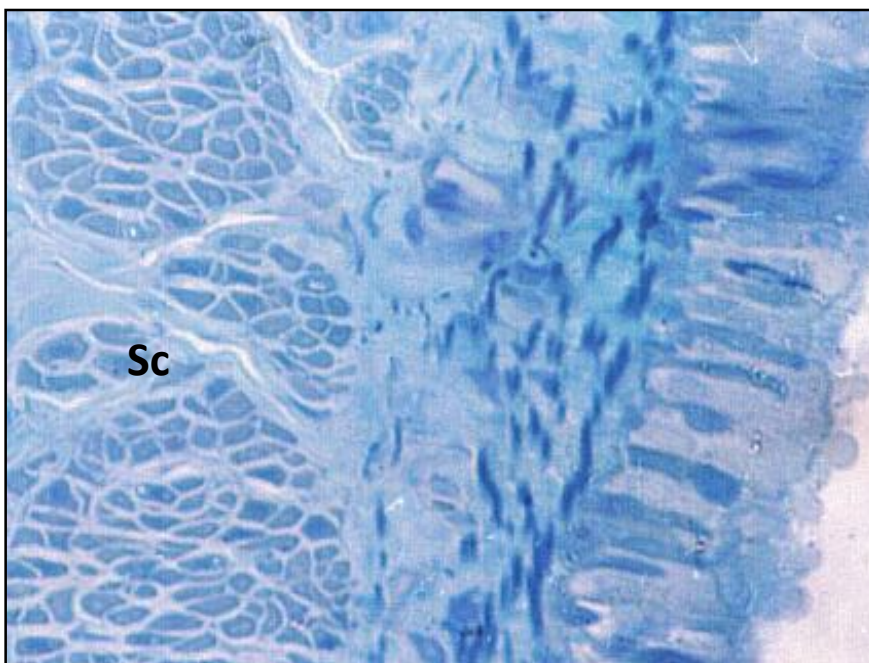


Fig. 52. The wall of intralobular rat bronchus with hyperglycemia for 8 weeks.

The distance between the fascicles of smooth muscle cells (Sc) is increased in the focal point.

Semi-fine section

Staining: methylene blue.

Morphofunctional characteristic of the lung of rats in experiment with hyperglycemia during 8 weeks

In the setting of hyperglycemia, the general plan of the bronchial wall structure is preserved, but there is an increase in the folding of the mucosa (Fig. 51). Focal hypertrophy of myocytes and an increase in the distance between the cells are revealed (Fig. 52). The peribronchial connective tissue is infiltrated by numerous lymphocytes and macrophages, and also contains large lipid droplets. Elastic fibers in the bronchial wall are fragmented, thickened, and arranged in groups. A similar tendency is noted in interalveolar septa and only in some alveoli its usual structure remains unchanged (Fig. 53). The perivascular edema of different degree is often defined, especially around venous vessels, in which the stasis of blood cells is noted (Fig. 51). Changes in the respiratory portion are characterized by the appearance of atelectasis zones and emphysema portions, extensive infiltration and blood filling of capillaries (Fig. 54). The increase in the thickness of the wall of the alveoli is especially clearly visible on the electron diffraction patterns. In septal walls there are numerous accumulations of fibers (collagen and elastic), zones of mucoid swelling (Fig. 55). In the lumen of the alveoli there are large macrophages with a great number of vacuoles (Fig. 56). The electron diffraction patterns show that the contents of the vacuoles and their size vary considerably (Fig. 57). The reaction to the lectin of *Helix pomatia* revealed the presence of cell groups in the alveolar wall, probably macrophages, most of which contain a significant number of granules of reaction product with various sizes (Fig. 58). Most alveolocytes of type 1 show signs of hypertrophy. In alveolocytes of the 2nd type, the tubules of the endoplasmic reticulum are enlarged, the mitochondria are swollen, the number of osmiophilic

bodies is insignificant (Fig. 59). In the structure of the alveoli, the basement membrane thickens in some areas, its loosening is observed, and numerous small vacuoles appear in alveolocytes of type 1 and endotheliocytes (Fig. 60). There is a focal increase in the response to glycosaminoglycans in peribronchial connective tissue (Fig. 61), in the wall of large vessels and in interalveolar septa. The reaction to PAS-positive substances that have diffuse or focal localization in the blood vessels increases. Its intensity in the basement membranes of the capillaries of the alveoli, as well as in the inner and middle layers of the bronchial vessels, significantly increases; around the latter there is a perivascular edema (Fig. 62). In the peripheral zone of the lymphoepithelial formation of the bronchi, the infiltration zones increase, the number of cells increases in them (Fig. 63). Moreover, on the area of $10000 \mu\text{m}^2$, the number of small lymphocytes significantly increases to $68.7 \pm 4.01\%$; lymphoblasts to $6.7 \pm 0.32\%$; macrophages to $8.3 \pm 1.72\%$ (Table 7).

Table 7

THE NUMBER OF CELLULAR ELEMENTS IN THE PERIPHERAL ZONE OF LYMPHOEPITHELIAL FORMATIONS OF SUBSEGMENTAL AND INTRALOBULAR BRONCHI IN INTACT AND EXPERIMENTAL RATS (on an area of $10.000 \mu\text{m}^2$)

Indices	Lymphoblasts	Average lymphocytes	Small lymphocytes	Macrophages	Plasmocytes	Mast cells
Groups of animals						
Intact	$3,04 \pm 0,2$	$18,7 \pm 2,22$	$49,8 \pm 2,19$	$0,5 \pm 0,12$	0	$0,3 \pm 0,17$
Hyperglycemia 8 weeks	$6,7 \pm 0,32^*$	$23,2 \pm 2,8$	$68,7 \pm 4,01^*$	$8,3 \pm 0,72^*$	$3,1 \pm 0,48$	$1,4 \pm 0,3^*$
Hyperglycemia 16 weeks	$5,3 \pm 0,54^*$	$27,8 \pm 1,57^*$	$85,6 \pm 3,61^*$	$12,3 \pm 2,07^*$	$3,7 \pm 0,18$	$5,3 \pm 0,74^*$

* $p < 0,05$ in comparison with intact animals

Summary. With hyperglycemia, in the setting of the preservation of the general plan of the structure, numerous zones of atelectasis and emphysematous areas appear in the lungs. The walls of the alveoli thicken; numerous formed elements are present in their blood capillaries. Pericapillary and perivascular edema is revealed. Extensive infiltration zones are found in the peribronchial connective tissue and in the walls of the alveoli. The number of macrophages and alveolocytes

is increased. The zones of intensive reaction to PAS-positive substances in the vessel wall and focal increase of glycosaminoglycans in connective tissue are revealed.

Fig. 53. Respiratory portion of the lung in hyperglycemia for 8 weeks.

In the interalveolar septum, elastic fibers (↑) are thickened and arranged by groups. Perivascular edema (PE) is expressed.

PE

Staining: Weigert's resorcin-fuchsin.

Magnification: 260X.

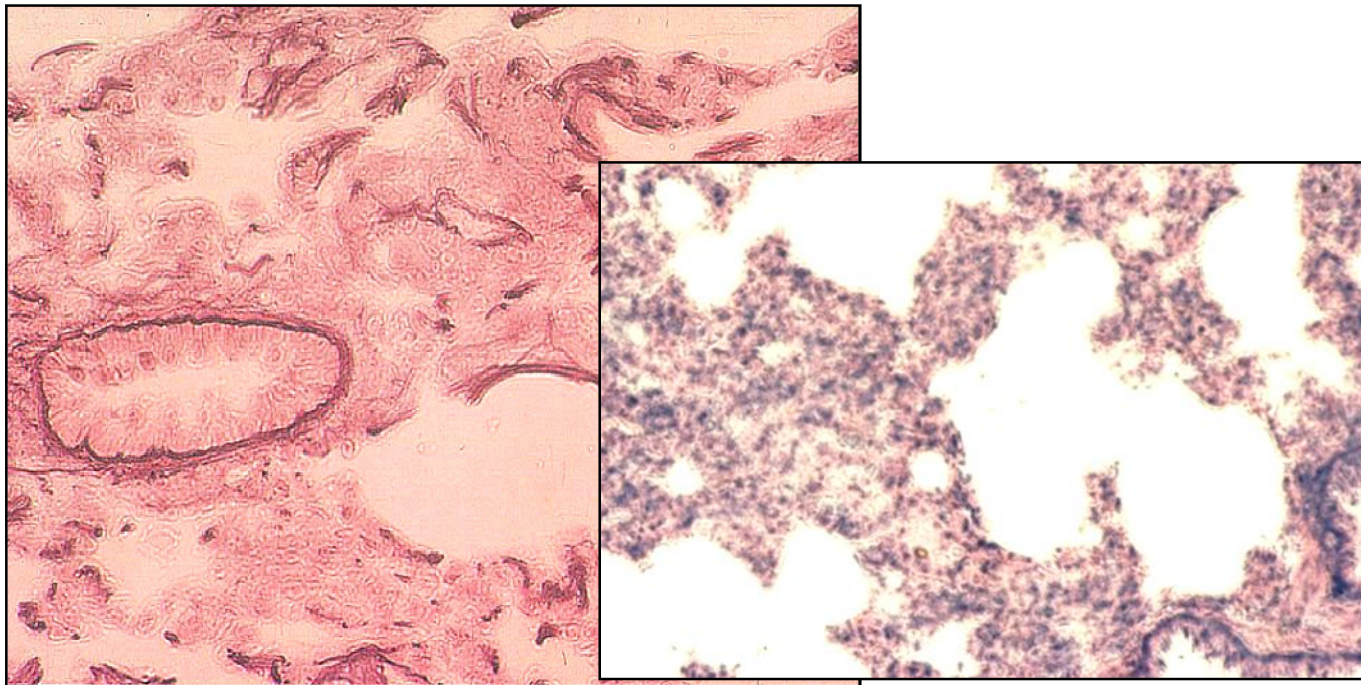
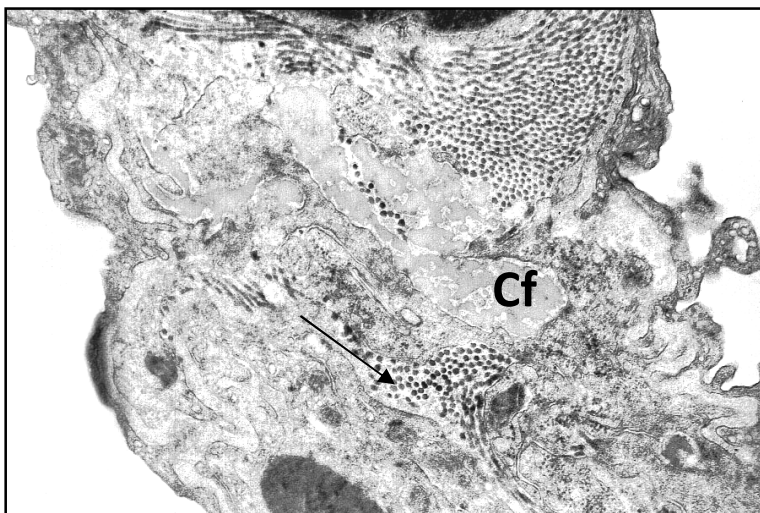


Fig. 54. Respiratory portion of the lung in hyperglycemia for 8 weeks.

The walls of the alveoli are thickened. In the blood capillaries (↑) there is a stasis of the formed elements. Infiltration zones (I) are revealed.



Staining: hematoxylin and eosin.

Magnification: 560X.

Fig. 55. Septal wall of the lung in hyperglycemia for 8 weeks.

Thickening of alveolar wall.

Between the fascicles of collagen fibers (Cf), the areas of mucoïd swelling (↑), the focal increase of elastic fibers (Ef) are revealed.

Embedding: araldite-epon.

Staining: uranyl acetate, lead citrate.

Magnification: 15000X.

Ef

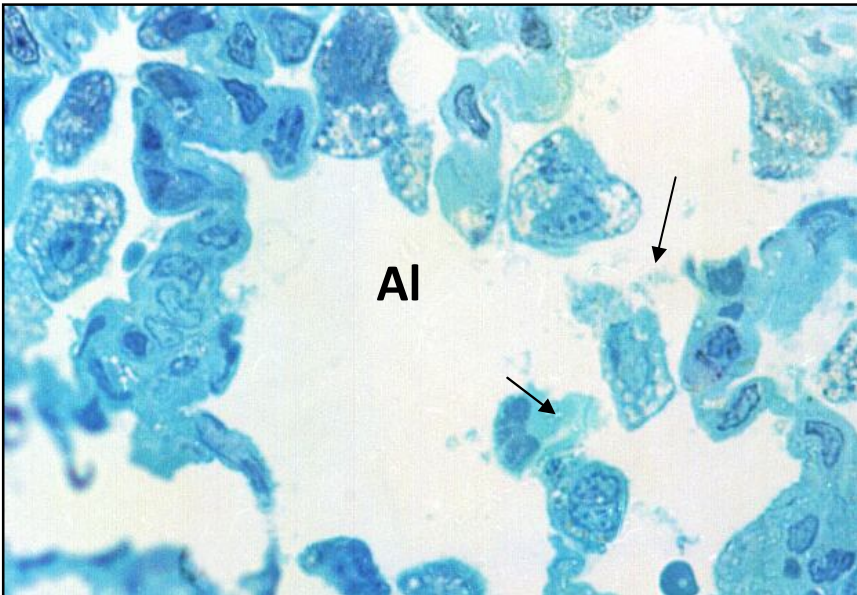


Fig. 56. Respiratory portion of the lung in hyperglycemia for 8 weeks.

Numerous large macrophages (↑) with a large number of vacuoles are revealed in the lumen of the alveoli.

The wall of the alveole (Al) is thickened due to the hypertrophy of the cells and the expansion of the blood capillaries.

Staining: methylene blue.

Magnification: 1000X.

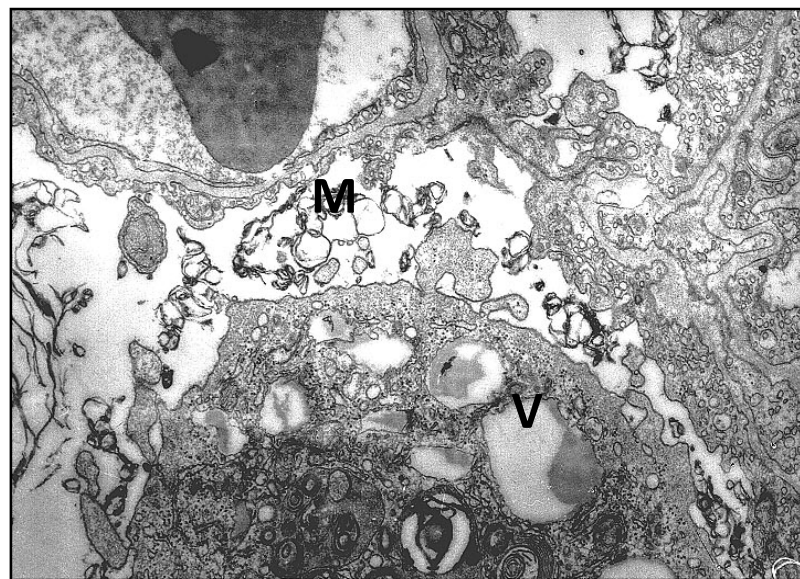

Fig. 57. Respiratory portion of the lung in hyperglycemia for 8 weeks.

The macrophage contains vacuoles (V) whose contents and size are different. In the lumen of the alveoli, clusters of membranes (M), different in size, are revealed.

Embedding: araldite-epon

Staining: uranyl acetate, lead citrate.

Magnification: 20000X.

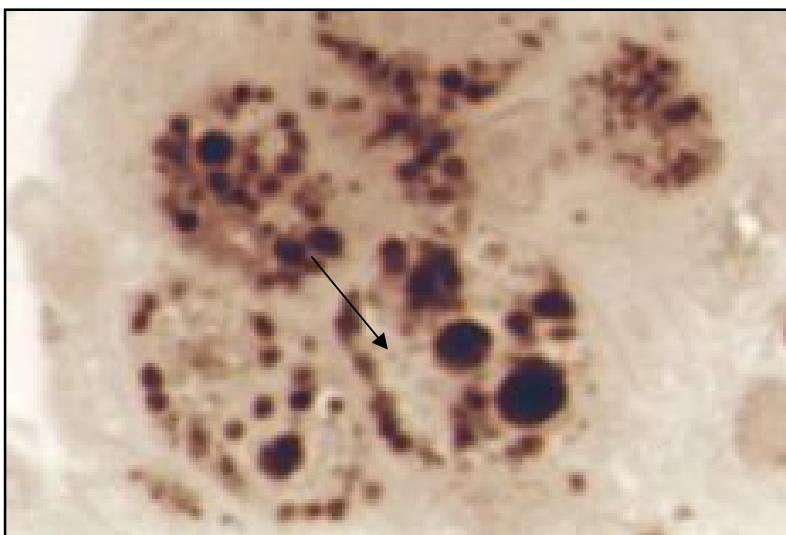

Fig. 58. Respiratory portion of the lung in hyperglycemia for 8 weeks.

In the wall of the alveoli, groups of cells with a large number of granules of product reaction with different sizes (↑) are localized.

In some cells, the granules are only detected in the layer.

Semi-finesection.

The reaction to the lectin of *Helix pomatia* in addition to methylene blue staining.

Magnification: 520X.

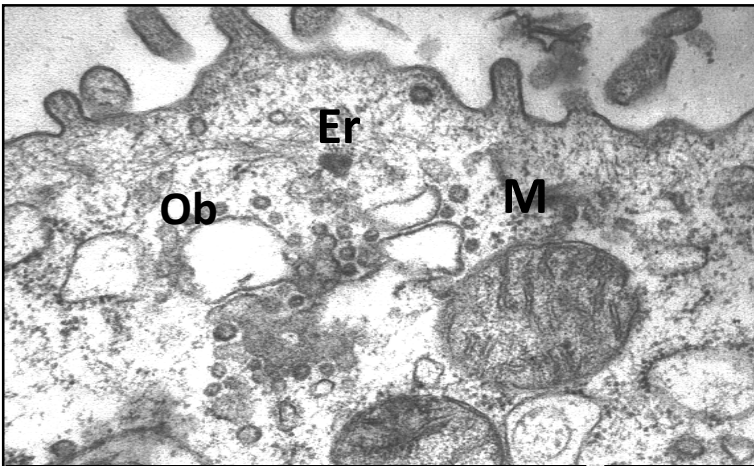


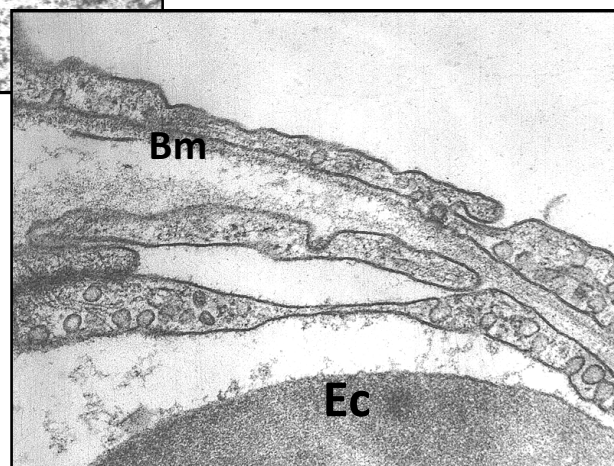
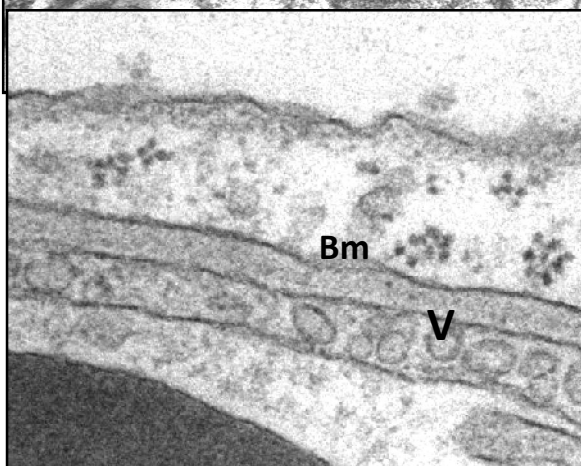
Fig. 59. Type 2 alveolocyte of the lung of rat with hyperglycemia for 8 weeks.

The tubules of the endoplasmic reticulum (Er) are enlarged, the mitochondria (M) are enlarged in size, the osmiophilic bodies (Ob) are singular.

Embedding: araldite-epon

Staining: uranyl acetate, lead citrate.

Magnification: 35000X.



A

B

Fig. 60. Wall of the alveole of the rat: A - intact, B - with hyperglycemia for 8 weeks. Focal increase in the thickness of the basement membrane (Bm), the appearance of small vacuoles (V) in the cytoplasm of the endotheliocyte (Ec) and in the alveocyte type 1 (A1). Embedding: araldite-epon Staining: uranyl acetate, lead citrate. Magnification: 25000X.

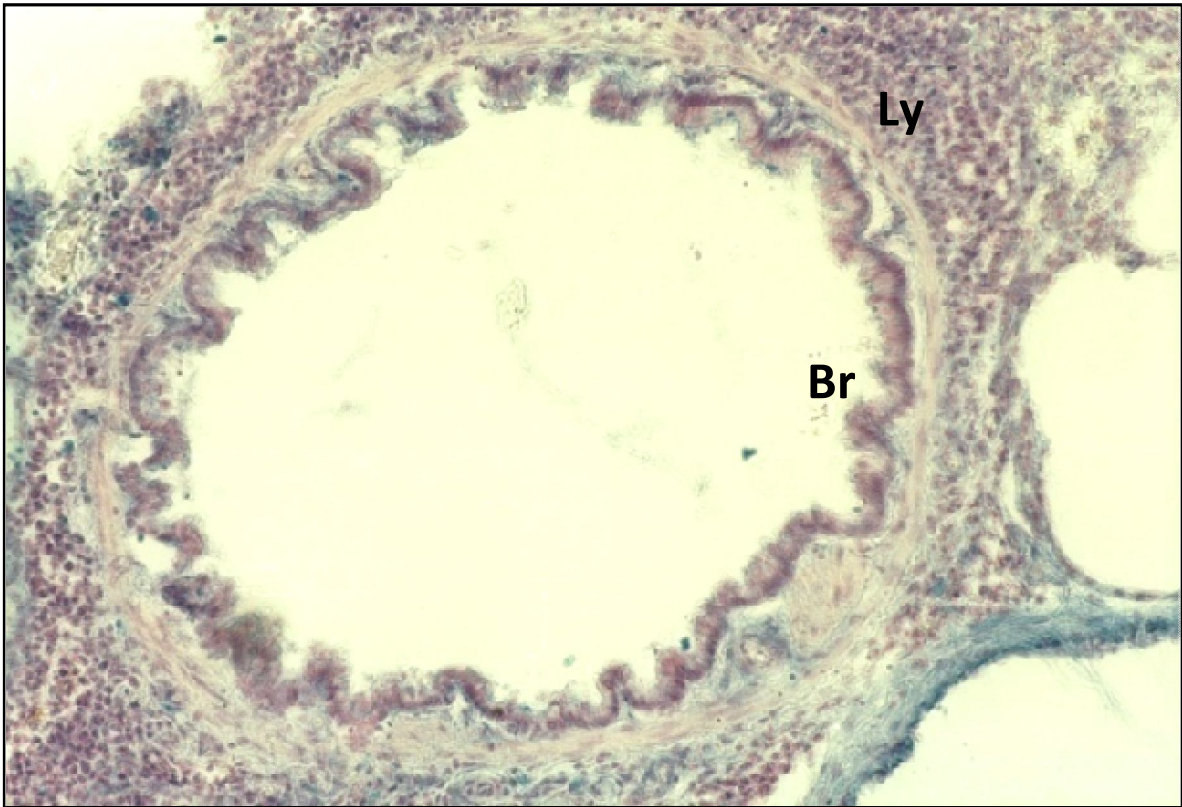


Fig. 61. The wall of the intralobular bronchus of the lung of the rat with hyperglycemia for 8 weeks.

Focal increase in the intensity of the reaction to glycosaminoglycans in the mucosa of the bronchus (Br), in the wall of the alveoli and in the peribronchial connective tissue, which is infiltrated by numerous lymphocytes (Ly). Staining: alcian blue 8 GX by Steedman. Magnification: 420X.

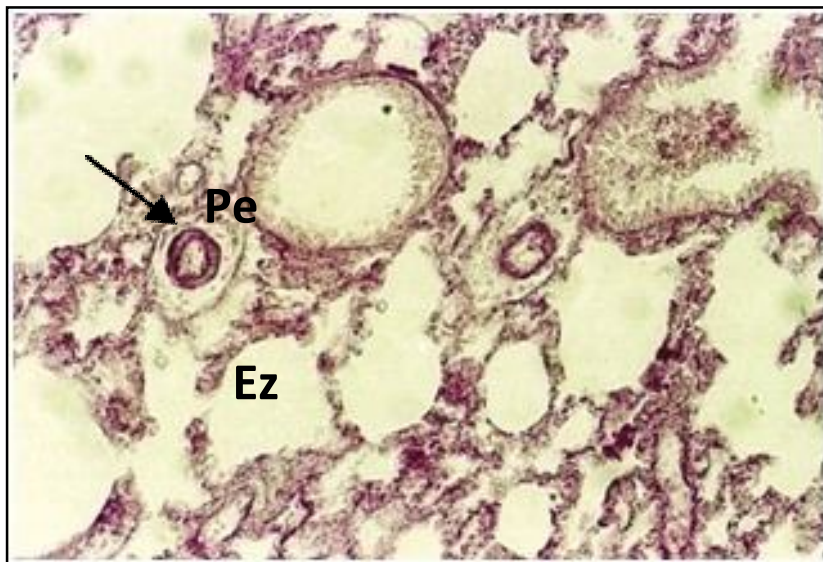

Fig. 62. Respiratory portion of the lung in hyperglycemia for 8 weeks.

An increase in the intensity of the reaction to PAS-positive substances (↑) in the wall of the blood vessels of the alveoli, in the basement membranes of the bronchi, in the inner and middle layers of the peribronchial vessels around which there are signs of perivascular edema (Pe). Along with the normal plan of the structure of the respiratory portion, the emphysematous zones (Ez) are revealed.

Staining: PAS-reaction of McManus. Magnification: 280X.

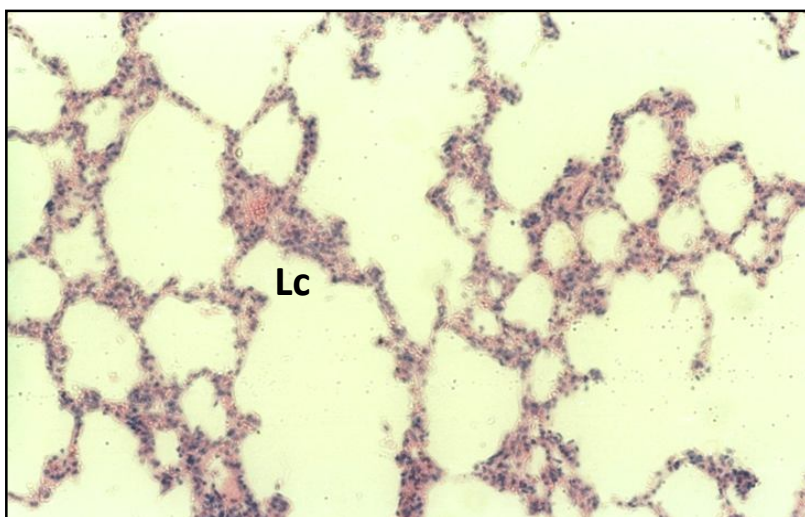


Fig. 63. The lung of rat with hyperglycemia for 8 weeks. In the peribronchial and interalveolar connective tissue there are significant areas of leukocyte infiltration (Lc) Staining: hematoxylin and eosin. Magnification: 400X.

Morphofunctional characteristics of the lung of rats in the experiment with hyperglycemia during 16 weeks

Long-term hyperglycemia leads to significant changes in both the bronchial tree and in the respiratory portion. In subsegmental and intralobular bronchi, significant hypertrophy of smooth muscle cells is revealed, between which the intercellular space increases, probably as a result of edema. In the peribronchial tissue, large lipiddroplets appear (Fig. 64). A part of the blood vessels is dilated, others are in a collapsed condition, and perivascular edema is defined. In some areas, concretion in the connective tissue, especially near the collapsed blood vessels, is noted; mast cells with signs of degranulation appear here (Fig. 65). In the peribronchial connective tissue, mature fibroblasts are usually located between bundles of collagen fibers, and numerous vacuoles are revealed in their cytoplasm (Fig. 66). A part of the bronchi is in a collapsed condition, in others the lumen is sharply enlarged. The zones of infiltration in the bronchi have mainly focal localization. Part of the alveoli is in a collapsed condition and filled with liquid. The walls of the alveoli are thickened due to a significant number of collagen fibers having different directions, usually located around the blood capillaries (Fig. 67). Sometimes there is a significant swelling of endotheliocytes and then their nucleated part almost covers the capillary lumen (Fig. 68). Numerous formed elements of blood are revealed in the lumen of the capillaries of the alveoli, and

around them there are zones of infiltration from lymphocytes and macrophages. Macrophages are usually large in size, arranged by groups, and have a light vacuolated cytoplasm (Fig. 69). The reaction to the lectin of *Helix pomatia* enabled to identify groups of cells containing a great amount of reaction products; along with this the granules are located along their entire surface (Fig. 70). Around the blood vessels there is a perivascular edema, and in some cases a pronounced diffuse or focal infiltration with lymphocytes and macrophages with the formation of nodules and infiltrates of the "granuloma" type (Fig. 71). The reaction to glycosaminoglycans increases, in the peribronchial connective tissue and in the blood vessels around which perivascular edema is detected (Fig. 72, 73). An extremely positive reaction to PAS-positive substances is detected in the wall of bronchial vessels and in interalveolar septa. A particularly large number of PAS-positive granules is observed in hypertrophied smooth muscle cells of the tunica media of the arteries. In the area of the perivascular edema the PAS - positive substances have focal localization. In the peribronchial connective tissue of lymphoepithelial formation the number of cells per unit area significantly increases. Among them, small lymphocytes are up to $85.6 \pm 3.61\%$; medium lymphocytes to $27.8 \pm 1.57\%$; macrophages up to $12.3 \pm 2.07\%$; mast cells up to $5.3 \pm 0.74\%$; plasmocytes to $3.7 \pm 0.18\%$ (Table 8).

SUMMARY. In the setting of prolonged hyperglycemia in the bronchial wall, there is an increase in the muscle plate of the mucosa, the appearance of large lipid droplets, the induration of peribronchial connective tissue, the increase in the number of cells in the lymphoepithelial structures, structural changes in bronchial vessels and perivascular edema. The intensity of the reaction to PAS-positive substances and glycosaminoglycans in the connective tissue of the bronchial wall and in the blood vessels around which "granulomas" formations are developed, increases. In the respiratory portion, the wall of the alveoli thickens, pericapillary sclerosis, swelling of endotheliocytes, stasis of formed elements in the lumen of

capillaries, extensive infiltrates from lymphocytes and macrophages, as well as a significant increase in the reaction to PAS-positive substances in the interalveolar septa are observed.

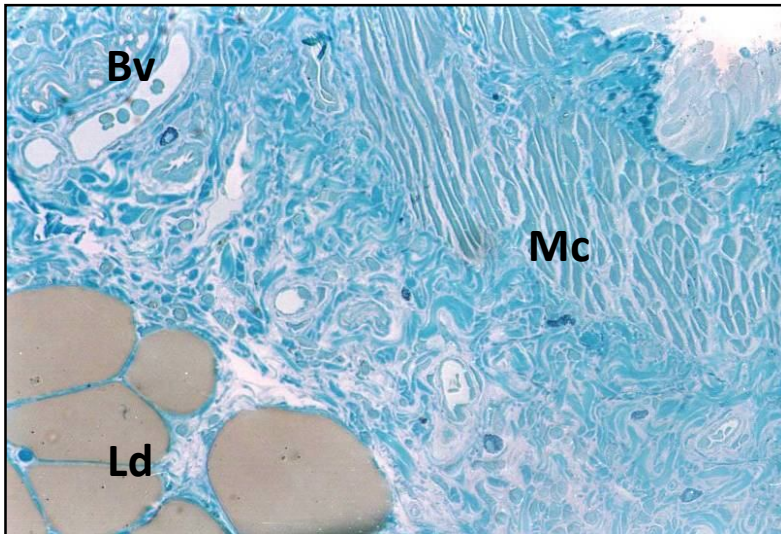


Fig. 64. The lung of a rat with hyperglycemia for 16 weeks.

Hypertrophy of smooth muscle cells (Mc) of the bronchus wall. In the peribronchial tissue, there are focal zones of induration of connective tissue. The blood vessels (Bv) are enlarged. Here a significant number of large lipid droplets (Ld) is identified.

Semi-fine section.

Staining: methylene blue. Magnification: 480X.

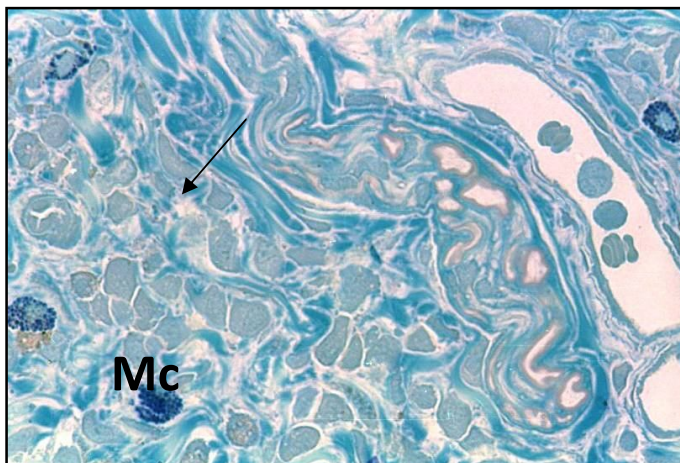


Fig. 65. The lung of a rat with hyperglycemia for 16 weeks.

Some blood vessels (Bv) are dilated, others are in a collapsed condition, around them there is a focal induration of the connective tissue (↑). In some cases, there are signs of a perivascular edema. There are mast cells (Mc) containing numerous granules

Semi-fine section. Staining: methylene blue. Magnification: 1000X.

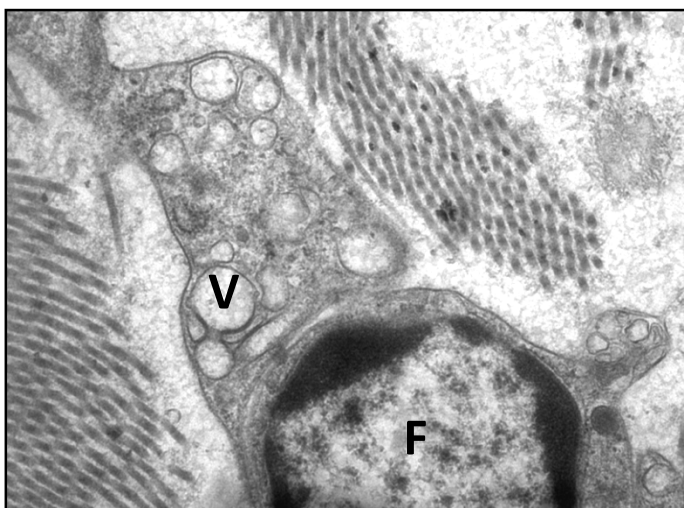


Fig. 66. Peribronchial connective tissue of rat in hyperglycemia for 16 weeks.

Mature fibroblast (F) is located between the bundles of formed collagen fibers. In its cytoplasm there are many large vacuoles (V), under the karyolemma there is a layer of compact chromatin.

Embedding: araldite-epon

Staining: uranyl acetate, lead citrate. Magnification: 15000X.

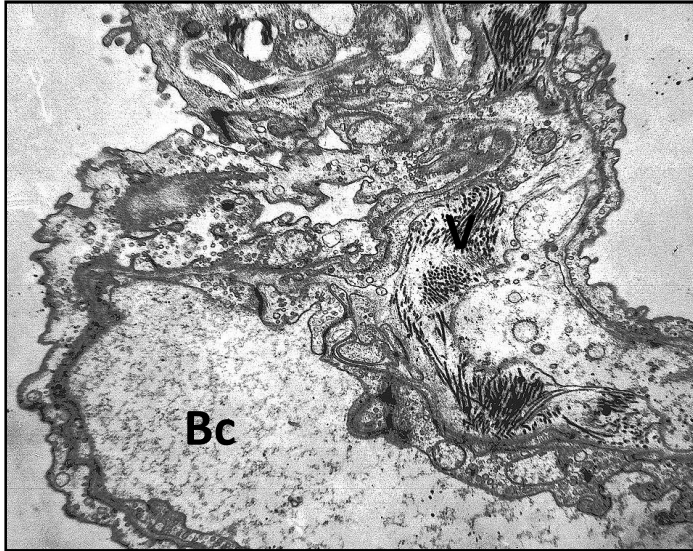


Fig. 67. The wall of the alveoli of the rat in hyperglycemia for 16 weeks.

The lumen of the blood capillaries (Bc) is enlarged, has a different size and is surrounded by bundles of numerous fibers (F) having different directions.

Embedding: araldite-epon.

Staining: uranyl acetate, lead citrate.
Magnification: 10000X.

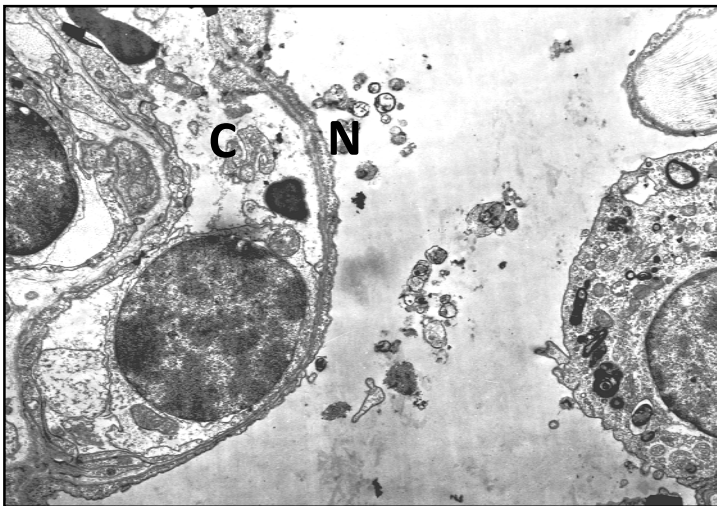


Fig. 68. Respiratory portion of a rat in hyperglycemia for 16 weeks.

In the lumen of the capillary (C) the nucleated part of the endotheliocyte (N) is bulging, covering its lumen.

Embedding: araldite-epon.

Staining: uranyl acetate, lead citrate.
Magnification: 7000X.

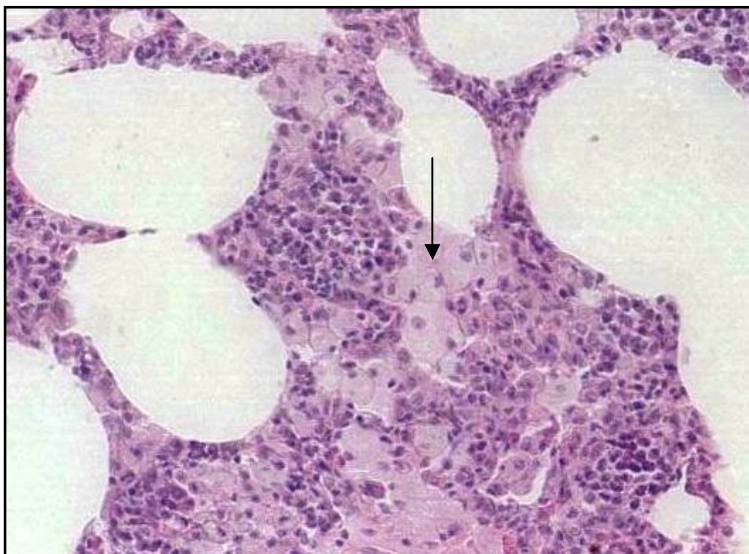


Fig. 69. Respiratory portion of a rat in hyperglycemia for 16 weeks.

The interalveolar septa are thickened, infiltrated by numerous lymphocytes and macrophages (↑), which predominantly have focal localization.

Staining: hematoxylin and eosin.

Magnification: 680X.

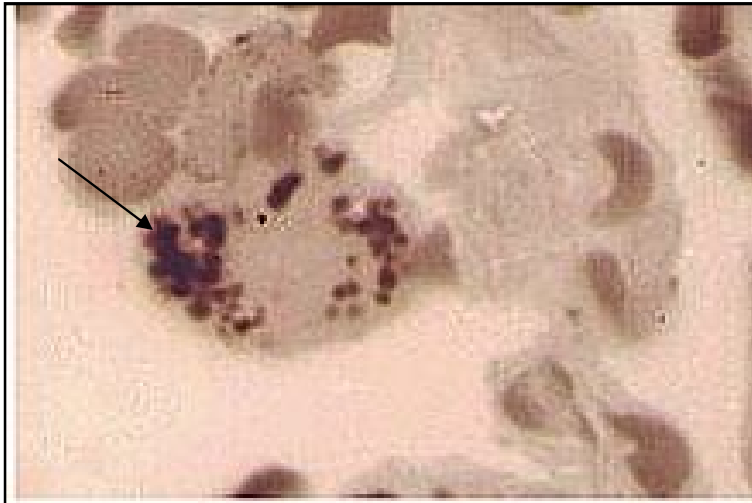


Fig. 70. Respiratory portion of a rat in hyperglycemia for 16 weeks

In the alveolar wall, groups of cells containing numerous granules of reaction products (↑) are localized.

Semi-fine section.

The reaction to the lectin of *Helix pomatia* in addition to methylene blue staining.

Magnification: 1000X.

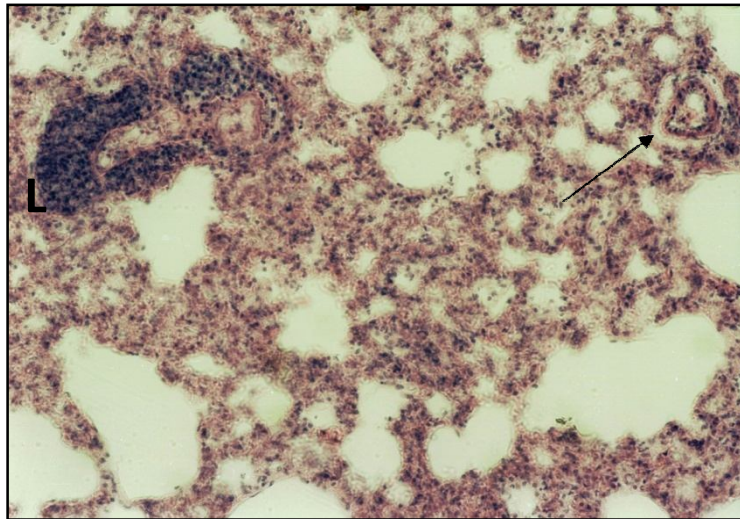


Fig. 71. Respiratory portion of a rat in hyperglycemia for 16 weeks

Most alveoli are in a collapsed condition, there are numerous cells in the lumen. There is perivascular edema (↑) and in these areas diffuse or focal infiltration of lymphocytes (L) (granuloma formations) is detected.

Staining: hematoxylin and eosin.

Magnification: 280X.

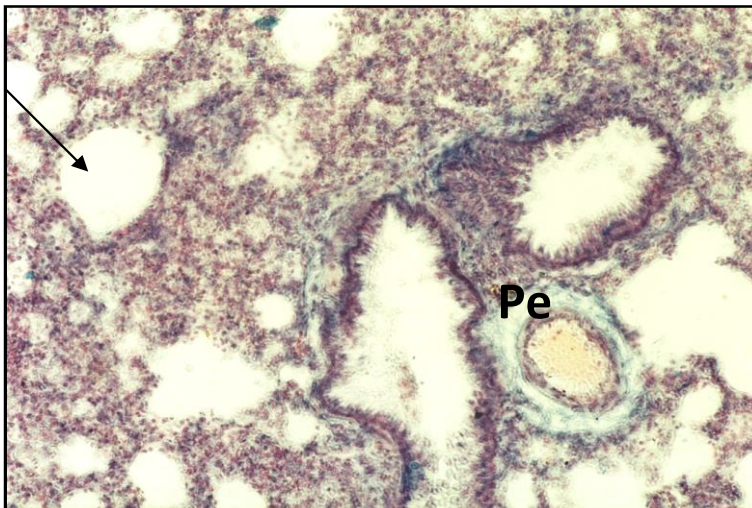


Fig. 72. The lung of a rat with hyperglycemia for 16 weeks.

Atelectasis and extensive infiltration of alveoli (↑) by lymphocytes.

Increased intensity of reactions to glycosaminoglycans in the bronchus wall and in the perivascular edema zone (Pe). In the wall of the alveoli, the reaction is moderate.

Staining: alcian blue 8 GX by Steedman.

Magnification: 280.

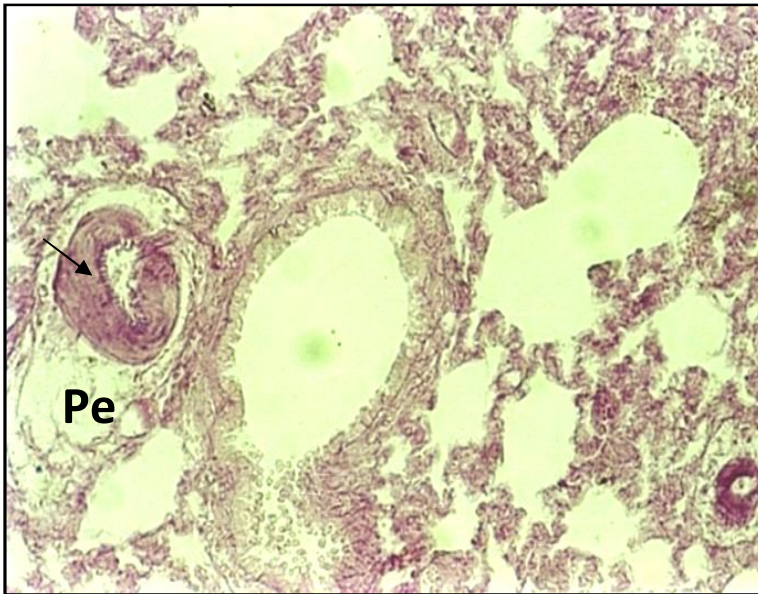


Fig. 73.
Respiratory portion of a rat in hyperglycemia for 16 weeks.
Pronounced hypertrophy of the muscular membrane of blood vessels with a high content of PAS-positive substances (↑). Perivascular edema (Pe). PAS-positive reaction in the wall of the blood vessels of the alveoli.
Staining: PAS-reaction of McManus. Magnification: 280X.

Constant contact of the lung with a large amount of oxygen, especially in the setting of hyperglycemia, leads to a significant activation of the LPO reaction, which is one of the causes of cell damage and death. This leads to the development of pathological changes in all structures of the respiratory system and especially in the blood vessels. It is known that the high activity of LPO reactions in DM directly correlates to the severity of vascular complications [Efimov, A. S., 1989; Balabolkin, M. I., 2000; Saltykov, B. B., 2000].

With hyperglycemia for 8 weeks, the general plan of the structure of the respiratory system is preserved, but at the same time there are numerous areas of atelectasis and emphysema parts in the respiratory portion. There is an increase in the thickness of the muscle plate of the bronchial mucosa and perivascular edema mainly around the venous vessels, in which stasis of the formed elements is noted. The infiltration of peribronchial connective tissue increases, and the number of lymphoblasts, small lymphocytes, macrophages statistically significant increases in the lymphoepithelial formations; plasma cells appear. In the interlayers of the connective tissue of the bronchi, in the wall of the blood vessels and interalveolar septa, the intensity of the reaction to glycosaminoglycans and PAS-positive

substances increases. In the septal walls, the number of collagen fibers increases, and zones of mucoid swelling appear. There are signs of hypertrophy in the alveocytes of type I, the basement membrane of the alveoli thickens. In alveocytes of type II, the number of osmiophilic bodies is significantly reduced, which probably reflects a decrease in their secretory activity, a decrease in the surfactant lining of the alveoli, and this contributes to the development of injuries of the respiratory portion of the lungs. In the alveolar lumen there are numerous macrophages, in most of which ligands of the lectin *Helix pomatia* are detected, which indicates the activation of the differentiation process and the appearance of maturing macrophages. It is fair to assume that this is associated with hyperglycemia. It is known that the number of macrophages in the lumen of the alveoli depends on the level of glucose in the blood and the severity of plasmorrhagia [Kodolova, I. M., 1982; Shcherbak, A. V., 1986; Toso, C., 2008]. Apparently, in such conditions with a high level of blood glucose, macrophages play an active role in the resorption and removal of byproducts coming from the vascular bed into the wall and lumen of the alveoli.

In the dilated capillaries of the walls of the alveoli, aggregates of erythrocytes, focal edema of the subendothelial space, structural changes in the endothelial cells appear, i.e. these changes indicate a decrease in the transportation of gases of the respiratory portion of the lung. It is considered that with DM intracellular accumulation of sorbitol in the vessel wall occurs, this leads to hyperosmolarity, development of edema and swelling of cells and intercellular substance, and as a result of impaired vascular wall permeability [Genyk, S. N., 1989; Bobyreva, L. E., 1996; Lipatov, D.V., 2012; Jennings, P. E., 1987].

Thus, in the setting of 8-week hyperglycemia, a complex of nonspecific changes appears which plays a very significant role in the development of lung pathology.

Hyperglycemia for 16 weeks is accompanied by pronounced changes in the lungs. A part of the bronchi is in a collapsed condition, in others the lumen is enlarged, the walls of the alveoli are thickened. The distances between smooth muscle cells of the bronchial mucosa are increased, in the peribronchial connective tissue, signs of sclerosis and the appearance of large lipid droplets are revealed. In connection with this, it should be noted that during such a long-term experiment, the age of rats at the time of slaughter was about 9 to 10 months; however such pronounced sclerotic changes in the connective tissue of the lung were observed only in experimental animals. Around the bronchial blood vessels there is perivascular edema and marked infiltration of lymphocytes and macrophages by the type of granuloma formations, which indicates the leading role of metabolic disturbances in carbohydrate metabolism and plasmorrhagic processes in the development of diabetic angiopathies [Saltykov, B. B., 1984; Dedovl. I. et al, 2003]. According to a number of authors, the excessive lipid hydroperoxidation plays an important role in the progression of structural disorders in the lungs [Lysenko, L. V., 1990; Lyaifer, A. I., 1993; Sazonova, O. V., 2000; Wang, J.Y., 2014]. Taking into consideration that the lungs are constantly in contact with oxygen, as well as with such active initiators of peroxidation as ozone and nitrogen dioxide, there are all conditions for activation of the LPO reaction in the development of a hyperglycemic state. In addition, there are numerous macrophages in the lung, which, under pathological conditions, can affect the activity of the free radical oxidation reaction [Romanova, L. K., 1991; Nathan, C. F., 1982; McDonald, R. J., 1991].

In hyperglycemia, the vascular bed and especially the endothelial cells are the most vulnerable because the highly reactive products of LPO and oxygen free radicals formed as a result of glucose oxidation have a damaging effect on them. It has been established that the lung structure abnormalities by products of free radical oxidation leads to an increase in the secretion of biologically active substances, which increase vascular permeability, that can lead to the development

of an inflammatory reaction. In the peripheral zone of lymphoepithelial formations, the number of cells increases due to a considerable increase in the number of small lymphocytes, macrophages, plasma and mast cells. Along with this, macrophages usually have a large size and a light vacuolated cytoplasm. It appears that in conditions of high plasmorrhagia macrophages actively provide resorption and removal of byproducts coming from the bloodstream into the wall and lumen of the alveoli. However as the structural changes in the vessels of the microcirculatory bloodstream and in the alveolar septa increase, due to the repeated process of induction, there is an excessive accumulation of byproducts and, as a result, a decrease in the phagocytic activity of macrophages, as evidenced by the accumulation of an abundance of vacuoles in their cytoplasm.

According to some authors, the weakening of the local lung protection system is a negative pathogenetic factor that worsens pathogenic mechanism in respiratory organs in diabetes mellitus [Strukov, A. I., 1990; Nazhmutdinova, D. K., 2000; Fournier, M., 1977]. In the peribronchial connective tissue, bundles consisting of collagen fibers grow in size, their number increases in the wall of the alveoli, especially around the blood capillaries. Reactions to PAS-positive substances and glycosaminoglycans are preserved at a high level of in the connective tissue and wall of blood vessels. The swelling of endotheliocytes in the blood capillaries of the alveoli is revealed, frequently enough accumulations of formed elements are found in them, almost completely covering the lumen. Basement membranes of capillaries thicken, the number of PAS-positive substances increases in them. Consequently in the lungs of a large network of blood vessels, developing angiopathy take on particular significance. The whole complex of changes leads to a decrease in the number of functionally active capillaries, and this initiates the development of hypoxia, the growth of dystrophic processes in connective tissue and, as a result, the formation of interstitial fibrosis.

Thus, the changes observed by us with 16-week hyperglycemia indicate the appearance of specific morphological features, such as granulomatous perivascular formations, collapsed capillaries with a thickened wall, typical for lung lesions with DM [Lysenko, L. V., 1990; Zhestovskiy, S. S., 2007; Shoikhet, Y.N., 2008]. If in the beginning in pulmonary tissue with DM, the above-described changes are of a diffuse nature, and therefore they can be compensated for a long time, then in the future this leads to aggravation of pathological processes in the lungs and complication of the DM itself, which defines the necessity of finding ways to correct them.

Morphofunctional characteristics of the lung of rats in the experiment with hyperglycemia in the setting of dihydroquercetin administration for 8 weeks

Changes in the mucosa of subsegmental and intralobular bronchi are of a focal character: on longitudinal sections it is seen that the elastic fibers are fragmented, the muscle plate is somewhat thickened in comparison with the control. Migration of numerous mast cells through the epithelium is observed. In the respiratory portion, the majority of the alveoli retain the structural plan typical of intact animals (Fig. 74). A part of the alveoli are emphysematically dilated, their walls are thinned. Elastic fibers of the alveoli are focally thickened, in some areas they are fragmented (Fig. 75).

In the lumen of the alveoli and in the connective tissue of the bronchi there is a significant number of small macrophages. The reaction to the lectin of *Helix pomatia* showed that the number and size of the granules of the reaction product in cells in the lumen of the alveoli decreases in comparison with the control. The granules have focal localization (Fig. 76). The reaction to glycosaminoglycans is reduced, especially in the interalveolar septa, but remains at a fairly high level in the bronchial blood vessels. The reaction to PAS-positive substances remains rather high.

In the wall of the alveoli it has a mosaic character; the largest number of granules is detected in the basement membranes of the capillaries. The most intensive reaction to neutral polysaccharides persists in the peribronchial connective tissue and in the walls of blood vessels.

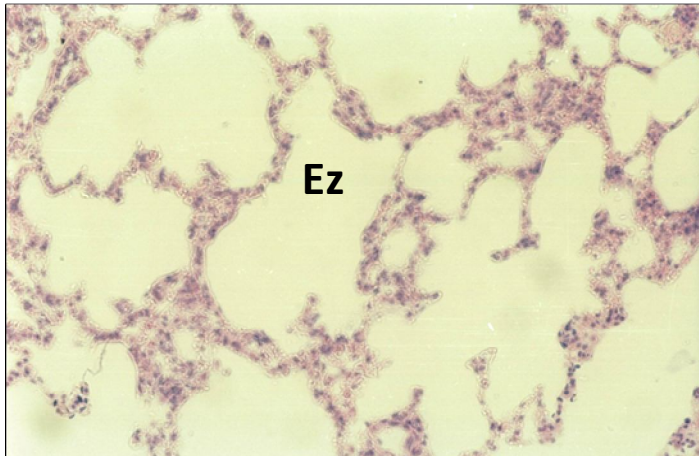


Fig. 74. Respiratory portion of the lung in hyperglycemia for 8 weeks in the setting of dihydroquercetin administration.

Most alveoli have a normal structural plan. There are emphysematous zones (Ez).

Staining: hematoxylin and eosin.

Magnification: 260X.

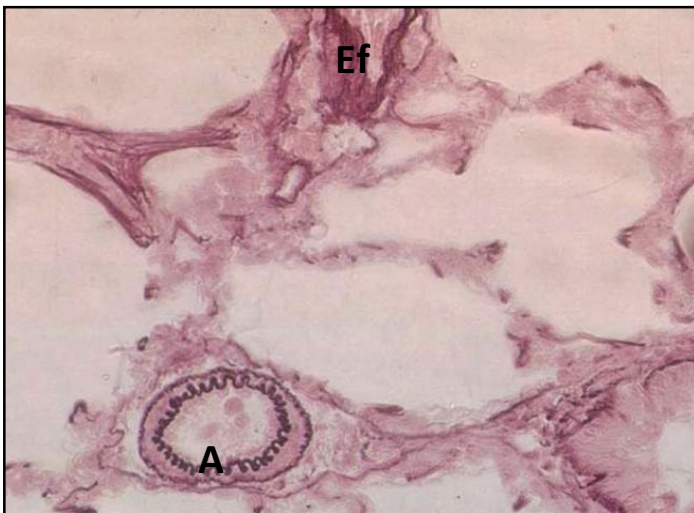


Fig. 75. Respiratory portion of the lung in hyperglycemia for 8 weeks in the setting of dihydroquercetin administration.

Elastic fibers (Ef) in the wall of the alveoli are focally thickened, located in groups. In some alveoli they are fragmented. Elastic membranes in the artery wall (A) are well defined.

Staining: Weigert's resorcin fuchsin.

Magnification: 260X.

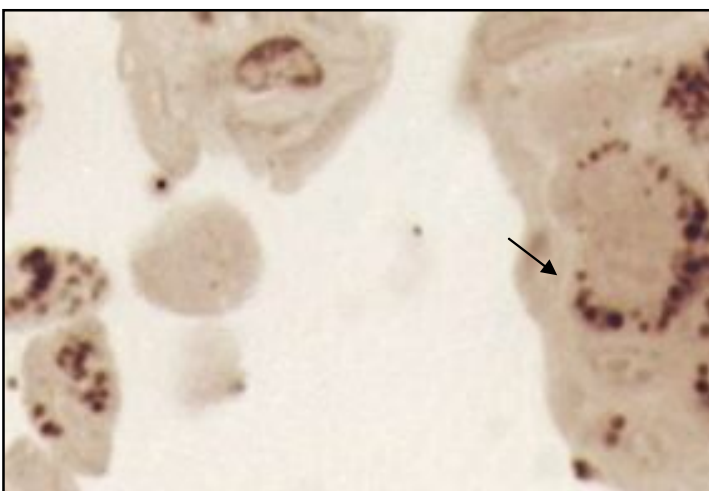


Fig. 76. Respiratory portion of the lung in hyperglycemia for 8 weeks in the setting of dihydroquercetin administration.

In the alveole there are cells containing mostly small granules of the reaction product, which have focal localization (↑). Semi-fine section.

The reaction to the lectin of *Helix pomatia* in

addition to methylene blue staining.

Magnification: 560X.

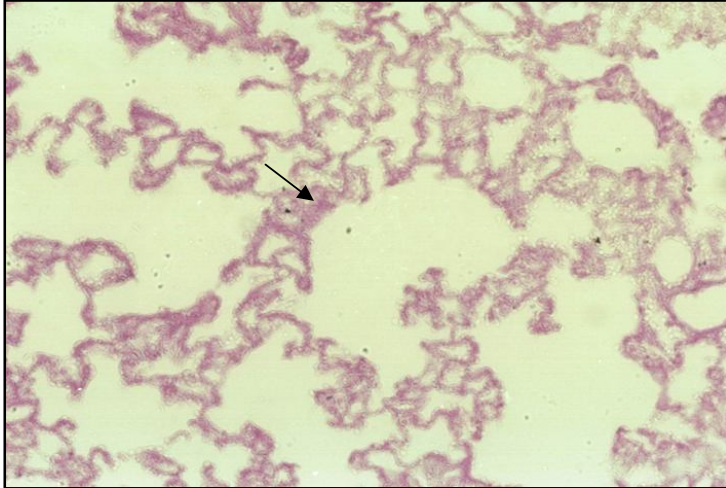


Fig. 77. Respiratory portion of the lung in hyperglycemia for 8 weeks in the setting of dihydroquercetin administration.

Reaction to PAS - positive substances in the wall of the alveoli is mosaic. Intensification of the reaction was noted in the basement membranes of hemocapillaries (↑)

Staining: PAS-reaction of McManus. Magnification: 200X.

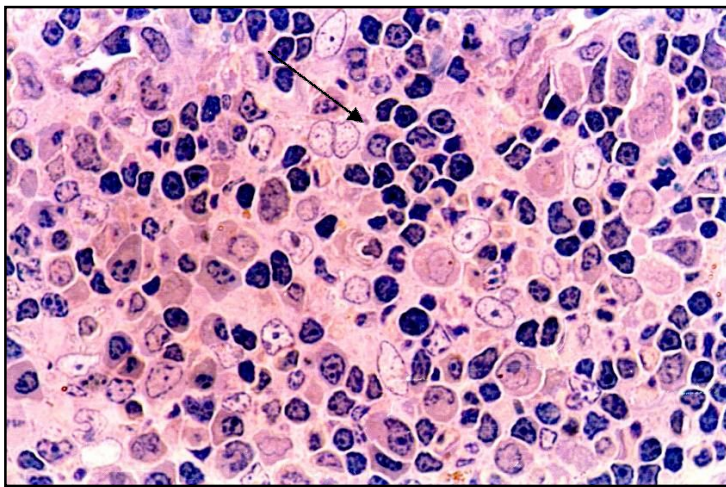


Fig. 78. The adventitious membrane of rat bronchus with hyperglycemia for 8 weeks in the setting of administration of dihydroquercetin.

Lymphoepithelial formation includes numerous lymphoblasts, polymorphocytes, macrophages and a moderate number of mature lymphocytes (↑).

Staining: hematoxylin and eosin.

Magnification: 1000X.

Table 8

THE NUMBER OF CELLULAR ELEMENTS IN THE PERIPHERAL ZONE OF LYMPHOEPITHELIAL FORMATIONS OF SUBSEGMENTARY AND INTRALOBULAR BRONCHI

Indices	Lymphoblasts	Medium lymphocytes	Small lymphocytes	Macrophages	Plasmocytes	Mast cells
Groups of animals						
Hyperglycaemia for 8 weeks (control 1)	6,7± 0,32	23,2 ± 2,8	68,7 ± 4,01	8,3 ± 0,72	3,1± 0,48	1,4 ± 0,3
Hyperglycemia for 8 weeks with dihydroquercetin	8,4± 0,35	29,1± 1,01*	45,3± 5,7*	10,1± 0,82	0,5±0,17*	0,8± 0,21
Hyperglycaemia for 16 weeks (control 2)	5,3± 0,54	27,8 ± 1,57	85,6 ± 3,61	12,3 ± 2,07	3,7± 0,18	5,3± 0,74
Hyperglycemia for 16 weeks with dihydroquercetin	4,7± 0,42	20,3± 2,6	51,7± 3,71**	7,92± 0,57**	1,4± 0,27**	1,7±0,29**

* p< 0,05 in comparison with 1st control group

** p< 0,05 in comparison with 2nd control group

In the peripheral zone of the lymphoepithelial formation of the bronchi, cellular elements are located diffusely; sometimes they cover the adjacent sections of the lung parenchyma. In their structure the number of lymphoblasts increases significantly (up to 8.4 ± 0.35%) and medium lymphocytes (up to 29.1 ± 2.01%) in the setting of a decrease in small lymphocytes (up to 45.3 ± 5.7%) and plasmocytes (Table 8). The number of macrophages increases to 10.1 ± 0.82% (in control - 8.3 ± 0.72%).

SUMMARY. Thus, the administration of dihydroquercetin in the setting of hyperglycemia makes it possible to preserve the typical plan of the structure in most

alveoli. In the lumen of the alveoli and their walls, a large number of mature macrophages are detected, since the number of granules of the reaction products to the lectin decreases as the cells mature. In lymphoepithelial formations, the number of lymphoblasts and medium lymphocytes increases in the setting of the decrease of the number of small lymphocytes, plasmatic and mast cells. At the same time, the migration of the latter through the epithelium increases. The phenomena of perivascular edema are moderately expressed. The intensity of the reaction to PAS - positive substances and glycosaminoglycans in the walls of bronchial blood vessels significantly decreases.

Morphofunctional characteristics of the lung of rats in the experiment with hyperglycemia in the setting of dihydroquercetin administration for 16 weeks

In the setting of sustained hyperglycemia, the administration of dihydroquercetin somewhat reduces the structural changes in the wall of the intra-lobular bronchi in comparison with the control. The focal folding of the mucous coat is revealed, in these areas the smooth muscle cells are hypertrophied (Fig. 79). In the peribronchial connective tissue, the indurated parts alternate with the zones of muroid swelling. There, mainly young fibroblasts with dilated tubules of the endoplasmic reticulum and nuclei of usually irregular shape are found, in which the chromatin is located on the periphery by a narrow rim, the nucleolus is well contoured. The fibers surrounding the fibroblast are located at a considerable distance from each other (Fig. 80). In the respiratory portion the shape and size of the alveoli varies, some of them preserve the usual plan of the structure, there are emphysematous zones. In the majority of alveoli, the wall is thickened, there are elastic fibers in it, the number and size of which are different. Hypertrophy of alveolocytes is revealed. Lymphoid infiltration in the respiratory portion has focal localization, macrophages are rare. The reaction to the lectin of *Helix pomatia* made it possible to identify in the lumen of the alveoli individual cells containing small

granules of the reaction product unevenly distributed along the cell contour. In the part of bronchial vessels, there is a perivascular edema, here the reaction to PAS-positive substances is poorly expressed (Fig. 81). The high level of PAS-positive substances was noted in the wall of bronchial vessels and in interalveolar septa (Fig. 82), although in the latter the level of the reaction is much lower than in the control.

The reaction to glycosaminoglycans significantly decreases in the peribronchial connective tissue, in large blood vessels it remains at a fairly high level. In the wall of the alveoli, the glycosaminoglycan content is moderate and has a focal localization (Table 9).

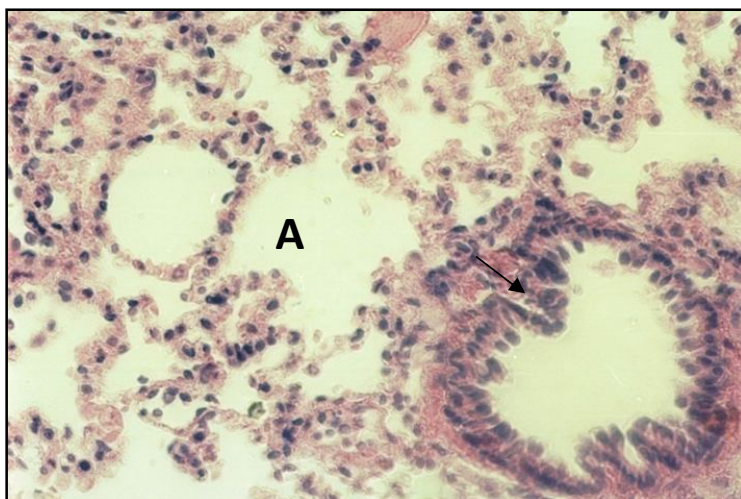


Fig. 79. Respiratory portion of lung of a rat at 16 weeks of hyperglycemia in the setting of dihydroquercetin administration.

The shape and size of the alveoli (A) vary. There is swelling of alveocytes and a moderate amount of macrophages in the lumen of the alveoli. The wall of the bronchi is thickened (↑).

Staining: hematoxylin and eosin.

Magnification: 420X.

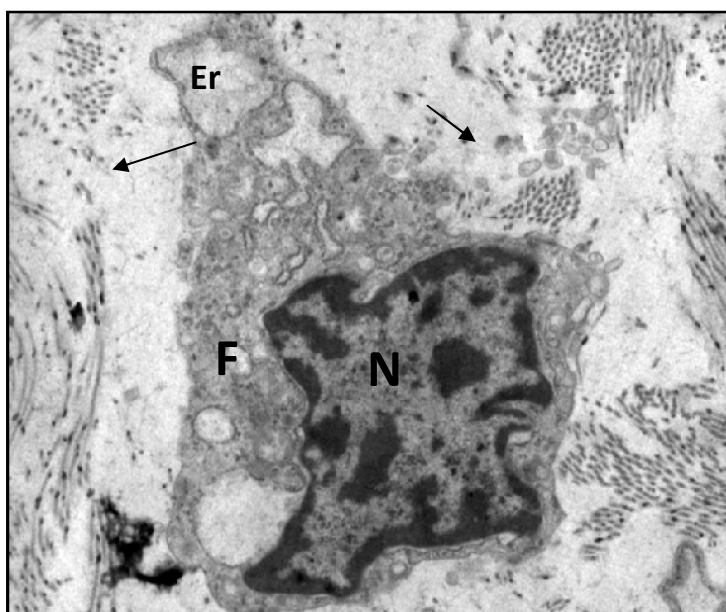


Fig. 80. Peribronchial connective tissue at 16 weeks of hyperglycemia in the setting of dihydroquercetin administration.

Fibroblast (F) has rugged contours of the nucleus. Chromatin in the form of a narrow zonule, is located along the periphery of the nucleus. The nucleolus (N) is well contoured. The tubules of the endoplasmic reticulum (Er) are widened in a focal point. Fine fibrous structures are visible around the cell (↑).

Embedding: araldite-epon.

Staining: uranyl acetate, lead citrate.

Magnification: 12000X.

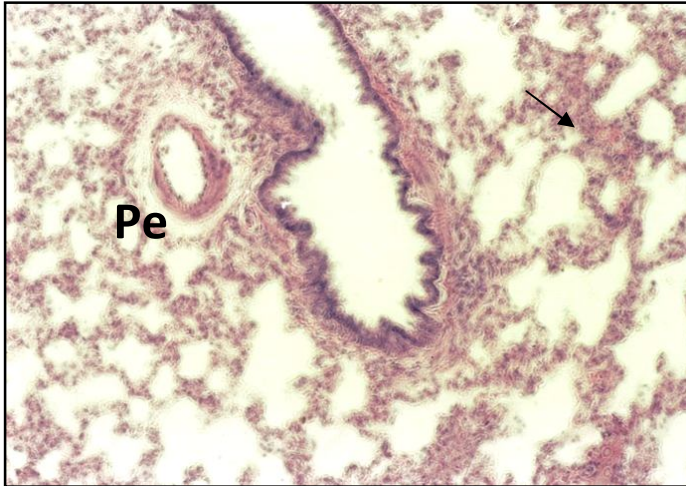


Fig. 81. Respiratory portion of lung of a rat at 16 weeks of hyperglycemia in the setting of dihydroquercetin administration.

Focal enhancement of PAS - reactions in the wall of the alveoli (↑), blood vessels and bronchial mucosa. Perivascular edema (Pe).

Staining: PAS-reaction of McManus hematoxylin staining. Magnification: 280X.

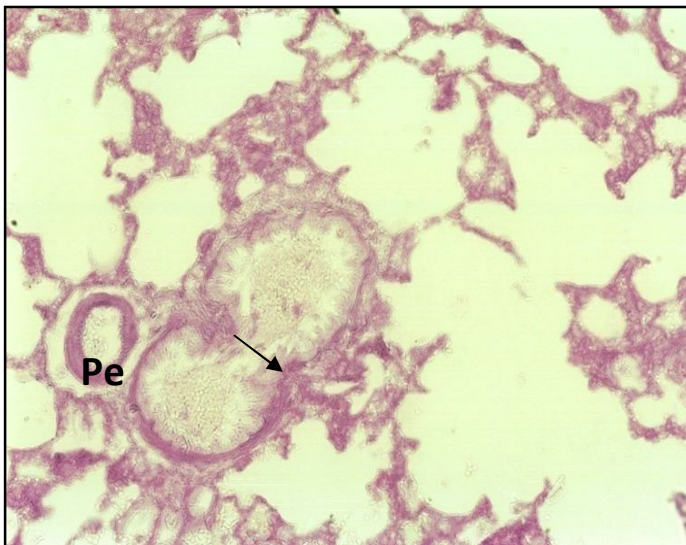


Fig. 81. Respiratory portion of lung of a rat at 16 weeks of hyperglycemia in the setting of dihydroquercetin administration.

Focal increase in PAS - positive substances in the blood capillaries of the alveoli, in the peribronchial connective tissue and in the middle layer of the blood vessels (↑). Perivascular edema. In the peribronchial connective tissue, the effects of edema are focal.

Staining: PAS-reaction of McManus.

Magnification: 280X.

Analysis of the peripheral zone of lymphoepithelial formation revealed a decrease in the total number of cells on an area of $10,000 \mu\text{m}^2$, a significant decrease in the number of small and medium lymphocytes, macrophages, mast and plasma cells (Table 9).

SUMMARY. With a long-term hyperglycemia, the administration of dihydroquercetin reduces the level of structural changes in the bronchial tree and in

the respiratory portion of the lung. In the peribronchial connective tissue, in the setting of areas with an increased number of fibers, the areas of mucoid swelling are revealed; the intensity of the reaction to glycosaminoglycans and PAS-positive substances is reduced, the infiltration zones are small, the number of cells of various types decreases. Perivascular edema is less significant. In the respiratory portion, the majority of the alveoli preserves the general plan of the structure. The number of PAS - positive granules and the content of glycosaminoglycans in the bronchial vessels and vessels of the microcirculatory bloodstream of the alveolar wall decreases.

Table 9

AUTHENTICITY OF CHANGES OF INTENSITIVENESS OF THE REACTION TO PAS-POSITIVE SUBSTANCES AND GLYCOSAMINOGLYCANS IN THE LUNG OF INTACT AND EXPERIMENTAL ANIMALS (in conventional units)

	Glycosaminoglycans			PAS-positive substances		
	Peribronchial connective tissue	Bronchial blood vessels	Interalveolar septum	Peribronchial connective tissue	Bronchial blood vessels	Interalveolar septum
Hyperglycemia * for 8 weeks (control)	↑	↑	↑	↑	↑	↑
Hyperglycemia ^ for 8 weeks with dihydroquercetin	0	↓	↓	0	↓	↓
Hyperglycemia * for 16 weeks (control)	↑	↑	0	↑	↑	↑
Hyperglycemia # for 16 weeks with dihydroquercetin	0	↓	0	0	↓	↓

* in comparison with intact animals;

^ in comparison with a control of 8 weeks;

in comparison with a control of 16 weeks;

↑ statistically significant increase; ↓ statistically significant decrease; 0 absence of significant differences.

The administration of dihydroquercetin in the setting of 8-week hyperglycemia made it possible to preserve the plan of the structure typical of intact animals in most alveoli. Changes in lymphoepithelial formations with the administration of drug substances were as follows: a large number of lymphoblasts,

medium lymphocytes and mature macrophages are preserved in the setting of a decrease in the number of small lymphocytes. Positive dynamics is observed in the peribronchial connective tissue and in the interalveolar septa; a tendency to reduce the level of reaction to glycosaminoglycans and PAS-positive substances has been noted here. At the same time, both in the wall of the blood vessels and in the basement membranes of the hemocapillaries, a fairly high focal intensive reaction to neutral polysaccharides remains there.

In the setting of 16-week hyperglycemia, the administration of dihydroquercetin somewhat reduces structural changes in the respiratory portion of the lung, but the observed situation is very mosaic. The part of the alveoli preserves the usual plan of the structure, the others are emphysematically dilated, and some have a thickened wall due to the increase, generally, of the elastic fibers. There is moderate hypertrophy in the alveocytes, focal alveolar wall infiltration and a slight decrease in activity to the PAS-positive substances in the interalveolar septa and in the basement membrane of the capillaries.

Infiltration zones in the peribronchial connective tissue are reduced, along with this, a decrease in the number of lymphoblasts, medium lymphocytes, plasmocytes and mast cells is observed. It is believed that a decrease in the number of young forms of lymphocytes, in the setting of increased mature ones, is most often associated with an improvement in the blood supply of this area [Strukov, A. I., 1990]. In the connective tissue of the bronchial tree there are small foci of sclerosis and mucoid swelling areas, a fairly high response to glycosaminoglycans and PAS-positive substances remains (Table 9). Perivascular edema in bronchial vessels is moderately expressed.

Taking into consideration the above, we may come to the conclusion that in the course of experimental hyperglycemia the angioprotective effect of dihydroquercetin is quite high. It is known that dihydroquercetin has a beneficial effect on the wall of blood vessels and it increases the resistance of tissues to the

damaging effect of hyperglycemia [Teselkin, Y. O., 1996; Lukyanova, L. D., 2007; Uminskiy, A. A., 2007]. The increase in the period of administration of this drug substance did not lead to a full recovery of structures in the lung, but in this case the nature of the disturbances was less significant and it allowed reducing the level of pathological changes in the respiratory organs.

CHAPTER 5. Biochemical values of peripheral blood and lung tissue of rats in different periods with hyperglycemia in the setting of dihydroquercetin administration

Glycemic parameters of peripheral blood

Studies of the glucose profile in rats were performed in the fasting state in the morning. In each of the experimental groups, all the animals were examined for baseline blood glucose level and further work was carried out individually with each one. The consistent results of changes in the level of the glucose profile were obtained at week 4 of the experiment, when the glucose values were 5.9 ± 0.38 mmol / L (Table 10). At this period of time, in 60 minutes after oral administration of glucose, its level in the blood of rats increased to 11.5 ± 0.85 mmol / L (Table 11). In the course of the following experiment, an increase of glucose level at a period of 8 weeks was noted. This index was 6.4 ± 0.53 mmol / L, which almost twice exceeds its level in intact rats. Animals administered with dihydroquercetin at week 4 had a blood glucose level of 4.5 ± 0.41 mmol / L (5.9 ± 0.58 mmol / L in the control). After oral intake of glucose in 60 minutes, its level was significantly lower than in the control and was 5.8 ± 0.51 mmol / L (Table 11). Dihydroquercetin caused a significant decrease in the blood glucose to 5.2 ± 0.44 mmol / L (in the control 6.4 ± 0.53 mmol / L, Table 10). In the group of animals with experimental hyperglycemia for 16 weeks, changes in blood glucose were as follows: 8 weeks - 6.6 ± 0.61 mmol / L; 12 weeks - 6.9 ± 0.31 mmol / L; 16 weeks - 7.1 ± 0.43 mmol / L (Table 12).

Table 10

The blood glucose indicators of intact rats, with hyperglycemia for 8 weeks and with dihydroquercetin administration (mmol / L)

Duration of the experiment Groups of animals	Hyperglycemia for:			Intact animals
	4weeks	6 weeks	8 4weeks	
Animals with hyperglycemia (control)	5,9 ± 0,38*	6,2 ± 0,37*	6,4 ± 0,53*	3,1 ± 0,24
Animals with hyperglycemia in the setting of dihydroquercetin administration	4,5 ± 0,41**	4,0 ± 0,6**	5,2 ± 0,44**	3,2 ± 0,28

* p< 0,05 in comparison with intact animals

** p< 0,05 in comparison with the control group

Table 11

The blood glucose levels of rats (4th week from the start of the experiment) in the fasting state and 60 minutes after oral intake of glucose (mmol / L)

Groups of animals Levels	Hyperglycemia (control)	Hyperglycemia in the setting of dihydroquercetin administration
In the fasting state	5,9 ± 0,58	4,5 ± 0,41*
60 minutes after	11,5 ± 0,85	5,8 ± 0,51*

* p< 0,05 in comparison with the control group

Table12

Blood glucose levels of intact rats with hyperglycemia for 16 weeks and in the setting of dihydroquercetin administration (mmol / L)

Duration of the experiment Groups of animals	Hyperglycemia for:			Intact animals
	8 weeks	12 weeks	16 weeks	
Animals with hyperglycemia (control)	6,6 ± 0,61*	6,9 ± 0,31*	7,1 ± 0,43*	3,4 ± 0,26

Animals with hyperglycemia in the setting of dihydroquercetin administration	5,3 ± 0,42**	5,7 ± 0,38**	5,8 ± 0,32**	3,2 ± 0,35
--	--------------	--------------	--------------	------------

* p < 0,05 in comparison with intact animals

** p < 0,05 in comparison with the control group

The administration of dihydroquercetin in these periods of time showed that the blood glucose level was significantly lower, by the 16th week of the experiment it was 5.8 ± 0.32 mmol / L.

SUMMARY: Thus, the obtained data testify that under conditions of 8 and 16 weeks of the experiment, sustained hyperglycemia was produced in the body of rats. The administration of dihydroquercetin under these conditions leads to a significant decrease in blood glucose levels at all periods of time.

Oxidative stress and its role in hyperglycemia

Lipid peroxidation (LPO) exists in properly functioning cells, where lipid hydroperoxides are constantly kept in low concentration. It plays an important role in regulating the permeability of cell membranes, the state of cellular oxidative phosphorylation. Under certain conditions, the formation of reactive radical entities increases, which leads to oxidative stress. It has been established that in mechanisms of increasing oxidative stress in diabetes not only hyperglycemia but also hyperinsulinemia is involved [Khrapova, N. G., 1981; Bobyreva L. E., 1996; Balabolkin, M. I., 2000; Zenkov, N. K., 2001; Volchegorskiy, I. A., 2008; Mazo, V.K., 2016; Ciriello, A., 1999; Wu, Z., 2004; Wang, J.Y., 2014]. In healthy tissue, the process of lipid peroxidation, the intensity of which is inversely related to the activity of the natural antioxidant systems, constantly proceeds. Excess formation of reactive oxygen intermediates can cause damage and death of cells. Diene conjugates, which are the primary products of LPO, refer to toxic metabolites that have a damaging effect on lipoproteins, proteins, enzymes and nucleic acids. Further products of LPO are aldehydes and ketones which, with free groups of membrane compounds, form the

final products of LPO (Schiff's base, etc.); their continuous accumulation destabilizes membranes and promotes cell destruction. The unlimited increase in free radicals and hydroperoxides of lipids must have led to the rapid destruction of cellular structures, but under natural conditions this does not occur due to the presence in the body of a complex and multicomponent system of bioantioxidants and natural antioxidants that can chemically inhibit free radical lipid oxidation. The activity of the lipid peroxidation reaction in tissues is controlled by an antioxidant system that provides not only protection against the damaging effect of free radicals, but also has an impact on adaptive responses. However, it should be noted that the negative consequences of lipid peroxidation occur only when there is a depletion of reserves of endogenous antioxidant defense system [Vladimirov, Y. A., 1972; Kagan, V. E., 1979; Gazko, G. G., 1985; Sukhanova, L. Y., 1988; Balabolkin, M. I., 2000; Mazo, V. K., 2014; 91, Wolff, S. P., 1991].

In the absence of antioxidant correction, the level of functioning of protective systems progressively decreases, the level of LPO products reaches a maximum; along with this the hard-disposed secondary compounds (malondialdehyde) predominate in their structure. The reduction of the primary products of LPO, such as diene conjugates, hydroperoxides, due to uncompensated "burning out" of substrates for their formation, can lead to a false conclusion about the well-being in the LPO system - antioxidants [Kagan, V. E., 1979; Ivanov, V. V., 1984; Mazhul, L. M., 1987; Sazonova, O. V., 2000; Romanenko, I. A., 2005; Killebanova, E. M., 2006; Rogovskiy, V. S., 2013].

Vitamin E prevents the formation of end products of LPO, functions as an antioxidant, inhibits lipid peroxidation and eliminates free radicals, including singlet oxygen, which is a powerful oxidant. According to some authors, [Volchegorskiy, I. A., 2008; Gavrovskaya, L. K., 2008; Bondar, I. A., 2009; Paolisso, G., 1993] insulin also inhibits LPO reactions, but this antioxidant effect decreases as the body ages.

In conditions of hyperglycemia, the vascular bed is considered to be the most “favorable” place for inducing free radical oxidation, which is due to the high level of oxygen in the blood, which, as is well-known, appears to be a necessary substrate for the formation of highly reactive compounds. Free radicals damage the cellular structures of the vascular wall, cause desquamation of the endothelium, destruction and fragmentation of the elastic fibers, free radical depolymerization of glycosaminoglycans and the appearance of collagen cross-linking. The prolonged exploration of the products of peroxidation to the components of the vascular wall is accompanied by the development of cellular proliferation with enlargement of connective tissue structures, fibrosis and calcinosis. All this contributes to the thickening of the vascular wall and a decrease in the response to the action of various vasoactive substances, which leads to various circulatory disturbances [Borodin, E. A., 1992; Lyaifer, A. I., 1993; Bobyreva, L. E., 1998; Dedov, I. I., 2003; Balabolkin, M. I., 2008; Ren, S., 2000; Phung, O.J., 2014].

Intensification of lipid peroxidation is of particular importance for the functioning of the respiratory system. Lungs present the largest biological membrane of the body, the external surface of which is constantly in contact with oxygen, as well as with such active initiators of peroxidation as ozone and nitrogen dioxide. Free radical damage of the lungs is characterized not only by ventilatory disorders, but also by hypersecretion of biologically active substances, which leads to inflammatory cell infiltration, increased vascular permeability, edema of tissues, local hypoxia. Ischemia and hypoxia of tissues, observed in diabetes mellitus, are additional factors contributing to the increased formation of reactive oxidants in various organs and tissues. It is unlikely that tissue hypoxia limits free-radical processes; on the contrary, there is a lot of data indicating an increase in lipid peroxidation during hypoxic and ischemic injuries [Vladimirov, Y. A., 1972; Kagan, V. E., 1979; Zenkov, N. K., 2001; Rogovskiy, V.C., 2013; Wolff, S. P., 1991; Ciriello, A., 1999].

Thus, with hyperglycemia, oxidative stress leads to a violation of the balance in the body between pro-oxidants and components of the antioxidant defense system. It causes a different degree of insulin deficiency and the development of insulin resistance, which are considered to be indispensable components of the pathogenesis of vascular complications of diabetes.

The level of reactions of lipid peroxidation (LPO) in hyperglycemia and in the setting of dihydroquercetin administration

In peripheral blood

Experimental 8-week hyperglycemia in peripheral blood of rats showed a prominent and significant increase in the content of most LPO products, especially diene conjugates (up to 81.6 ± 4.04 nmol / L) and ceruloplasmin (up to $30,4 \pm 2,1$ mg / 100 ml). In intact animals, these indices were respectively 18.6 ± 0.38 nmol / ml and 18.4 ± 0.37 mg / 100ml. The level of vitamin E decreased and was 27.8 ± 0.62 μ g / ml, whereas in intact ones it was 32.5 ± 0.57 μ g / ml (Table 13).

The administration of dihydroquercetin in the course of the experiment leads to a significant and prominent reduction in the diene conjugate parameters to 68.8 ± 2.03 nmol / ml, malondialdehyde to 4.1 ± 0.38 nmol / ml in the setting of an increase of vitamin E to $30.8 \pm 0,43$ μ g / ml. At week 16 of experimental hyperglycemia, a high level of LPO products was preserved in the blood of rats, although the content of diene conjugates was lower than in the previous experiment and was 52.8 ± 39 nmol / ml. Vitamin E was reduced to 24.6 ± 0.67 μ g / ml (in intact - 31.7 ± 0.48 μ g / ml, Table 14). Dihydroquercetin at 16 weeks of hyperglycemia reduced the level of LPO reactions, as evidenced by the diene conjugate indices - 42.7 ± 2.68 nmol / ml and hydroperoxides - 21.9 ± 0.42 nmol / ml. The vitamin E content was increased to 28.4 ± 0.36 μ g / ml.

SUMMARY: Thus, hyperglycemia, both during 8 weeks and 16 weeks, leads to an increase in the peripheral blood of primary, as well as secondary products of LPO, in the setting of this the content of vitamin E decreases. The administration of dihydroquercetin during 8 weeks, and especially 16 weeks, revealed a significant

decrease in the level of LPO reaction, in the setting of increased antioxidant defence.

Table13

Biochemical blood indices of intact rats, with hyperglycemia for 8 weeks and in the setting of dihydroquercetin administration

Groups of animals	Intact	Hyperglycemia for 8 weeks (control)	Hyperglycemia for 8 weeks in the setting of dihydroquercetin administration
Indices			
Diene conjugates, nmol / ml	18,6 ± 0,38	81,6 ± 4,04*	68,8 ± 2,03**
Hydroperoxides, nmol / ml	21,7 ± 0,42	26,8 ± 1,12*	28,4 ± 1,4
Malondialdehyde, nmol / ml	3,1 ± 0,17	5,6 ± 0,37*	4,1 ± 0,38**
Ceruloplasmin, mg / 100ml	18,4 ± 0,37	30,4 ± 2,11*	32,1 ± 1,17
Vitamin E, µg / ml	32,5 ± 0,57	27,8 ± 0,62*	30,8 ± 0,43

* p< 0,05 in comparison with intact animals

** p< 0,05 in comparison with the control group

Table14

Biochemical blood indices of intact rats, with hyperglycemia for 16 weeks and in the setting of dihydroquercetin administration

Groups of animals	Intact	Hyperglycemia for 16 weeks (control)	Hyperglycemia for 16 weeks in the setting of dihydroquercetin administration
Indices			
Diene conjugates, nmol / ml	17,4 ± 0,44	52,8 ± 3,09*	42,7 ± 2,68**
Hydroperoxides, nmol / ml	22,4 ± 0,51	24,3 ± 0,72	21,9 ± 0,42**
Malondialdehyde, nmol / ml	3,3 ± 0,31	4,75 ± 0,54*	3,9 ± 0,27
Ceruloplasmin, mg / 100ml	31,7 ± 0,48	24,6 ± 0,67*	28,4 ± 0,36**

* p< 0,05 in comparison with intact animals

** p< 0,05 in comparison with the control group

In the lung tissue

In conditions of hyperglycemia, statistically significant activation of LPO processes in lung tissue is observed. This can be judged from the increase in the content of lipid peroxidation products already at week 8 of the experiment - diene conjugates increase to 77.4 ± 1.45 nmol / g; hydroperoxides up to 35.9 ± 2.1 nmol / g (for intact these parameters are respectively equal to 53.8 ± 0.33 nmol / g and 21.1 ± 0.54 nmol / g). It should be noted that the amount of vitamin E practically does not change (Table 15). The administration of dihydroquercetin during this experiment led to a significant decrease in the content of primary LPO products, namely, diene conjugates up to 59.8 ± 1.19 nmol / g and an increase in vitamin E to 45.9 ± 0.41 μ g / g, with hyperglycemia in the control its content was 40.3 ± 0.87 μ g / g. An increase in the duration of the experiment with hyperglycaemia to 16 weeks maintained the high activity of LPO reactions, which is indicated by fairly high indices of diene conjugates - 61.9 ± 1.47 nmol / g, hydroperoxides - 31.7 ± 1.82 nmol / g, in intact animals the content of these substances was accordingly equal to - 49.1 ± 0.42 nmol / g and 19.4 ± 0.65 nmol / g. The low level of vitamin E is indicative of a decrease in the level of antioxidant defence - 37.4 ± 1.75 μ g / g, in intact ones it was equal to - 43.71 ± 1.07 μ g / g (Table 16). The administration of dihydroquercetin under conditions of 16-week hyperglycemia led to a statistically significant decrease in the products of LPO reactions and an increase in the antioxidant defence index. This is evidenced by a decrease in the indices of diene conjugates to 48.7 ± 1.04 nmol / g, hydroperoxides to 21.3 ± 0.81 nmol / g and an increase in vitamin E to 44.4 ± 0.79 μ g / g with the administration of dihydroquercetin.

SUMMARY: Thus, experimental hyperglycemia leads to the activation of LPO reactions, as evidenced by an increase of diene conjugates in the tissue of the lung, hydroperoxides of lipids and a decrease in vitamin E. The level of LPO reactions depends on the duration of the experiment. The administration, under the conditions of the activation of the reactions of lipid peroxidation, of dihydroquercetin allows reducing the intensity of these processes, activating the

antioxidant system, and preventing excessive accumulation of peroxidation products in the lung. It should be noted that dihydroquercetin more actively affects the accumulation of vitamin E in the lung tissue.

Table 15

Biochemical indices of intact rat tissue, with hyperglycemia for 8 weeks and in the setting of dihydroquercetin administration

Indices	Intact	Hyperglycemia for 8 weeks (control)	Hyperglycemia for 8 weeks in the setting of dihydroquercetin administration
Diene conjugates, nmol / ml	53,18 ± 0,33	77,4 ± 1,45*	59,8 ± 1,19**
Hydroperoxides, nmol / ml	21,1 ± 0,54	35,9 ± 2,1*	34,8 ± 1,72
Vitamin E, µg / g	42,65 ± 1,08	40,3 ± 0,87	45,9 ± 0,41**

* p < 0,05 in comparison with intact animals

** p < 0,05 in comparison with the control group

Table 16

Biochemical indices of intact rat tissue, with hyperglycemia for 16 weeks and in the setting of dihydroquercetin administration

Indices	Intact	Hyperglycemia for 16 weeks (control)	Hyperglycemia for 16 weeks in the setting of dihydroquercetin administration
Diene conjugates, nmol / ml	49,1 ± 0,42	61,9 ± 1,47*	48,7 ± 1,04**
Hydroperoxides, nmol / ml	19,4 ± 0,65	31,7 ± 1,82*	21,3 ± 0,81**
Vitamin E, µg / g	43,71 ± 1,07	37,4 ± 1,75*	44,4 ± 0,79**

* p < 0,05 in comparison with intact animals

** p < 0,05 in comparison with the control group

In our work, when creating sustained and long-term experimental hyperglycemia, morphological and biochemical disturbances were found, similar to those observed in patients with type 2 diabetes mellitus. Hyperglycemia is the result of a metabolic disorder, in which the level of dietary carbohydrates exceeds their consumption by organs and tissues. In this case, glucose has a long and uncontrolled

effect on various cell structures, which leads to the development of glucose toxicity [Baranov, V. G., 1965; Williams, G., 2003; Bensellam, M., 2009]. One of the phenomena of this process is the activation of peroxide oxidation of glucose, as well as lipids and proteins, which is accompanied by an increase in the level of extremely reactive free radicals. In addition, the state of hyperglycemia leads to the fact that individual links of the body's antioxidant defense system do not cope with the increased load.

Such a disturbance of the balance of oxidative processes and an increase in uncontrolled free radical reactions due to hyperglycemia are sometimes called oxidative stress, which is particularly detrimental to the cells and tissues of the body [Vladimirov, Y. A., 1972; Ivanov, V. V., 1984; Mazovetskiy, A. G., 1987; Lyaifer, A. I., 1993; Ciriello, A., 1999]. One of the main criteria in choosing the model of experimental hyperglycemia was the absence of direct detrimental effect or the occurrence of significant metabolic disturbances of B cells of pancreatic islets. In addition, it should be taken into consideration that the absorption of glucose from the gastrointestinal tract leads to the greatest stimulation of B cells, active secretion of insulin, which ultimately can lead to depletion or a decrease in the functional activity of islet cells of pancreatic islets [Baranov, V. G., 1983; Mazovetskiy, A. G., 1987; Balabolkin, M. I., 1994; Shestakova, E.A. 2012]. It has been known that in patients with type 2 DM, the secretion of insulin with food intake is reduced, and sometimes there is no insulin response at all. A number of studies have shown that in the setting of hyperglycemia, the ability of insulin to stimulate the glucose uptake by means of peripheral tissues is reduced [Baranov, V. G., 1965; Ametov, A. S., 2002; Dedov, I. I., Melnichenko, T. A., 2008]. Taking in consideration the above, in our work we used various ways of introducing glucose solution into the body of experimental animals: oral and parenteral (intraperitoneal). The most clear and statistically significant data were obtained in the study of fasting blood glucose levels of rats. In the course of the experiment, a "peak" increase in glucose levels was detected

already 60 minutes after its administration. With the extension of the experimental period, there was a clear tendency to the increase of the blood glucose concentration, which indicates the development of hyperglycemic syndrome in experimental animals. The level of glucose in the blood is indicative of the state of two constantly changing processes that are under the control of insulin: the utilization of glucose by the tissues and the intake of glucose into the bloodstream. The consistent results were obtained at the 4th week of the experiment, when blood glucose levels increased in 2 times in comparison with intact animals. During this period, the oral administration of glucose in rats resulted in a rapid increase in blood content in 60 minutes, which is somewhat similar to postprandial hyperglycemia (hyperglycemia after eating) in patients with type 2 DM.

It is considered that this is an important pathogenetic factor in the development of angiopathies and it occurs as a result of the fallout of the early phase of insulin secretion [Mkrtumyan, A. M., 2002; Balabolkin, M. I., 2004]. During the further extension of the experiment to 16 weeks, there was a clear tendency to the increase of blood glucose level. Thus, an increase in blood glucose level intensifies the state of insulin resistance and, possibly, leads to a decrease in the susceptibility of B cells, thereby causing disinsulinism, which leads to the formation of a vicious circle: increasing glucose levels intensifies insulin resistance, and this contributes to the development of even more pronounced hyperglycemia [Mazovetskiy, A. G., 1987; Dmitriev, L. F., 2005; Ametov, A. S., 2008; Francini, F., 2001].

Evaluation of the glycemetic profile in experimental rats made it possible to reveal regularity in the growth of blood glucose content with an increase in the duration of the experiment. The most significant increase of this indicator occurred during the first 4-8 weeks. Further, at a period of 12-16 weeks, there was some stabilization, but the blood glucose level in rats in the fasting state was constantly almost 2 times higher than in intact animals. This allowed suggesting about the

development of hyperglycemic syndrome during the experiment. The administration of dihydroquercetin allowed lowering the level of glucose, but the indices remained elevated and this tendency persisted during all the periods of the experiment. The positive thing is that the “peak” rise of blood glucose 60 minutes after its oral intake was significantly lower than in the setting of hyperglycemia.

It is known that the intensity of the LPO reaction and the state of the antioxidant system are among the most significant in the development of complications in DM [Mazhul, L. M., 1987; Bobyрева, L. E., 1996; Balabolkin, M. I., 2000; Sazonova, O. V., 2000; Mazo, V.K., 2016; Ciriello, A., 1999]. With hyperglycemia at a period of 8 weeks, there is a significant increase in the peripheral blood of diene conjugates, malondialdehyde in the setting of a decrease in the concentration of vitamin E. In the lung tissue, the content of hydroperoxides increases significantly. The activation of LPO reactions is observed at all levels. When the experiment is extended to 16 weeks, in the peripheral blood the above-described regularity is preserved. In the lung tissue in the setting of an increase in the content of diene conjugates and hydroperoxides, there is a significant decrease in vitamin E. The state of hyperglycemia leads to a decrease in the level of antioxidant defence in the setting of the intensification of LPO reactions, namely, the excessive formation of reactive oxygen intermediates that can cause damage and death of cells in the pancreas and lung [Khrapova, N. G., 1981; Zenkov, N. K., 2001; Veneman, T.F., 2012].

The administration of dihydroquercetin during 8-week hyperglycemia leads to a significant decrease in diene conjugates (although their level is quite high), malondialdehyde and an increase in the concentration of vitamin E. In lung tissue, the level of diene conjugates decreases in this experiment, the content of vitamin E increases, but a sufficiently high level of hydroperoxides is maintained. In other words, despite the positive dynamics of the reaction of LPO in the lung tissue, the increased activity of free radical oxidation is preserved and it is likely that the

release of oxidation products into the total blood flow occurs from the lung. Elongation of hyperglycemia to 16 weeks and the administration of dihydroquercetin somewhat reduces the level of diene conjugates in the peripheral blood and lung tissue in the setting of an increase in vitamin E. It should be noted that the content of diene conjugates in blood is significantly higher than that in intact animals, and although these substances are classified as primary products of LPO, they are toxic metabolites that have a damaging effect on proteins, enzymes, lipoproteins and nucleic acids [Ivanov, V. V., 1984; Lyaifer, A. I., 1993; Zenkov, N. K., 2001; Romanenko, I. A., 2005]. Perhaps this is one of the factors that is involved in the development of microangiopathies. Therefore, the administration of dihydroquercetin, which in addition to the antioxidant effect has a beneficial effect on the morphology of the vascular wall, is fully justified. Vitamin E inhibits LPO reactions and removes free radicals, i.e. it is a natural antioxidant and the growth of its content in lung tissue with hyperglycemia makes it possible to evaluate the administration of medications as a positive fact.

Conclusion

The aim of this research was to study the morphofunctional state of pancreatic and lung islets in experimental hyperglycemia and to evaluate the efficacy of the antioxidant drug substance - dihydroquercetin.

To carry out this study, a model of experimental long-term hyperglycemia was created by means of combining the intake of glucose solution into the body of rats - orally and parenterally. The main difference of the model was that the necessary degree of severity of hyperglycemia was reached, direct toxic effect on islet cells of pancreatic islets was avoided, and oral administration provided an active stimulating effect on B cells.

The complex study made it possible to reveal the stage-by-stage development of structural changes in B cells, vessels of the microcirculatory bloodstream of pancreatic islets during hyperglycemia at various times. A detailed electron microscopic description of the morphological changes in B cells in hyperglycemia was carried out. It is shown that as the duration of the experiment is extended, dystrophic changes in B-islet cells increase, structural changes in the vessels of the microcirculatory bloodstream and in the connective tissue layers of the islets of the pancreas increase.

The dynamics of morphological changes in the lung is shown in the course of the lengthening of the experiment, which was developed by the appearance of a symptom complex typical for type 2 DM, namely pericapillary and interstitial edema, emphysema, alveolar macrophage accumulations, perivascular formations of the "granuloma" type, thickening of the basement membranes of capillaries.

The data obtained allowed us to objectively estimate the effectiveness of the antioxidant drug used any further and come to the following conclusion that

dihydroquercetin shows pronounced antioxidant characteristics, lowers the level of LPO reaction, activates antioxidant defence, reduces the rate of increase in structural changes in pancreatic and lung islets resulting from hyperglycemia.

Thus, the antioxidant drug, normalizing the level of free radical oxidation reduces the destructive changes and damage to cells and tissues of the body in conditions of hyperglycemia. Taking into consideration the fact that dihydroquercetin reduces the level of metabolic and structural changes in the setting of sustained hyperglycemia, it can be recommended as a drug of pathogenetic treatment to enhance baseline therapy with hypoglycemic agents, in order to reduce the likelihood of early development of complications, in particular, angiopathies arising in the setting of carbohydrate metabolism disorder [Teselkin, Y. O., 1996; Uminskiy, A. A., 2007; Chernikova, N.A., 2010; Mazo, V.K., 2014; Blinkova, T.M., 2015].

According to many authors, diabetes mellitus type 2 is impossible to cure [Balabolkin, M. I., 1994; Nedosugova, L. V., 2004; Smolyanskiy, B. L., 2004; Zhestovskiy, S. S., 2007; Gavrovskaya, L. K., 2008]. But this disease can be controlled and patients will remain the ability to work and feeling of well-being for many years. The main thing in this case is the systematic monitoring of metabolism, which allows eliminating the symptoms of hyperglycemia and the use of drugs that prevent the development of vascular complications. Morphological substantiation of the structural changes that arise in the pancreas and lungs in carbohydrate metabolism disorder in the body made it possible to study in detail possible mechanisms for correcting this condition, to justify the use of medications in order to facilitate the course of such a disease as type 2 diabetes mellitus.

References

1. Avcyn, A. P. *Ultrastrukturnye osnovy patologii kletki*[Ultrastructural foundations of Cell Pathology]/ A. P. Avcyn, V. A. Shahlamov. - M.:Medtsina Publ., 1979. 316p.
2. Aleksandrov, A. A. *β -Blokatory i saharnyj diabet*[Beta-blockers and diabetes mellitus] / A. A. Aleksandrov // *Russ. medicinskiy zhurnal* [Rus. Medicaljournal]. - 2004. - Vol. 12, no. 15, pp. 953-956.(in Russian)
3. Ametov, A. S. *Insulinosekreציya i insulinorezistentnost: dve storony odnoy medalı* [Insulin secretion and insulin resistance: two sides of the same coin] / A. S. Ametov // *Problemy endokrinologii* [Problems of endocrinology]. - 2002. -Vol. 48, no. 3, pp. 31-37. (in Russian)
4. Ametov, A. S. *Perspektivy razvitiya diabetologii*[Further development of diabetology] / A. S. Ametov// *Terapevt. Arhiv* [Therap. archive]. - 2005. - No.10, pp. 5-9.(in Russian)
5. Ametov, A. S. *Rol B-kletok v regulyacii gomeostaza gljukozy v norme i pri saharnom diabete 2 tipa* [The role of B cells in the regulation of glucose homeostasis in norm and in type 2 diabetes mellitus]/ A. S. Ametov// *Saharnyy diabet* [Diabetes mellitus]. - 2008. - N. 41. - No. 4, pp. 6-11.(in Russian)
6. Androsova, O.G. *Vliyanie digidrokvercetina na perekisnoe okislenie lipidov pri holodovom vozdeystvii: Avtoref. kand. med. nauk* [The effect of dihydroquercetin on lipid peroxidation during cold exposure: Author's abstract Candidate of Medical Sciences] : / O.G. Androsova // Vladivostok.- 2014. 22p.
7. Balabolkin, M. I. *Saharnyydiabet* [Diabetesmellitus] / M. I. Balabolkin. - M.:MeditsinaPubl., 1994. 384p.
8. Balabolkin, M. I..*Rol okislitel'nogo stressa v patogeneze sosudistykh oslozhnenij diabeta: lekciya* [The role of oxidative stress in the pathogenesis of vascular complications of diabetes: a lecture] / M. I. Balabolkin, E. M. Klebanova // *Problemy endokrinologii* [Problems of endocrinology]. - 2000. - Vol. 46, no6, pp. 29-34.(in Russian)
9. Balabolkin, M. I. *Novaya klassifikaciya, kriterii diagnostiki i kompensacii saharnogo diabeta*[New classification, criteria for diagnosis and compensation of diabetes mellitus]/ M. I. Balabolkin, E. M. Klebanova, V. M. Kreminskaja // *Consiliummedicum*. - 2000. - vol.2, no.5, pp. 204-210.(in Russian)
10. Balabolkin, M. I. *Mikroangiopatiya – odno iz sosudistykh oslozhneniy*

- saharnogo diabeta* [Microangiopathy is one of the vascular complications of diabetes mellitus] / M. I. Balabolkin, E. M. Klebanova, V. M. Kreminskaja // *Consiliummedicum*. – 2000. – Vol. 2, no. 5, pp. 215-220.(in Russian)
11. Balabolkin, M. I. *Rol insulinorezistentnosti v patogeneze saharnogo diabeta tipa 2* [The role of insulin resistance in the pathogenesis of type 2 diabetes mellitus] / M. I. Balabolkin, E. M. Klebanova // *Terapevt. Arhiv* [Therap. archive]. - 2003. - No. 1, pp. 72-77.(in Russian)
 12. Balabolkin, M. I. *Vozmozhna li patogeneticheskaya terapiya saharnogo diabeta vtorogo tipa* [Is pathogenetic therapy possible for type 2 diabetes mellitus] / M. I. Balabolkin, E. M. Klebanova, V. M. Kreminskaya // *Problemy endokrinologii* [Problems of endocrinology]. - 2008. – No. 5, pp. 50-56.(in Russian)
 13. Balabolkin, M. I. *Rol disfunkcii endotelija i oksidativnogo stressa v mehanizmah razvitiya angiopatii pri SD 2 tipa* [The role of endothelial dysfunction and oxidative stress in the mechanisms of angiopathy in type 2 DM] / M. I. Balabolkin, E. M. Klebanova, V. M. Kreminskaya // *Kardiologija* [Cardiology]. - 2004. –No. 7, pp. 90-97.(in Russian)
 14. Balabolkin, M. I. *Primenenie antioksidantov iz gruppy flavonoidov v lechenii diabeticheskoy retinopatii pri saharnom diabete tipa 2* [The administration of antioxidants from the flavonoid group in the treatment of diabetic retinopathy in type 2 diabetes mellitus] / M. I. Balabolkin, N. S. Nikishova, A. K. Volkova, L. V. Nedosugova, M. F. Belojarceva, M. V. Zueva, I.V. Capenko, A. S. Beglyarov, I.A. Rudko // *Problemy endokrinologii* [Problems of endocrinology]. - 2003. - Vol.49, no. 3, pp. 3–6.(in Russian)
 15. Baranov, V. G. *Eksperimentalnyy saharnyy diabet* [Experimental diabetes mellitus] / V. G. Baranov. - L.: Nauka Publ., 1983. 238p.
 16. Baranov, V. G. *Model skrytogo eksperimentalnogo saharnogo diabeta u krysov i faktory, blagoprijatstvujushhie perevodu ego v yavnyy diabet* [The model of latent experimental diabetes mellitus in rats and factors conducing to its transformation into overt diabetes] / V. G. Baranov, I. M. Sokoloverova // *Problemy endokrinologii* [Problems of endocrinology]. – 1965. – No. 2, pp. 50-56.(in Russian)
 17. Barabanov, V.M., Gulimova, V.I., Fokin, E.I., Savelev, S.V. *Morfologicheskaya i immunogistohimicheskaya harakteristika jendokrinykh kletok i neyrallykh struktur podzheludochnoj zhelezy u podrostka s saharnym diabetom* [Morphological and immunohistochemical characteristics of endocrine cells and neural structures of the pancreas in adolescents with diabetes mellitus] / V.M.Barabanov, V. I. Gulimova, E. I. Fokin, S. V. Savelev // *Klin. i eksper. morfol* [Clinic. and exp. morfol.]- 2014.- No. 2, pp. 4-8.(in Russian)
 18. Bashkirova, J. V. *Endotelialnaya disfunkciya i mikrocirkuljatornye narusheniya u bolnykh saharnym diabetom 2 tipa* [Endothelial dysfunction and

- microcirculatory disorders in patients with type 2 diabetes mellitus]/ J. V. Bashkirova [etal.] // *Bulleten SO RAMN* [Bulletin of the RAS Siberian branch]. - 2008. – No. 6, pp. 182-186. (in Russian)
19. Bizjuk, L.A., Korolevich, M.P. *Antioksidant digidrokvercetin: kliniko-farmakologicheskaya effektivnost i puti sinteza* [Antioxidant dihydroquercetin: clinical pharmacological efficacy and synthesis routes] / L.A. Bizjuk, M.P. Korolevich // *Lechebnoe delo: nauchno-prakticheskij terapevticheskij zhurnal* [General Medicine: research and practice therapeutic journal]. - 2013. – Vol.29, no.1, pp. 13-19.(in Russian)
 20. Bityutskaya, L. G. *Antioksidanty pri jeksperimental'noj giperglikemii: Avtoref. kand. med. nauk* [Antioxidants in experimental hyperglycemia Author's abstract Candidate of Medical Sciences] : / L.G. Bityutskaya. – Vladivostok, 2005. 20 p.
 21. Blinkova, T.M., Polyakova E.D. *Issledovanie ingredientnogo sostava obogatitelya rastitelnogo pishhevogo diabeticheskogo naznacheniya.* [Investigation of the ingredient composition of a vegetable diabetic nutrient enrichment agent.] / T.M. Blinkova, E.D. Polyakova // *Tehnologiya i tovarovedenie innovacionnyh pishhevyh produktov* [Technology and Commodity Research of innovative food products.]- 2015. - Vol. 32, no.3, pp. 50-56.(in Russian)
 22. Bobyreva, L. E. *Antioksidanty v kompleksnoj terapii diabeticheskikh angiopatii* [Antioxidants in the complex therapy of diabetic angiopathies] / L. E. Bobyreva // *Ekspierimentalnaya i klinicheskaya farmakologiya* [Experimental and Clinical Pharmacology]. - 1998. - Vol.61, no. 1, pp. 74-80.(in Russian)
 23. Bobyreva L. E. *Svobodnoradikalnoe okislenie, antioksidanty i diabeticheskie angiopatii* [Free radical oxidation, antioxidants and diabetic angiopathy] / L. E. Bobyreva // *Problemyendokrinologii* [Problemsofendocrinology]. - 1996. – No. 6.(2), pp. 14-18.(in Russian)
 24. Borodin, E. A. *Perekisnoe okislenie lipidov v membranaheritocitov i mikrosom pecheni i antiokislitel'naja sistema tkanej krysv pri dlitel'nom dejstvii holoda* [Peroxide oxidation of lipids in erythrocyte membranes and liver microsomes and the antioxidant system of the tissues of rats with prolonged exposure to cold] / E. A. Borodin, G. P. Borodina, V. A. Dorovskih // *Biologicheskie membrany* [Biological membranes]. - 1992. - Vol.9, no. 6, pp. 622-627.(in Russian)
 25. Bondar, I. A. *Antioksidant dibikor v lechenii sosudistyh oslozhneniy saharnogo diabeta 2-go tipa* [Antioxidant dibicor in the treatment of vascular complications of type 2 diabetes mellitus]/ I. A. Bondar', O. Ju. Shabel'nikova, A. R. Alina // *Problemyendokrinologii* [Problemsofendocrinology]. - 2009. – No.2, pp. 41-45. (in Russian)

26. Bregovskiy, V. G. *Hronicheskie oslozhneniya saharnogo diabeta 2-go tipa* [Chronic complications of type 2 diabetes mellitus] / V. G. Bregovskiy, F. E. Shadrichiev // *Aguavitae*. - 2001. –No.1, pp. 46-51.
27. Vesnina, I. A. *Differencirovka i citogenez endokrinocitov podzheludochnoy zhelezy beloy krsy v usloviyah dlitel'nogo golodaniya*[Differentiation and cytogenesis of white pancreatic pancreatic endocrinocytes in conditions of prolonged fasting] / I. A. Vesnina // *Morfologiya* [Morphology]. - 2001. – No. 6, pp. 56-62. (in Russian)
28. Veybel, E. R. *Morfometriya legkih cheloveka* [Morphometry of the human lungs] / E. R. Vejbel. - M.: Meditsina Publ., 1970. 176p.
29. Vladimirov, J. A. *Perekisnoe okislenie lipidov v biologicheskikh membranah* [Peroxide oxidation of lipids in biological membranes] / J. A. Vladimirov, A. I. Archakov. - M.: Nauka Publ., 1972. 252p.
30. Volchegorskiy, I. A. *Antioksidanty pri eksperimentalnom saharnom diabete*[Antioxidants in experimental diabetes mellitus] / I. A. Volchegorskiy, L. M. Rassohina, I. J. Miroshnichenko // *Problemy endokrinologii* [Problemsof endocrinology]. - 2008. – No.5, pp. 43-49. (in Russian)
31. *Vozobnovlenie populyatsii insulinproducirovushchih beta-kletok podzheludochnoy zhelezy za schet deleniya samih kletok, a ne blagodarya vzroslym stvolovym kletkam, kak predpolagalos ranee*[Renewal of the population of insulin-producing beta cells of the pancreas by dividing the cells themselves, rather than through adult stem cells, as previously thought] // Online magazine "Commercial Biotechnology" –Available at: <http://www.cbio.ru/> (Accessed 11 May 2007).
32. Gavrovskaya, L. K. *Vliyanie taurina i tioktatsina na uglevodnyy obmen i antioksidantnuyu sistemu pri eksperimentalnom saharnom diabete* [Effect of taurine and tiointacin on carbohydrate metabolism and antioxidant system in experimental diabetes mellitus] / L. K. Gavrovskaya, N. S. Saprionov // *Eksperimentalnaya i klinicheskaya farmakologiya* [Experimental and Clinical Pharmacology]. - 2008. – No. 3, pp. 34-35. (in Russian)
33. Gavrovskaya, L. K. *Sovremennyye podhody k terapii saharnogo diabeta* [Modern approaches to the therapy of diabetes mellitus] / L. K. Gavrovskaya, O. V. Ryzhova, N. S. Saprionov // *Med. akademicheskii zhurn.* [Medical academic journal]. - 2008. – No. 4, pp. 33-41.(in Russian)
34. Galenok, V. A. *Gipoksiya i uglevodnyy obmen* [Hypoxia and carbohydrate metabolism] / V. A. Galenok, V. N. Dikker. – Novosibirsk: Nauka Publ., 1985. 194 p.
35. Galstyan, G. R. *Vliyanie amilina na funktsii V-kletok i regulatsiyu uglevodnogo obmena* [Influence of amylin on B-cell function and regulation of carbohydrate metabolism] / G. R. Galstyan // *Sakharnyy diabet* [Diabetes Mellitus]. - 2008. – N.41. – No. 4, pp. 24-25.(in Russian)

36. Galstyan, G. R. *Khronicheskiye oslozhneniya sakharnogo diabeta: etiopatogenez, klinika, lecheniye* [Chronic complications of diabetes mellitus: etiopathogenesis, clinical findings, treatment]/G. R. Galstyan// *Russkiy meditsinskiy zhurnal* [Russian Medical Journal]. - 2002. - Vol. 10, No.27, pp. 1266–1269.(in Russian)
37. Gayer, G. *Elektronnaya gistokhimiya* [Electronic histochemistry]: translation from English/ G. Gayer. - M.:Mir Publ., 1974. 488 p.
38. Gatsko, G. G. *Vozrastnyye osobennosti perekisnogo okisleniya lipidov v krovi pri alloksanovom diabete* [Age features of lipid peroxidation in blood under alloxan diabetes] / G. G. Gatsko. L. M. Mashul. O. V. Shablinskaya // *Problemy endokrinologii* [Problems of endocrinology]. – 1985. – No. 2, pp. 68–70.(in Russian)
39. Geller, L. I. *Patologiya vnutrennikh organov pri sakharnom diabete* [Pathology of internal organs in diabetes mellitus] / L. I. Geller. - M.:Meditsina Publ., 1975. 132 p.
40. Gendeleka, G. F. *Znachenkiye kompensatsii sakharnogo diabeta v razvitii diabeticheskikh mikroangiopatii* [Value of compensation for diabetes mellitus in the development of diabetic microangiopathies]/ G. F. Gendeleka // *Vrachebnoye delo* [Medical Practice]. - 1989. – No. 8, pp. 54-58. (in Russian)
41. Genyk, S. N. *Patogenez diabeticheskikh angiopatii* [Pathogenesis of diabetic angiopathies]/ S. N. Genyk. V. S. Shevchuk. V. R. Pidufalyy. G. M. Karas // *Vrachebnoye delo* [Medical Practice]. - 1989. – No. 2, pp. 1-5.(in Russian)
42. Glants, S. *Mediko-biologicheskaya statistika* [Medico-biological statistics] / S. Glants. - Translation from English. - M.:Praktika Publ., 1998. 459 p.
43. Goldberg, E. D. *Sostoyaniye pulov stvolovykh kletok pri eksperimentalnom SD* [The condition of stem cell pools under experimental DM]/ E. D. Goldberg. A. M. Dygay. V. V. Zhdanov. G. N.Zyuzkov. T.I. Fomina. T.I. Ermolayeva. L.A. Guriantseva. T.Yu. Khrichkova // *Kletochnyye tekhnologii v biologii i meditsine* [Cell technologies in biology and medicine]. - 2006. – No. 3, pp. 123-126.(in Russian)
44. Gorbenko, N. I. *Sovremennyye aspekty farmakologicheskoy korrektsii giperglikemii u bolnykh insulinnezavisimym sakharnym diabetom (tip 2)* [Modern aspects of pharmacological correction of hyperglycemia in patients with insulin-dependent diabetes mellitus (type 2)] / N. I. Gorbenko // *Eksperimentalnaya i klinicheskaya farmakologiya* [Experimental and Clinical Pharmacology]. - 1999. - Vol. 62, No. 5, pp. 71-78.(in Russian)
45. Gordiyenko. V. M. *Ultrastruktura zhelez endokrinnoy*

- sistemy*[Ultrastructure of the glands of the endocrine system] / V. M. Gordiyenko. V. G. Kozyritskiy. - Kiev: Zdoroviya Publ., 1978, pp. 108-128.
46. Gordyunina S.V. Insulinorezistentnost i regulyatsiya metabolizma [Insulin resistance and regulation of metabolism] / S.V. Gordyunina // *Problemy endokrinologii* [Problems of endocrinology]. - 2012.- No. 3, pp. 31-34.(in Russian)
 47. *Sakharnyy diabet: angiopatii i okislitelnyy stress: Posobiye dlya vrachey* [Diabetes mellitus: angiopathy and oxidative stress: A manual for physicians] / I. I. Dedova. M. I. Balabolkina. G. G. Mamayeva et al. - M.:MeditsinaPubl., 2003. 85 p.
 48. Dedov, I. I. *Sakharnyy diabet, etiologiya, patogenez, rasprostranennost sredi naseleniya* [Diabetes mellitus, etiology, pathogenesis, prevalence among the population] / I. I. Dedov. M. I. Balabolkin // *Meditsinskiy akademicheskiy zhurnal* [Medical Academic Journal]. - 2006. – No. 6, pp. 3-15.(in Russian)
 49. Dedov, I. I. *Vliyaniye antioksidantov na sostoyaniye perekisnogo okisleniya lipidov i funktsiyu V-kletok u bolnykh s vpervye vyyavlyennym insulinzavisimym sakharnym diabetom*[Influence of antioxidants on the state of lipid peroxidation and B-cell function in patients with newly diagnosed insulin-dependent diabetes mellitus] / I. I. Dedov. V. A. Gorelysheva. O. M. Smirnova. G. A. Romanovskaya. A. I. Filippov // *Problemy endokrinologii* [Problems of endocrinology]. - 1992 – No. 6, pp. 16-20.(in Russian)
 50. Dedov, I. I. *Svobodnoradikalnoye okisleniye i antioksidantnaya zashchita pri sakharnom diabete: Posobiye dlya vrachey*[Free radical oxidation and antioxidant protection in diabetes mellitus: A manual for Physicians] / I. I. Dedov. - M.: Meditsina Pibl., 2003. 40 p.
 51. Dedov. I. I. *Sakharnyy diabet i arterialnaya gipertenziya*[Diabetes mellitus and arterial hypertension] / I. I. Dedov. M. V. Shestakova. – M.: MeditsinaPubl.,2006.343 p.
 52. Dedov. I. I. *Kommentarii k konsensusnomu algoritmu Amerikanskoy Diabeticheskoy Assotsiatsii i Evropeyskoy assotsiatsii po izucheniyu sakharnogo diabeta: «Medikamentoznaya korrektsiya giperqlikemii pri sakharnom diabete 2 tipa»* [Comments on the consensus algorithm of the American Diabetes Association and the European Association for the Study of Diabetes Mellitus: "Medication correction of hyperglycemia in type 2 diabetes mellitus"] / I. I. Dedov. M. V. Shestakova. O. K. Vikulova // *Sakharnyy diabet* [Diabetes Mellitus]. – 2009. – No. 2, pp. 77–82.(in Russian)
 53. Demidova, I. Y. *Sakharnyy diabet 2 (patogenez i lecheniye)* [Diabetes mellitus 2 (pathogenesis and treatment)] / I. Y. Demidova. I. V. Glinkina. A. N. Perfilova // *Consiliummedicum*. – 2000. – Vol.2, No. 5, pp. 211-214.(in Russian)
 54. Dmitriyev, L. F. *Mekhanizmy razvitiya giperqlikemii i vozmozhnyye*

- sposoby normalizatsii uglevodnogo obmena (obzor)* [Mechanisms of development of hyperglycemia and possible ways of normalization of carbohydrate metabolism (review)] / L. F. Dmitriyev. S. F. Dugin // *Terapevticheskiy arkhiv* [Therapeutic archive]. - 2005. – No. 10, pp. 24-29.(in Russian)
55. Dorovskikh, V. A. *Antioksidantnaya aktivnost proizvodnykh malonovoy kisloty* [Antioxidant activity of malonic acid derivatives] / V. A. Dorovskikh. E. V. Zrazhevskaya. E. A. Borodin // *Eksperimentalnaya i klinicheskaya farmakologiya* [Experimental and Clinical Pharmacology]. - 1992. – No. 3, pp. 34-37.(in Russian)
 56. Efimov, A. S. *Diabeticheskiye angiopatii* [Diabetic angiopathies] / A. S. Efimov. –2nd ed. - M.:Meditsina Publ., 1989. -288p.
 57. Erokhin, V. V. *Funktsionalnaya morfologiya legkikh*[Functional morphology of the lungs] / V. V. Erokhin. - M.:Meditsina Publ., 1987. 272p.
 58. Zhanatayev, A. K. *Izucheniye genotoksichnosti digidrokvvertsetina in vivo* [Study of the genotoxicity of dihydroquercetin in vivo] / A. K. Zhanatayev. A. V. Kulakova. V. V. Nasonova. A. D. Durnev // *Byulleten eksperimentalnoy biologii i meditsiny* [Bulletin of Experimental Biology and Medicine]. – 2008. – No.3, pp. 309-312.(in Russian)
 59. Zhestovskiy, S. S. *Sovremennoye sostoyaniye problem profilaktiki i lecheniya sakharnogo diabeta (obzor)* [The current state of the problems of the prevention and treatment of diabetes mellitus (review)] / S. S. Zhestovskiy, L. V. Petrova. A. S. Ametov // *Terapevticheskiy arkhiv* [Therapeutic archive]. - 2007. – No.10, pp. 46–50.(in Russian)
 60. Zakirianov, A. R. *Regeneratsionnaya kletochnaya terapiya sakharnogo diabeta 1-go tipa i ego oslozhneniy* [Regenerative cell therapy of type 1 diabetes mellitus and its complications] / A. R. Zakirianov. N. A. Onishchenko. E. D. Klimenko. O. M. Pozdnyakov // *Vestnik Rossiyskoy AMN* [Bulletin of the Russian Academy of Medical Sciences]. - 2008. – No. 3, pp. 42-51. (in Russian)
 61. Zapadnyuk, I. P. *Laboratornyye zhivotnyye. Razvedeniye. sodержaniye. ispolzovaniye v eksperimente* [Laboratory animals. Breeding, content, use in experiment] / I. P. Zapadnyuk. V. I. Zapadnyuk. E. A. Zakhariya. - Kiev: VysshshayashkolaPubl., 1974, pp. 148-175.
 62. Zenkov, N. K. *Okislitelnyy stress: Biokhimicheskiy i patofiziologicheskiy aspekty* [Oxidative stress: Biochemical and pathophysiological aspects] / N. K. Zenkov. V. Z. Pankin. E. B. Menshikova. - M.:MAIK “Nauka/Interperiodoka” Publ., 2001. 343p.
 63. Zilov, A. V. *Kombinirovannaya terapiya sakharnogo diabeta 2 tipa. Rol i mesto tabletirovannykh preparatov* [Combined therapy of type 2 diabetes mellitus. The role and place of tablets]/ A. V. Zilov // *Lechashchiy vrach*

[Therapist]. - 2007. – No, 10, pp. 32-35.(in Russian)

64. Ivanov, V. V. *Perekisnoye okisleniye lipidov v pecheni krysa pri alloksanovom diabete* [Peroxide oxidation of lipids in liver of rats with alloxan diabetes] / V. V. Ivanov. I. V. Vaseneva. N. A. Ufimtsev // *Problemy endokrinologii* [Problems of endocrinology]. – 1984. – No.1, pp. 70–73.(in Russian)
65. Ivanova, V. F. *Strukturno–funktsionalnyye izmeneniya v podzheludochnoy zheleze beloy krysy pri vvedenii glyukozy* [Structural and functional changes in the pancreas of a white rat with the administration of glucose] / V. F. Ivanova. A. A. Puzyrev // *Morfologiya* [Morphology]. – 2006. – No. 1, pp. 67–71.(in Russian)
66. Kagan, V. E. *Ob uchastii svobodnykh aktivnykh form kisloroda v fermentativnom perekisnom okislenii lipidov v biomembranakh* [About participation of free active forms of oxygen in enzymatic peroxidation of lipids in biomembranes] / V. E. Kagan. L. L. Prilipko. V. M. Savov // *Biokhimiya* [Biochemistry]. - 1979. - Vol.44, No.3, pp. 482-489.(in Russian)
67. Kendysh, I. N. *Regulyatsiya uglevodnogo obmena* [Regulation of carbohydrate metabolism] / I. N. Kendysh. - M.: Meditsina Publ., 1985. 272 p.
68. Klebanova, E. M. *Okislitelnyy stress, funktsionalnaya aktivnost V – kletok i sodержaniye faktora nekroza opukholi u bolnykh sakharnym diabetom 2-go tipa* [Oxidative stress, functional activity of B cells and the content of tumor necrosis factor in patients with type 2 diabetes mellitus] / E. M. Klebanova // *Klinicheskaya meditsina* [Clinical Medicine]. – 2006. – Vol. 84, No.8, pp. 40-43.(in Russian)
69. Kodolova, I. M. *Izmeneniya legkikh pri sakharnom diabete* [Changes in the lungs with diabetes mellitus] / I. M. Kodolova. L. V. Lysenko. B. B. Saltykov // *Arkhiv patologii* [The Archive of Pathology]. - 1982. - Vol.XLIV, No, 7, pp. 35-40.(in Russian)
70. Kolesnik, Y. M. *Izmeneniya endokrinnoy chasti podzheludochnoy zhelezy belykh laboratornykh krysa pri sakharnom diabete, adaptatsii k gipoksii i ikh sochetanii (immunotsitokhimicheskoye issledovaniye)* [Changes in the endocrine part of the pancreas of white laboratory rats in diabetes mellitus, adaptation to hypoxia and their combination (immunocytochemical study)] / Y. M. Kolesnik. A. V. Abramov. G. V. Vasilenko // *Morfologiya* [Morphology] - 1996. - Vol.109, No.1, pp. 91–94.(in Russian)
71. Kolesnik, Y. M. *Pankreaticheskiye ostrovki: nekotoryye aspekty morfologii, fiziologii i protsessov destruktzii pri sakharnom diabete tipa 1* [Pancreatic islets: some aspects of morphology, physiology and processes of destruction in type 1 diabetes mellitus] / Y. M. Kolesnik. M. A. Orlovskiy //

- Problemy endokrinologii* [Problems of endocrinology]. - 2004. - Vol. 50, No. 2, pp. 3–10.(in Russian)
72. Kondratyev, Y. Y. *Autoantitela k poverkhnosti ostrovkovykh kletok podzheludochnoy zhelezy: immunofermentnoye opredeleniye s ispolzovaniyem kletok – misheney krysa* [Autoantibodies to the surface of islet cells of the pancreas: an immunoenzymometric definition using rat target cells] / Y. Y. Kondratyev. N. V. Sadovnikova. A. L. Liozner. V. P. Fedotov // *Problemy endokrinologii* [Problems of endocrinology]. – 1986. – No.3, pp. 39–43.(in Russian)
73. Lipatov D.V., Kuzmin A.G., Tolkacheva A.A., Chistyakov T.A. *Osobennosti proliferativnogo protsessa u patsiyentov s diabeticheskoy retinopatiyey* [Features of the proliferative process in patients with diabetic retinopathy] / D.V. Lipatov. A.G. Kuzmin. A.A. Tolkacheva. T.A. Chistyakov // *Sakharnyy diabet* [Diabetes mellitus]. - 2012. - No. 2 , p.15-20.(in Russian)
74. Lukianova, L. D. *Energotropnoye, antigipoksicheskoye i antioksidantnoye deystviye flavonoidov* [Energotropic, antihypoxic and antioxidant effects of flavonoids]/ L. D. Lukianova. E. L. Germanova. A. I. Lysko // *Vestnik RAMN* [Bulletin of the RAMS]. - 2007. – No.2, pp. 55-62.(in Russian)
75. Lukianova, L. D. *Farmakologicheskaya korrektsiya gipoksicheskikh sostoyaniy* [Pharmacological correction of hypoxic conditions]/ L. D. Lukianova // *V kn.: Problemy gipoksii: molekulyarnyye. fiziologicheskiye i klinicheskiye aspekty*[In the book: Problems of hypoxia: molecular, physiological and clinical aspects] / L. D. Lukianova. I. B. Ushakov. - M.:MeditsinaPubl., 2004, pp. 275-295.
76. Lukianchikov, V. S. *Patogenez i profilaktika sosudistykh oslozhneniy pri metabolicheskom sindrome i sakharnom diabete 2 tipa* [Pathogenesis and prevention of vascular complications in metabolic syndrome and type 2 diabetes mellitus] / V. S. Lukianchikov. I. V. Zvereva // *Russkiy meditsinskiy zhurnal* [Russian Medical Journal]. – 2009. – Vol.17, No.10, pp. 717–720.(in Russian)
77. Lysenko, L. V. *Diabeticheskaya makro- i mikroangiopatiya legkikh* [Diabetic macro- and microangiopathy of the lungs]/ L. V. Lysenko // *Arkhiv patologii* [Archive of pathology]. - 1990. - Vol. 52, No. 11, pp. 31-36.(in Russian)
78. Lysenko, L. V. *Ultrastrukturnyye i ultratsitokhimicheskiye izmeneniya legkikh u krysa pri sakharnom diabete* [Ultrastructural and ultracytochemical changes in lungs in rats with diabetes mellitus]/ L. V. Lysenko. A. I. Lysenko. V. P. Kulik // *Byulleten eksperimentalnoy biologii i meditsiny* [Bulletin of Experimental Biology and Medicine]. - 1990. - Vol. CIX, No.1, pp. 75-78.(in Russian)
79. Lyayfer, A. I. *Sistema perekisnogo okisleniya lipidov i antioksidantnaya*

- zashchita i rol eye narusheniy v patogeneze sakharnogo diabeta i angiopatii* [Lipid peroxidation system and antioxidant protection and the role of its disorders in the pathogenesis of diabetes mellitus and angiopathy]/ A. I. Lyayfer. M. N. Solun // *Problemy endokrinologii* [Problems of endocrinology]. - 1993. – No. 1, pp. 57-59.(in Russian)
80. Mazo V.K., Sidorova Y.S., Kochetkova A.A. *Geneticheskiye modeli sakharnogo diabeta 2-go tipa na myshakh dlya otsenki effektivnosti minornykh biologicheskii aktivnykh veshchestv pishchi* [Genetic models of type 2 diabetes mellitus in mice to assess the effectiveness of minor biologically active food substances] / V.K. Mazo, Y.S. Sidorova, A.A. Kochetkova // *Voprosy Pitaniya* [Food Questions].- 2014.- Vol.83, No.6, pp. 25-31.(in Russian)
81. Mazo V.K., Sidorova Y.S., Shipelin V.A., Retrov N.A., Kochetkova A.A. *Polifenolnyye rastitelnyye ekstrakty: vliyaniye na narusheniya uglevodnogo i lipidnogo obmena u laboratornykh gryzunov* [Polyphenolic plant extracts: effects on the disorders of carbohydrate and lipid metabolism in laboratory rodents]. / V.K. Mazo, Y.S. Sidorova, V.A. Shipelin, N.A. Retrov, A.A. Kochetkova // *Problemy endokrinologii* [Problems of Endocrinology]. - 2016.- Vol.62, No.4, pp. 38-44.(in Russian)
82. Mazhul, L. M. *Nekotoryye pokazateli perekisnogo okisleniya lipidov v kro-vi krys raznogo vozrasta pri alloksanovom diabete* [Some indicators of lipid peroxidation in blood of rats of different ages with alloxan diabetes] / L. M. Mazhul // *Voprosy meditsinskoy khimii* [Questions of medical chemistry]. - 1987. – No.2, pp. 41-43.(in Russian)
83. Mazovetskiy, A. G. *Sakharnyy diabet* [Diabetes mellitus] / A. G. Mazovetskiy, V. K. Velikov. – M.:Meditsina Publ., 1987. 284 p.
84. Mkrtumyan, A. M. *Postprandialnaya giperglikemiya: eye znachenkiye i korrektsiya* [Postprandial hyperglycemia: its significance and correction]/ A. M. Mkrtumyan // *Consilium medicum*. – 2002. – Vol.4, No. 10, pp. 534–535.(in Russian)
85. Motavkin, P. A. *Klinicheskaya i eksperimentalnaya patofiziologiya legkikh* [Clinical and Experimental Pathophysiology of the Lungs] / P. A. Motavkin, B. I. Geltser. – M.:Nauka Publ., 1998. 366 p.
86. Nazhmutdinova, D. K. *Sostoyaniye mestnoy zashchity legkikh pri eksperimentalnom sakharnom diabete* [State of local lung protection in experimental diabetes mellitus]/ D. K. Nazhmutdinova // *Problemy endokrinologii* [Problems of Endocrinology]. - 2000. – Vol.46, No. 4, pp. 30-32.(in Russian)
87. Nedosugova, L. V. *Metabolicheskaya terapiya sakharnogo diabeta dibikorom: novyye dannyye* [Metabolic therapy of diabetes mellitus with dibicor: new data] / L. V. Nedosugova, E. P. Elizarova, M. I. Balabolkin // *Lechashchiy vrach* [The attending physician]. - 2004. – No. 6, pp. 20-21.(in Russian)

- Russian)
88. Nedosugova, L. V. *Farmakoekonomicheskiye aspekty lecheniya sakharnogo diabeta 2 tipa* [Pharmacoeconomic aspects of treatment of type 2 diabetes mellitus] / L. V. Nedosugova // *Sakharnyy diabet* [Diabetes mellitus]. - 2008. – N.39, No. 2, pp. 76-79.(in Russian)
 89. Nifantsev E.E., Koroteyev M.P., Kukhareva T.S., Koroteyev A.M., Pugashova N.M., Moryusov S.E., Kutuzova N.M., Kaziyev G.Z. *Khimicheskaya modifikatsiya i biologicheskaya aktivnost flavonoida digidrokvertsetina 1* [Chemical modification and biological activity of dihydroquercetin flavonoid 1.] / E.E. Nifantsev, M.P. Koroteyev, T.S. Kukhareva, A.M. Koroteyev, N.M. Pugashova, S.E. Moryusov, N.M. Kutuzova, G.Z. Kaziyev // *Nauka i shkola* [Science and school].- 2012.- No. 6, pp. 181-191.(in Russian)
 90. Novitskiy, V. V. *Modulyatsiya apoptoza mononuklearov v usloviyakh oksilitel'nogo stressa* [Modulation of apoptosis of mononuclears under oxidative stress conditions] / V. V. Novitskiy, N. V. Ryazantseva, N. Y. Chasovskikh, E. G. Starikova, E. V. Kaygorodova, Y. V. Starikov, O. B. Zhukova // *Byulleten eksperimentalnoy biologii i meditsiny* [Bulletin of experimental biology and medicine]. - 2008. - No. 3, pp. 251-254.(in Russian)
 91. Ogneva, V. V. *Gistologicheskaya i elektronmikroskopicheskaya kharakteristika D-kletok ostrovkov podzheludochnoy zhelezy* [Histological and electron microscopic characteristics of D cells of pancreatic islets] / V. V. Ogneva, P. P. Petkov // *Arkhiv anatomii, gistologii i embriologii* [Archive of anatomy, histology and embryology]. – 1972. - Vol.2, pp. 22–26.(in Russian)
 92. *Oksilitelnyy stress i apoptoz: obshchiye svedeniya. Biologiya i meditsina* [Oxidative stress and apoptosis: general information. Biology and medicine] – Biological databases (Institute of Biomedical Problems RAS site) // Available at: Medbiol.ru/medbiol/apopt_amo/0000e63d.htm. (Accessed 18 October 2008).
 93. Podgrebelnyy, A. N. *Rol fibroblastov v razvitii sakharnogo diabeta i ego oslozhneniy* [The role of fibroblasts in the development of diabetes mellitus and its complications] / A. N. Podgrebelnyy, O. M. Smirnov, I. I. Dedov // *Problemy endokrinologii* [Problems of Endocrinology]. - 2005. - Vol. 51, No. 2, pp. 14-22.(in Russian)
 94. Polikar, A. *Bronkholegochnyy apparat. Struktura i mekhanizmy v norme i pri patologii* [The bronchopulmonary apparatus. Structure and mechanisms in norm and in pathology] / A. Polikar. P. Gali. – N.: NaukaPubl., 1972. 333 p.
 95. Puzyrev, A. A. *Ultrastruktura endokrinnykh kletok podzheludochnoy zhelezy sobaki* [Ultrastructure of dog pancreatic endocrine cells] / A. A. Puzyrev, V. F. Ivanova, S. V. Kostyukevich // *Morfologiya* [Morphology]. - 2006. - Vol. 130, No. 6, pp. 68–72.(in Russian)
 96. Puzyrev, A. A. *Zakonomernosti tsitogeneza endokrinnoy*

- gastroenteropankreaticheskoy sistemy pozvonochnykh* [Regularities of cytogenesis of the endocrine gastroenteropancreatic system of vertebrates] / A. A. Puzyrev, V. F. Ivanova, S. V. Kostyukevich // *Morfologiya* [Morphology]. - 2003. - Vol. 124, N.4, pp. 11-19. (in Russian)
97. Puzyrev, A. A. *Elektronnomikroskopicheskoye izucheniye ostrovkov Langergansa podzheludochnoy zhelezy cheloveka* [Electron-microscopic study of the islets of the Langerhans pancreas of a person] / A. A. Puzyrev, V. F. Ivanova // *Arkhiv patologii* [Archive of pathology]. - 1974. - Vol. 36, No. 7, pp. 42-48. (in Russian)
98. *Respiratornaya meditsina* [Respiratory medicine] / ed. A.G. Chuchalina. - M.: GEOTAR - Media Publ., 2007. - Vol.1, pp. 23-40; 131-230.
99. Rogovskiy V.S., Rozenfeld M.A., Razumovskiy S.D., Matyushin A.I., Shimanovskiy N.L., Leonova V.B., Konstantinova M.L. *Otsenka sposobnosti digidrokvertsetina ingibirovat okisleniye fibrinogena ozonom* [Evaluation of the ability of dihydroquercetin to inhibit the oxidation of fibrinogen ozone]. / V.S. Rogovskiy, M.A. Rozenfeld, S.D. Razumovskiy, A.I. Matyushin, N.L. Shimanovskiy, V.B. Leonova, M.L. Konstantinova // *Eksperimentalnaya i klinicheskaya farmakologiya* [Experimental and clinical pharmacology]. - 2013. - Vol.76, No. 3, pp. 23-26. (in Russian)
100. Rogozhkin V.V., Peretolchin D.V., Rogozhkina T.V. *Issledovaniye fiziko-khimicheskikh svoystv digidrokvertsetina* [Investigation of the physico-chemical properties of dihydroquercetin]. / V.V. Rogozhkin, D.V. Peretolchin, T.V. Rogozhkina // *Izvestiya vuzov. Prikladnaya khimiya i biotekhnologiya* [News of universities. Applied Chemistry and Biotechnology]. - 2012. - Vol.2, No. 1, pp. 68-74. (in Russian)
101. Romanova, L. A. *Metod opredeleniya gidroperekisey lipidov s pomoshchyu tiotsionata ammoniya* [A method for defining lipid hydroperoxides by means of ammonium thiocyanate] / L. A. Romanova, I. D. Stalnaya // *Sovremennyye metody v biokhimii* [Modern methods in biochemistry] / ed. V.N. Orekhovich. - M.: Meditsina Publ., 1977, pp. 64-66.
102. Sazonova, O. V. *Fenomen perekisnogo okisleniya v patogeneze sosudistykh slozhnykh sakharnog odiabeta* [Phenomenon of peroxidation in the pathogenesis of vascular complications of diabetes mellitus] / O. V. Sazonova, O. A. Nikiforov, L. Y. Sukhanova // *Consilium medicum*. - 2000. - №6, pp. 73-76. (in Russian)
103. Saltykov, B. B. *Dinamicheskoye morfologicheskoye nablyudeniye za razvitiyem diabeticheskoy mikroangiopatii* [Dynamic morphological observation of the development of diabetic microangiopathies] / B. B. Saltykov, V. K. Velikov // *Arkhiv patologii* [Archive of Pathology]. - 2000. - Vol. 62, No. 6, pp. 42-46. (in Russian)

104. Saltykov, B. B. *Patogeneticheskiyemekhanizmydiabeticheskoy mikroangiopatii* [Pathogenetic mechanisms of diabetic microangiopathy] / B. B. Saltykov // *Arkhiv patologii* [Archive of Pathology]. - 1984. - N.12, No. 8, pp. 78-83. (in Russian)
105. Severgina, E. S. *Lokalizatsiya B-kletok vatsinusakh – obychnoye yavleniye ili priznakkompensatornogo protsessapri insulinozavisimom sakharnom diabete?* [The localization of B cells in the acini is a common phenomenon or symptom of the compensatory process in insulin-dependent diabetes mellitus?] / E. S. Severgina, T. G. Dyuzheva, L. E. Razgulina, I. B. Stakheyev // *Arkhiv patologii* [Archive of Pathology]. - 1992. - Vol.54, No. 12, pp. 18-23. (in Russian)
106. Sokolov, E. I. *Gazoobmennaya funktsiya legkikh u bolnykh SD 1 tipa* [Gas exchange function of lungs in patients with type 1 DM] / E. I. Sokolov, Y. I. Demidov // *Terapevt. arkh* [Therapeutist. arch]. - 2008. – No. 3, pp. 63-68. (in Russian)
107. Smolyanskiy, B. L. *Lecheniye sakharnogo diabeta* [Treatment of diabetes mellitus] / B. L. Smolyanskiy, V. G. Lifyanskiy. – St. Petersburg: Neva Publ. - 2004. 384 p.
108. Snigur, G. A. *Strukturnyye izmeneniya v pankreaticheskikh ostrovkakh pri eksperimentalnom SD na fone vvedeniya BAD na osnove Gamnemy lesnoy* [Structural changes in pancreatic islets during experimental DM in the setting of administration of dietary supplements on the basis of Gamnema forest] / G. A. Snigur, M. P. Samokhina, V. B. Pisarev, A. A. Spasov, A. E. Bulanov // *Morfologiya* [Morphology]. - 2008. – No. 1, pp. 60-64. (in Russian)
109. Sukhanova, L.Y. *Perekisnoye okisleniye lipidov u bolnykh sakharnym diabetom* [Peroxide oxidation of lipids in patients with diabetes mellitus] / L.Y. Sukhanova, L.A. Kulikova, V.A. Galenok // *Problemy endokrinologii* [Problems of endocrinology]. – 1988. – No. 2, pp. 16–17. (in Russian)
110. Strukov, A. I. *Vospaleniye* [Inflammation] / A. I. Strukov, V. S. Paukov, O. Y. Kaufman // *Obshchaya patologiya cheloveka* [General human pathology]. - M.: Meditsina Publ., 1990, pp. 3-73.
111. Teselkin, Y. O. *Antioksidantnyye svoystva digidrovertsetina* [Antioxidant properties of dihydroquercetin] / Y. O. Teselkin, B. A. Zhambalova, I. V. Babenkova, G. I. Klebanova, N. A. Tyukavkina // *Biofizika* [Biophysics]. - 1996. - Vol.41, N.3, pp. 621–623. (in Russian)
112. Tekhver, Y. T. *Gistologiya dykhatelnykh organov domashnykh zhivotnykh* [Histology of the respiratory organs of domestic animals] / Y. T. Tekhver. – Tartu: Nauka Publ., 1977. 87 p.
113. *Osobennosti techeniya khronicheskoy obstruktivnoy bolezni legkikh u bolnykh sakharnym diabetom* [Features of the course of chronic obstructive pulmonary disease in diabetic patients] / E. A. Titova, A. I. Algazin, T. A.

- Kornilova, I. P. Sokol, E. M. Reutskaya, E. M. Petayeva, V. M. Strebkova, V. N. Chirkova, L. E. Shulgina, Y. N. Shoykhet // *Pulmonologiya* [Pulmonology].- 2008. –No. 5, pp. 60-65.(in Russian)
114. Titok, T. G. *Modeli sakharnogo diabeta. ikh vybor i ispolzovaniye v eksperimentalnykh issledovaniyakh* [Models of diabetes mellitus, their choice and use in experimental studies] / T. G. Titok [etal] // *Biopolimery i kletka* [Bio-polymers and cell]. - 1999. - Vol.15, No. 2, pp. 103-108.(in Russian)
115. Williams, G. *Rukovodstvo po diabētu* [The Guide to Diabetes] / G. Williams, D.K. Pikam. – M.:Med.press–informPubl., 2003. 248 p.
116. Uminskiy, A. A. *Biokhimiya flavonoidov i ikh znacheniyev meditsine* [Biochemistry of flavonoids and their importance in medicine] / A. A. Uminskiy, B. K. Khavsteyen, V. F. Bakaneva. – M.: Pushchino, OOO “Foton – vek” Publ., 2007. 264 p.
117. Utekhin, V. I. *Ultrastrukturnaya karakteristika “svetlykh” i “temnykh” B-kletok v pankreaticheskiykh ostrovkakh krysa* [Ultrastructural characterization of "light" and "dark" B cells in pancreatic islets of the rat] / V. I. Utekhin // *Tsitologiya* [Cytology]. - 1979. - Vol. 21, No. 1, pp. 21-24.(in Russian)
118. Khavinson, V. K. *Vliyaniye tetrapeptidana na techeniye eksperimentalnogo sakharnogo diabeta* [Effect of tetrapeptide on the course of experimental diabetes mellitus] / V. K. Khavinson, V. V. Malinin // *Meditsinskiy akademicheskiy zhurnal* [Medical academic journal]. - 2008. – No. 1, pp. 145-151.(in Russian)
119. Khalimov Y.S., Salukhov V.V., Ulupova E.O. *Gipoglikemiya kak osnovnyy faktor vyboratseley glykemicheskogo kontrolya i taktik ilecheniya bolnykh sakharnym diabetom tipa 2* [Hypoglycemia as the main factor in the selection of the goals of glycemic control and treatment tactics in patients with type 2 diabetes mellitus.] / Y.S. Khalimov, V.V. Salukhov, E.O. Ulupova // *Consilium medicine*.- 2012.- Vol.14, No. 12, pp. 25-30.(in Russian)
120. Khnychenko, L. K. *Vybor preparatov metabolicheskogo tipa deystviya v terapii sakharnogo diabeta* [Choice of drugs of metabolic type of action in the treatment of diabetes mellitus] / L. K. Khnychenko, I. V. Okunevich, O. V. Ryzhova // *Meditsinskiy akademicheskiy zhurnal* [Medical academic journal]. - 2006. – Vol.6, No. 4, pp. 17-24.(in Russian)
121. Chernikova N.A., Abayeva B.S., Prudnikova M.A., Suchkova E.V. *Antioksidantnaya terapiya v kompleksnom upravlenii sakharnym diabetom* [Antioxidant therapy in the integrated management of diabetes mellitus] / N.A. Chernikova. B.S. Abayeva. M.A. Prudnikova. E.V. Suchkova. // *Consilium medicine*.-2010.- Vol.12, No. 12, pp. 37-40.
122. Chumasov E.I., Petrova E.S., Korzhevskiy D.E. *Izmeneniye ostrovkov i nervnykh elementov v podzheludochnoy zhelezeyu krysa*

- renii* (immunogistokhimicheskoye issledovaniye)
 [Changing of islets and nerve elements in the pancreas in rats with aging
 (immunohistochemical study)] / E.I. Chumasov, E.S. Petrova, D.E. Korzhevskiy
 // *Morfologiya* [Morphology]. - 2015. - Vol.148, No. 6, pp. 64-69. (in Russian)
123. Tseluyko, S.S. *Morfologicheskaya kharakteristika soyedinitelnoy tkani organov dykhaniya pri obshchem okhlazhdenii* [Morphological characteristics of connective tissue of respiratory organs in general cooling] / S.S. Tseluyko, V.A. Dorovskikh, N.P. Krasavina. - Blagoveshchensk: Meditsina Publ., 2000. 256 p.
124. Tseluyko S.S., Krasavina N.P., Semenov D.A. *Regeneratsiya tkaney* [Regeneration of tissues] / S.S. Tseluyko, N.P. Krasavina, D.A. Semenov: Blagoveshchensk. - 2016. 136p.
125. Shestakova E.A. *Vozmozhnosti ranney kombinirovannoy terapii sakharnogo diabeta 2-go tipa* [Possibilities of early combination therapy of type 2 diabetes mellitus]. / E.A. Shestakova // *Problemy Endokrinologii* [Problems of Endocrinology]. - 2012. - Vol.61, No.5, pp. 56-59.(in Russian)
126. Shestakova M.V., Sukhareva O.Y. *Sakharnyy diabet tipa 2: Legko li predupredit i mozno li vylechit?* [Diabetes mellitus type 2: is it easy to prevent and can it be cured?] / M.V. Shestakova, O.Y. Sukhareva // *Consilium medicine*. - 2012. - Vol.14, No.12 pp. 5-9.(in Russian)
127. Shishkova, V.N. *Osobennosti razvitiya ostrogo i khronicheskogo vospaleniya verkhnykh dykhatelnykh putey i patsiyentov s sakharnym diabetom* [Features of the development of acute and chronic inflammation of the upper respiratory tract and patients with diabetes mellitus]. / V.N. Shishkova // *Consilium medicine*. - 2015. - Vol.17, No. 4, pp. 40-43.(in Russian)
128. Shoykhet, Y.N. *Kompyuternaya tomografiya i gistologicheskiye izmeneniya v legkikh pri sakharnom diabete* [Computer tomography and histological changes in the lungs with diabetes mellitus] / Y.N. Shoykhet [et al] // *Byulleten Sibirskogo otdeleniya RAMN* [Bulletin of the Siberian Branch of RAMS]. - 2008. - No. 2, pp. 63-67.(in Russian)
129. Shcherbak, A. V. *Patologiya organov dykhaniya pri sakharnom diabete* [The pathology of respiratory organs in diabetes mellitus] / A. V. Shcherbak // *Terapevticheskiy arkhiv* [Therapeutic archive]. - 1986. - No.8, pp. 148-151.(in Russian)
130. *Endokrinologiya: Natsionalnoye rukovodstvo* [Endocrinology: National guidance] / ed. I. I. Dedova, T. A. Melnichenko. - M.: GEOTAR - Media Publ., 2008, pp. 357-381.
131. Apple, A. *Strukturno funktsionalnyye vzaimootnosheniya v evolyutsii ostrovkovoy tkani* [Structurally functional relationships in the evolution of islet tissue] / A. Apple. D. E. Brin // *V kn.: Evolyutsionnaya endokrinologiya podzheludochnoy zhelezy* [In the book: Evolutionary endocrinology of the

- pancreas]. - L.: Nauka Publ., 1977, pp. 66–73.
132. Abe, N. Pancreatic endocrine function and glucose transporter (GLUT)-2 expression in rat acute pancreatitis / N. Abe, T. Watanabe, S. Ozawa et al. // *Pancreas*. - 2002. - Vol. 25. - P. 149 - 153.
 133. Aerts, L. Ultrastructural evaluation of B-cell recruitment in virgin and pregnant offspring of diabetic mothers / L. Aerts, F.A. Van Assche // *Diabetes Res. Clin. Pract.* - 1998. - Vol. 41. - P. 9-14.
 134. Abdelli, S. JNK3 is abundant in insulin – secreting cells and protects against cytokine – induced apoptosis / S. Abdelli, J. Puyal, C. Biemann, V. Buchillier, A. Abderrahmani, J. S. Beckmann, J. S. Clarke, C. Bonny // *Diabetologia*. – 2009. – Vol. 52, № 9. – P. 1871–1880.
 135. Adler, A. I. Association of systolic blood pressure with macrovascular and microvascular complications of type 2 diabetes (UKPDS 36): prospective study / A. I. Adler, I. M. Stratton, H. A. Neil et al. // *BMJ*. - 2000. - Vol. 321. - P. 412-419.
 136. Arthur, C.W. Altered Exercise Gas Exchange as Related to microalbuminuria in Type 2 Diabetic Patients / C.W. Arthur, K.W. Matthew, T.C. Godwin, P.T. Frankie, Y.C. Loretta, K. Wasserman // *CHEST*. – 2004. – Vol. 125, № 4. - P. 1292–1298.
 137. Bensellam, M. Cluster analysis of rat pancreatic islet gene mRNA levels after culture in low-, intermediate- and high-glucose concentration / M. Bensellam, L. Van Lommel, L. Overbergh, F. C. Schuit, J. C. Jonas // *Diabetologia*. – 2009. – Vol. 52, № 3. – P. 463-476.
 138. Blostein-Fujii, A. Short term citrus flavonoid supplementation of type II diabetic women: no effect on lipoprotein oxidation tendencies / A. Blostein-Fujii, R. A. Disilvestro, D. Frid, C. Katz // *Free Radic Res*. – 1999. - № 30. – P. 315–320.
 139. Bouwens, L. Regulation of pancreatic beta-cell mass / L. Bouwens, I. Rooman // *Physiol. Rev.* - 2005. - Vol. 85, № 4. - P. 1255-1270.
 140. Bunn, H. F. Nonenzymatic glycosylation of protein: relevance to diabetes / H. F. Bunn // *Am. J. Med.* - 1981. - Vol. 70. - P. 325-330.
 141. Butler, A.E. Beta-cell deficit and increased beta-cell apoptosis in humans with type 2 diabetes / A. E. Butler, J. Janson, S. Bonner-Weir et al. // *Diabetes*. - 2003. - Vol. 52, № 1. - P. 102-110.
 142. Calafiore, R. Gifts of microencapsulated islet cells for the therapy of diabetes mellitus in nonimmunosuppressed animals / R. Calafiore, G. Basta, G. Luca et al. // *Biotechnol. Appl. Biochem.* - 2004. - V. 39, № 2. - P. 159-164.
 143. Ciriello, A. Hyperglycaemia: the bridge between non-enzymatic glycation and oxidative stress in pathogenesis of diabetic complications / A. Ciriello // *Diabet. Nutr. Metab.* - 1999. - Vol. 12, № 1. - P. 42-46.

144. Churchill, L. Contribution of specific cell-adhesive glycoproteins to airway and alveolar inflammation and dysfunction / L. Churchill, R. H. Gundel, L. G. Letts, C. D. Wegner // *Am. Rev. Respir. Dis.* - 1993. - Vol. 148, № 6. - Pt. 2. - P. 83 - 87.
145. Chong, A.S. Reversal of diabetes in non-obese diabetic mice without spleen cell-derived beta cell regeneration / A. S. Chong, J. Shen, J. Tao // *Science.* - 2006. – Vol. 311, № 5768. - P. 1774-1775.
146. Coppieters, K. Taking a closer look at the pancreas / K. Coppieters, M. von Herrath // *Diabetologia.* – 2008. – Vol. 51, № 12. – P. 2145-2147.
147. De Dios Escolar, J. Pulmonary response to bovine albumin. A morphometric study in rats / J. De Dios Escolar, E. Alafaro, P. A. Roche, C. Almajano, B. Gallego // *Histol-Histopathol.* - 1994. - Vol. 9, № 1. - P. 15-22.
148. De Haro-Hernandez, R. Regeneration of beta-cells and neogenesis from small ducts or acinar cells promote recovery of endocrine pancreatic function in alloxan-treated rats / R. De Haro-Hernandez, L. Cabrera-Munoz, J. D. Mendez // *Arch. Med. Res.* – 2004. – Vol. 35, № 2. - P. 114-120.
149. Ditzel, J. Hemoglobin A_{1c} and red cell oxygen-releasing capacity in relation to early microvascular responses in ambulatory diabetics / J. Ditzel, P. Jaeger, J. J. Kjaergaard // *Microcirc. Diabetes. Basel* - 1979. - Vol. 8. - P. 1-13.
150. Dominguez Bendala, J. Pancreatic Stem Cells / J. Dominguez Bendala // Humana Press: a part of Springer Science Business Media, LLC. - 2009. – P.157.
151. Elbein, S. C. Molecular-genetic analysis and assessment of insulin action and pancreatic β -cell function / S. C. Elbein, W. K. Ward, J. C. Beard, M. A. Permutt // *Diabetes.* - 1988. - Vol. 37, № 4. - P. 377-382.
152. Estacio, R. O. Effect of blood pressure control on diabetic microvascular complications in patients with hypertension and type 2 diabetes / R. O. Estacio, B. W. Jeffers, N. Gifford, R. W. Schrier // *Diabetes Care.* - 2000. - Vol. 23 (Suppl. 2). - P. B54-B64.
153. Faerch, K. Pathophysiology and aetiology of impaired fasting glycaemia and impaired glucose tolerance: does it matter for prevention and treatment of type 2 diabetes? / K. Faerch, K. Borch-Johnsen, J. J. Holst, A. Vaag // *Diabetologia.* – 2009. – Vol. 52, № 9. – P. 1714–1723.
154. Federici, M. High glucose causes apoptosis in cultured human pancreatic islets of Langerhans: a potential role for regulation of specific Bcl-2 family genes toward an apoptotic cell death program / M. Federici, M. Hribal, L. Perego et al. // *Diabetes.* - 2001. - V.15. - P. 1290-1301.
155. Fonseca V., Gill J., Zbou R. et al. An analysis of early insulin glargine added to metformin with or without sulfonylurea: impact on glycaemic control and hypoglycaemia / V. Fonseca, J. Gill, R. Zbou et al // *Diabetes Obes Metab.* - 2011. - Vol.13, №9. - P.814-822.

156. Fraker, C. A. Enhanced oxygenation promotes beta cell differentiation in vitro / C. A. Fraker, S. Alvarez, P. Papadopoulos, J. Giraldo, W. Gu, C. Ricordi, L. Inverardi, J. Dominguez-Bendala // *Stem cells express.* – 2007. – Doi. 10.1634. – P. 1-20.
157. Francini, F. Effect of an acute glucose overload on islet cell morphology and secretory function in the toad / F. Francini, H. Del Zotto, J. Gagliardino // *Gen. Comp. Endocrinol.* – 2001. - Vol. 22. - P.138.
158. Fushiya, S. Flavonoids from *Cleome droserifolia* suppress NO production in activated macrophages in vitro / S. Fushiya, Y. Kishi, K. Hattori, J. Batkhuu, F. Takano, A. N. Singab, T. Okuyama // *Planta Med.* - 1999.- № 65.- P.404–407.
159. Garber A. Incretin effects on β -cell function, replication, and mass / A. Garber // *Diabetes Care.*- 2011.- Vol.34, №2.- P.258-263.
160. Groop, L. Organ-specific autoimmunity and HLA-DR antigens as markers for β -cell destruction in patients with type II diabetes / L. Groop, A. Miettinen, P. H. Groop et al. // *Diabetes.* - 1988. - Vol. 37, № 1. - P. 99-103.
161. Govendir, M. Morphometric study of the beta-cell volume of the canine pancreas with consideration on the axis of tissue transaction / M. Govendir, P. J. Canfield, D. B. Church // *J. Vet. Med. Sci.* - 1999. – Vol.61, № 7. - P.737-742.
162. Imat, Y. Restricted expression of galactose. N – acetylgalactosamine – specific macrophage C – type lectin to connective tissue and to metastatic lesions in mouse lung / Y. Imat, Y. Akimoto, S. Mizuochi, K. Kimural, H. Hirano, T. Irimura // *Immunology.* – 1995. – Vol.86, № 4. - P. 591–598.
163. Imberty, A. Conformations of cell surface oligosaccharides and recognition by lectins from pathogens / A. Imberty // *International Journal of Experimental Pathology.* – 2004. – Vol.85, № 4. - P.50–51.
164. Hansen, S. H. The role of taurine in diabetes and the development of diabetic complications / S. H. Hansen // *Diab. Metab. Res. Rev.* - 2001. - Vol. 17. - P. 330-345.
165. Haspal, H. C. Glucose deprivation and hexose transporter polypeptides of murine fibroblasts / H. C. Haspal, E. W. Wilk, M. T. Birnbaum et al. // *J. Biol.Chem.* - 1986. - Vol. 261. - P. 6778-6789.
166. Hadjiliadis, D. Incidence and prevalence of diabetes mellitus in patients with cystic fibrosis undergoing lung transplantation before and after lung transplantation / D. Hadjiliadis, J. Madill, C. Chaparro, A. Tsang, T. Waddell, L. Singer, M. Hutcheon, S. Keshavjee, T. Elizabeth // *Clinical Transplantation.* - 2005. - Vol.19, № 6. – P. 773–778.
167. Hellman, B. O. The pancreatic β -cell recognition of insulin and sodium on glucose metabolism and insulin release / B. O. Hellman, L. A. Idahe, A. Le Minmark, J. Sehlin, T. Taljedal // *J. Biochem.* - 1974. - Vol. 138. - P. 33-45.

168. Hosker, J. P. Similar reduction of first- and second-phase B-cell responses at three different glucose levels in type II diabetes and the effect of gliclazide therapy / J. P. Hosker, A. S. Rudenski, M. A. Burnett et al. // *Metabolism*. - 1989. - Vol.38, № 6. - P. 797-772.
169. Jennings, P. E. Vitamin C metabolites and microangiopathy in diabetes mellitus / P. E. Jennings, S. Chirico, A. F. Jones et al. // *Diabetes Rev.* - 1987. - Vol. 6. - P. 151-154.
170. Jialal, I. Pathogenesis of macroangiopathy in diabetes / I. Jialal, A. Chait // *Complications of diabetes mellitus* / Eds. B. Draznin et al. - New York. - 1989. - P. 69-75.
171. Johnston, C. β -cell function and insulin sensitivity in nondiabetic HLA-identical siblings of insulin-dependent diabetes / C. Johnston, P. Raghu, D. K. McCulloch et al. // *Diabetes*. - 1987. - Vol. 36, № 7. - P. 829-837.
172. Kahn, S. E. The beta cell lesion in type 2 diabetes: there has to be a primary functional abnormality / S. E. Kahn, S. Zraika, K. M. Utzschneider, R. L. Hull // *Diabetologia*. – 2009. – Vol. 52, № 6. – P.1003-1012.
173. Kaparianos, A. Pulmonary complications in diabetes mellitus / A. Kaparianos, E. Agryropoulou, F. Sampsonas, K. Karkoulas, M. Tsiamita, K. Spiropoulos // *Chronic Respiratory Disease*. - 2008. - № 5. - P.101-108.
174. Lacy, P.E. Structure and function of the endocrine cell types of the islets // *Adv. Metabol. Dis.* – 1974. - Vol. 7. - P.171-182.
175. Lacy, P.E. The pancreatic beta cell. Structure and function / P. E. Lacy // *New Engl. J. Med.* - 1967. - Vol. 276. - P. 187-195.
176. Lieveise A.G. et al. Glycaemic control of Type 2 diabetics with insulin glargine in everyday practice / A.G. Lieveise et al. // *Diabetes Stoffw Herz*.- 2013.- №22.- P.141-147.
177. Lipsett, M. Beta-cell neogenesis during prolonged hyperglycemia in rats / M. Lipsett, D. T. Finegood // *Diabetes*. – 2002. – Vol. 51, № 6. - P. 1834-1841.
178. Liu, T. In vitro pancreas duodenal homeobox-1 enhances the differentiation of pancreatic ductal epithelial cells into insulin-producing cells / T. Liu, C. Y. Wang, F. Yu, C. M. Gou et al. // *Gastroenterol.* – 2007. – Vol. 13, № 39. – P. 5232–5237.
179. Matthaei, S. Blood glucose transfer in diabetes mellitus: decreased number of glucose transporters at blood-brain barrier / S. Matthaei, R. Horuk, J. M. Olefsky // *Diabetes*. - 1986. - Vol. 35, № 10. - P. 1181-1184.
180. Marzo, V. The endocannabinoid system in obesity and type 2 diabetes / V. Marzo // *Diabetologia*. – 2008. – Vol. 51, № 8. - P.1356-1367.
181. McDonald, R. J. Alveolar macrophage antioxidants prevent hydrogen peroxide-mediated lung damage / R. G. McDonald, E. M. Berger, J. E. Repine

- // Am. Rev. Respir. Dis. - 1991. - Vol. 143, № 5. - P. 1088-1091.
182. Nauck M.A. Incretin-based therapies for type 2 diabetes mellitus: properties, functions and clinical implication / M.A.Nauck // Am J Med.- 2011.- №124.- P.3-18.
 183. Nijveldt, R. J. Flavonoids: a review of probable mechanisms of action and potential applications / R. G. Nijveldt, E. F. van Nood, D. E. C. van Hoorn et al. // Am. J. Clin. Nutr. - 2001. – Vol. 74(4). - P.418-425.
 184. Orci, L. A portrait of the pancreatic β -cell. The Minkowski award lecture / L. Orci // Diabetologia. – 1974. - Vol. 10. - P. 1-25.
 185. Orci, L. Morphological and biochemical studies of β -cells of fetal rat endocrine pancreas in organ culture. Evidence for proinsulin biosynthesis / L. Orci, A. E. Lambert, Y. Kanazawa, M. Amherdt, C. Rouiller, A. E. Renold // J. Cell Biol. – 1971. - Vol. 50. - P. 565-582.
 186. Panzram, G. Mortality and survival in type 2 (non-insulin-dependent diabetes mellitus) / G. Panzram // Diabetologia. - 1987. - Vol. 30, № 3. - P. 123-131.
 187. Peters, K. Expression of stem cell markers and transcription factors during the remodeling of the rat pancreas after duct ligation / K. Peters, R. Panienska, J. Li et al. // Virchows Arch. - 2005. -Vol. 446, № 1.- P. 56-63.
 188. Phung O.J., Sobieraj D.M., Engel S.S., Rajpathak S.N. Early combination therapy for the treatment of type 2 diabetes mellitus: systematic review and meta-analysis / O.J. Phung, D.M. Sobieraj, S.S. Engel, S.N. Rajpathak // Diabetes Obes Metab.- 2014.- Vol.16, №5.- P.410-417.
 189. Popov, D. Structural and transport property alterations of lung capillary endothelium in diabetes / D. Popov, M. Simionescu // Ital. J. Anat. Embryol. - 2001. – Vol. 106(2 Suppl 1). - P. 405-412.
 190. Pukel, C. Destruction of rat islet cell monolayers by cytokines: synergistic interactions of interferon- γ , tumor necrosis factor, lymphotoxin and interleukin I / C. Pukel, H. Baquerizo, A. Rabinovitch // Diabetes. - 1988. - Vol. 37. - P. 133 - 136.
 191. Ren, S. Impact of antioxidants and HDL on glycated LDL-induced generation of fibrinolytic regulators from vascular endothelial cells / S. Ren, G. X. Shen // Arterioscler Thromb. Vasc. Biol. – 2000. – Vol. 20. - P. 1688-1693.
 192. Rice-Evans, CA. The relative antioxidant activities at plant-derived polyphenolic flavonoids / C. A. Rice-Evans, N. G. Miller, P. G. Bolwell et al. // Free Radic. Res. - 1995. – Vol. 22. - P.375-383.
 193. Riley, D. J. Damage and repair of lung connective tissue in rats exposed to toxic levels of oxygen / D. J. Riley, M. J. Kramer, J. S. Kerr, C. U. Chae, S. Y. Yu, R. A. Berg // Am. Rev. Respir. Dis. - 1987. - Vol. 135, № 2. - P. 441-447.
 194. Rooman, I. Gastrin stimulates beta-cell neogenesis and increases islet

- mass from trans-differentiated but not from normal exocrine pancreas tissue / I. Rooman, J. Lardon, L. Bouwens // *Diabetes*. - 2002. - Vol. 51, № 3. - P. 686-690.
195. Schneider, S. H. Impaired fibrinolytic response to exercise in type II diabetes: effects of exercise and physical training / S. H. Schneider, H. C. Kim, A. K. Khachadurian, W. B. Ruderman // *Metabolism*. - 1988. - Vol. 37, № 10. - P.924-929.
 196. Shimoni, Y. Type I and II models diabetes produce different modifications of K⁺ currents in rat heart: Role of insulin / Y. Shimoni, H. S. Ewart, D. Severson // *Physiol*. - 1998. – Vol. 507, №2. – P. 485-496.
 197. Taylor, R. Pathogenesis of type 2 diabetes: tracing the reverse route from cure to cause / R. Taylor // *Diabetologia*. – 2008. – Vol. 51, № 10. – P. 1781-1789.
 198. Tenerz, A. Myocardial infarction and prevalence of diabetes mellitus. Is increased casual blood glucose at admission a reliable criterion for the diagnosis of diabetes? / A. Tenerz, I. Lonnberg, C. Berne et al. // *Eur. Heart Dis*. – 2001. - №22. - P. 1102-1110.
 199. Teta, M. Growth and regeneration of adult β cells does not involve specialized progenitors / M. Teta, M. M. Rankin, S. Y. Long, G. M. Stein, J. A. Kushner // *Developmental cell*. – 2007. - № 12. – P. 817–826.
 200. Tielker, D. Pseudomonas aeruginosa lektin Lecb is located in the outer membrane and is involved in biofilm formation / D. Tielker // *Microbiologi*. - 2005. – Vol. 151, № 5. – P. 1313–1323.
 201. Toso, C. The role of macrophage migration inhibitory factor on glucose metabolism and diabetes / C. Toso, J. A. Emamaullee, S. Merani, F. M. J. Shapiro // *Diabetologia*. – 2008. – Vol. 51, № 11. – P. 1937-1946.
 202. Tushuizen, M. E. Pancreatic fat content and beta-cell function in men with and without type 2 diabetes / M. E. Tushuizen, M. C. Bunck, P. G. Pouwels et al. // *Diabetes Care*. – 2007. - № 30. – P. 2916-2921.
 203. Vercheval, M. Experimental diabetes impairs rat embryo development during the preimplantation period / M. Vercheval, R. De Hertigh, S. Pamfer // *Diabetologia*. - 1990. - Vol. 33, № 4. - P. 187-194.
 204. Vertounnen, J. Flavonoid treatment reduces glycation and lipid peroxidation in experimental diabetic rats / J. Vertounnen, V. van den Enden, L. Simoeus, I. de Leeuw // *Phytother Res*. – 1994. - №8. - P. 430–432.
 205. Veneman T.F., Storms F.E.M.G., Eland I.A., Bouter P.K.P. From insulin detemir to glargine. Effect on glycemic control and psychological wellbeing in patients with diabetes mellitus type 2 in daily practice / T.F. Veneman, F.E.M.G. Storms, I.A. Eland, P.K.P. Bouter // *J Diabetes Mellitus*.- 2012.- №2.- P.101-108.

206. Veld P., Smeets S. Microscopic anatomy of the human islet of Langerhans / P. Veld, S. Smeets // Dodrecht: Springer Science + Business Media.- 2015.- P.19-37.
207. Wang J.Y., Zhu C., Qian T.W., et al. Extract of black bean peel and pomegranate peel ameliorate oxidative stress induced hyperglycemia in mice / J.Y.Wang, C.Zhu, T.W.Qian, et al // Exp Ther Med.- 2014.- doi: 10.3892.
208. Wild, S. Global prevalence of diabetes: estimates for the year 2000 and projections for 2030 / S. Wild, G. Roglic, A. Green et al. // Diabet. Care. – 2004. - № 27. – P. 1047-1053.
209. Willams, R. J. Flavonoids: antioxidants or signaling molecules? / R. J. Willams, J. P. Spencer, C. Rice-Evans // Free Radic. Biol. Med. - 2004. – Vol. 36(7). - P. 838-849.
210. Wu, Z. Oxidative stress is mediator of glucose toxicity in insulin-secreting pancreatic islet cell lines / Z. Wu, W. Nicholson, S. M. Knobel et al. // J. Biol. Chem. - 2004. - Vol. 279. - P. 12126-12134.
211. Wu, X. Perinatal surviving is essential for the establishment of pancreatic beta cell mass in mice / X. Wu, L. Wang, S. Schroer, D. Choi, P. Chen, H. Okada, M. Woo // Diabetologia. – 2009. – Vol. 52, № 10. – P. 2130–2141.
212. Yoon, J. W. Autoimmune destruction of pancreatic beta cells / J. W. Yoon, H. S. Jun // Am. J. Ther. – 2005. - Vol. 12, № 6. - P. 580–591.
213. Yuji K., Sakaida H., Kai T., et al. Effect of dietary blueberry (*vaccinium ashei reade*) leaves on serum and hepatic lipid levels in rats / K.Yuji, H.Sakaida, T.Kai, et al. // Journal of Oleo Science.- 2013.- Vol.62, №2.- P.89-96.
214. Zimmet, P. An exuberance in the prevalence of diabetes mellitus and the threat of the epidemic of this illness in the future / P. Zimmet // Medikografiya. - 1999. – T.21,Vol. 62, № 4. - P.7-15.
215. Zanchetti, A. Antihypertensive treatment in patients with type-2 diabetes mellitus: what guidance from recent controlled randomized trials? / A. Zanchetti, L. M. Ruilope // Hypertens. - 2002. - Vol. 20. - P. 2099-2110.

Accepted abbreviations:

DM - diabetes mellitus
LPO - lipid peroxidation
DHQ – dihydroquercetin
Bc –B cell
Ps - pericapillary space
ED - excretory ducts
Ef - elastic fibers

IMGU - insulin-mediated glucose uptake
NIMGU - non-insulin-mediated glucose uptake
LDL - low-density lipoprotein
PAS - periodic acid–Schiff

CONTENTS

Introduction

CHAPTER 1. Rationale for the application of the model of experimental hyperglycemia in rats	11
CHAPTER 2. Morphofunctional characteristics of pancreatic islets	
Overview of pancreatic islets	15
Characteristics of B cells	16
Regeneration of islet cells	18
Brief description of insulin biosynthesis	20
Characteristics of alpha cells	22
Characteristics of other islet cells	23
Hyperglycemia and its importance in the development of complications of diabetes mellitus.....	25
Morphological changes of the pancreas in clinical and experimental hyperglycemia	27
Brief information about the pathogenesis of diabetes mellitus	28
Angiopathies	30
CHAPTER 3. Histological, histochemical, electron microscopic and morphometric characteristics of the islets of the pancreas of rats	
Morphofunctional characteristics of pancreatic islets in intact rats	33
Morphofunctional characteristics of pancreatic islets in rats during the experiment	36
With hyperglycemia for 8 weeks	
With hyperglycemia for 16 weeks	45
Dihydroquercetin and its role in the treatment of complications of hyperglycemia and diabetes mellitus	56
With hyperglycemia in the setting of dihydroquercetin administration during 8 weeks	59
With hyperglycemia in the setting of dihydroquercetin administration during 16 weeks	64

CHAPTER 4. Histological, histochemical, electron microscopic and morphometric characteristics of rat lung tissue	
Morphofunctional characteristics of the lung	73
Changes in the lung with hyperglycemia and diabetes mellitus	78
Morphofunctional characteristics of the lung in intact rats	80
Morphofunctional characteristic of the lung of rats in experiment with hyperglycemia during 8 weeks	84
Morphofunctional characteristics of the lung of rats in the experiment with hyperglycemia during 16 weeks	90
Morphofunctional characteristics of the lung of rats in the experiment with hyperglycemia in the setting of dihydroquercetin administration for 8 weeks	100
Morphofunctional characteristics of the lung of rats in the experiment with hyperglycemia in the setting of dihydroquercetin administration for 16 weeks	104
CHAPTER 5. Biochemical values of peripheral blood and lung tissue of rats in different periods with hyperglycemia in the setting of dihydroquercetin administration	
Glycemic parameters of peripheral blood	109
Oxidative stress and its role in hyperglycemia	111
The level of reactions of lipid peroxidation (LPO) in hyperglycemia and in the setting of dihydroquercetin administration	
In peripheral blood	114
In the lung tissue.....	115
Conclusion.....	122
References	124
Accepted abbreviations	145
CONTENTS	146